

Acute compartment syndrome due to extravasation of peripheral intravenous blood transfusion

ABSTRACT

Extravasation is an inadvertent injection or leakage of fluid and drugs in the extravascular or subcutaneous space. The extravasation by massive transfused blood results in the elevation of intra-compartmental pressures. Severely increased pressure may lead to acute compartment syndrome (ACS). A 50-year-old man underwent craniectomy for traumatic subdural hemorrhage of the brain. During intraoperative periods, the blood components were transfused by rapid transfusion device and manual pressurized pumping through the central and peripheral lines because of hemorrhagic hypovolemic shock. Approximately 30 minutes after transfusion, we found a hardened right low leg that was obscured by the surgical drape. Immediately, fasciotomy was performed to release all four compartments. The early recognition and treatment of ACS were important factors contributing to anatomical structure salvage and preservation of function. Anesthesia providers should check the site of the insertion of the intravenous catheter, especially while pressurized massive transfusion via the peripheral intravenous catheter.

Key words: Acute compartment syndrome; extravasation; general anesthesia; massive transfusion

Introduction

The acute compartment syndrome (ACS) is caused by increasing pressure within the anatomical compartment, resulting in compromised tissue perfusion.^[1] During general anesthesia, although ACS requires rapid recognition and treatment, it is not easy to diagnose ACS because patients are unconscious and under drapes, and the early symptoms of ACS such as pain and paresthesia are unrecognized by physicians. The extravasation is an inadvertent injection or leakage of fluid and drugs in the extravascular or subcutaneous space.^[2] The extravasation of transfused blood results in serious intra-compartmental pressures elevation, which rarely leads to ACS of the low leg. We describe a case in which massive intravenous blood

transfusion causes extravasation of blood and ASC of the low leg.


Case

A 50-year-old man of 65 kg weight, 172 cm and height underwent emergent craniectomy for traumatic subdural hemorrhage of the brain. The patient was a stupor and in an intubated state. In the operating room, the initial vital signs were blood pressure of 118/83 mmHg, heart rate of 115 beats/min, and peripheral oxygen saturation of 99% by the infusion of norepinephrine. General anesthesia was induced and maintained by sevoflurane and remifentanyl infusion under volume-controlled ventilation. The arterial catheterization on

This is an open access journal, and articles are distributed under the terms of the Creative Commons Attribution-NonCommercial-ShareAlike 4.0 License, which allows others to remix, tweak, and build upon the work non-commercially, as long as appropriate credit is given and the new creations are licensed under the identical terms.

For reprints contact: reprints@medknow.com

How to cite this article: Park C, Kim H. Acute compartment syndrome due to extravasation of peripheral intravenous blood transfusion. Saudi J Anaesth 2020;14:221-3.

Access this article online	
Website: www.saudija.org	Quick Response Code 
DOI: 10.4103/sja.SJA_565_19	

CHANYANG PARK, HYUCKGOO KIM

Department of Anesthesiology and Pain Medicine, College of Medicine, Yeungnam University, Daegu, Republic of Korea

Address for correspondence: Prof. Hyuckgoo Kim, Department of Anesthesiology and Pain Medicine, College of Medicine, Yeungnam University, Hyeonchung-ro, 170, Nam-gu, Daegu - 705-703, Republic of Korea. E-mail: rlagurn@ynu.ac.kr

Submitted: 04-Sep-2019, **Accepted:** 20-Oct-2019, **Published:** 05-Mar-2020

the right radial artery was performed. The central lines on the right subclavian vein and two more peripheral lines on both the saphenous vein of medial malleolus were placed.

During operation, after the dura mater of the brain was dissected, massive bleeding developed by sinus bleeding. The arterial blood pressure dropped to 50/35 mmHg and the heart rate increased to 130 beats/min. The bolus administration of phenylephrine revealed no impact on vital signs. Epinephrine infusion was initiated with norepinephrine. Concurrently, the packed red blood cells (pRBCs) rapidly transfused through central and peripheral lines. Rapid transfusion device, level one infusion system (Model H1025), was used to augment the flow. In addition, transfusion simultaneously was done by applying manual pressurized pumping through peripheral lines. Despite the administration of vasopressors and massive transfusion, the blood pressure remained lethally low.

Approximately 30 minutes after massive transfusion, we found a hardened right low leg like a stone. We had transfused blood into the peripheral line of the right saphenous vein by applying manual pressure but it was unrecognized because the extravasation of blood was obscured by a surgical drape. Immediately, fasciotomy was performed to release all four compartments by orthopedic physicians. The operative findings included a large hematoma and the muscle appeared dark red on the opening site of fasciotomy. The muscles were rapidly returned to normal color appearance after the removal and irrigation of the hematoma. The incisions were left open with sterile dressings [Figure 1]. The origin of the hematoma was the transfused dark red blood.

The blood pressure was gradually stabilized to 100/60 mmHg after bleeding control. The estimated blood loss was 8,000 mL and the amount of transfused blood was 3,800 mL. After surgery, there was no additional tissue damage due to ACS in the low leg but there was continuous oozing and leaking blood from the operative site of craniectomy. The postoperative hemoglobin level decreased steadily to 6.9 g/dL on the fourth day, even after continuous blood transfusion. The patient's brain revealed a severe edematous condition. His vital signs also were unstable continually even though dopamine, norepinephrine, and epinephrine were infused. On postoperative fifth day, he expired due to cardiac arrest.

Discussion

The extravasation during general anesthesia usually is related to the toxicity, osmolarity and vasoconstrictive property of the drugs including anesthetics.^[3,4]In the present

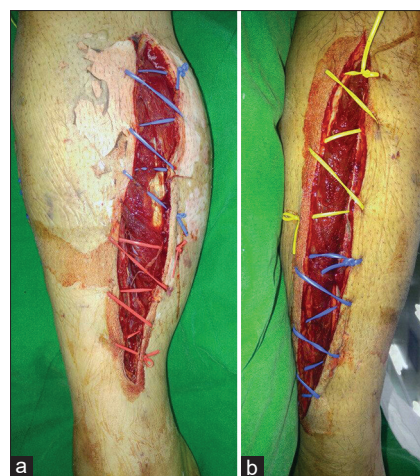


Figure 1: Double incisions fasciotomy was performed to release compartments and the incisions were left open with sterile dressings. (a) medial aspect of low leg. (b) lateral aspect of low leg

case, pressurized delivery of blood through a peripheral intravenous (IV) line resulted in iatrogenic vascular injury and extravasation, this happens rarely. Furthermore, the damage produced by the extravasated blood did not result in the physiochemical injury but the serious intra-compartmental pressures elevation of the right low leg. With increased intra-compartmental pressure, ACS which is a potentially devastating condition, was developed.^[1] To prevent irreversible complications caused by ACS, fasciotomy had been done before devastating tissue necrosis occurs. Consequently, the mechanism of ACS has been attributed to the extravasation of blood components related to the massive transfusion in hemorrhagic hypovolemic shock.

During emergent open craniectomy because of severe intracranial bleeding, massive bleeding continued, and the vital signs revealed hypovolemic shock. Therefore, a massive transfusion was indicated. The definition of massive transfusion includes requirement more than four pRBC units per hour with an ongoing need for transfusion.^[5]In addition, the volume of transfusion per minute was increased by applying pressure to the multiple IV lines to keep up the bleeding amount. We had initially confirmed well-functioned IV lines by regurgitation of blood.

Although we had confirmed that the peripheral IV cannulations function properly, the function was compromised under the operation and resulted in an extravasation injury unintentionally. We consider that high fluid velocity exiting the small catheter tip by pressurized administration increased the pressure in the vein distal to the catheter tip, and weaken the vascular wall structure. This mechanism may be responsible for the occurrence of extravasations.^[6]The anesthesiologist should confirm well-functioned IV line. In addition, very

close attention should be given when fluids are administered under pressure to concealed cannulas. The possibility of extravasation should be considered in all IV lines.

The extravasation of peripheral IV infiltration is a rare iatrogenic cause of ACS because the subcutaneous space has not a rigid boundary like the muscular compartments. Nevertheless, the ability of the overlying of skin to stretch in response to volume expansion is limited. Rapid and massive volume infiltration to subcutaneous can cause significant pressure increase. According to the increasing pressure of the subcutaneous space, the pressure within the anatomical compartment will also increase.^[7] And then, the subcutaneous compartments act as a tourniquet and result in impairing perfusion of the underlying muscle compartments. Therefore, although the extravasation developed in the medial side of the low leg, intra-compartmental pressures of all compartments of low leg were increased.

The case of ACS due to increased intra-compartmental pressure is a surgical emergency. Therefore, early fasciotomy was recommended as a preferred treatment contributing to anatomical structure salvage and preservation of function.^[8] The early fasciotomy, which may be unnecessary and associate with infection, is better than do it too late because underestimation of the risk for tissue damage by ACS has potential systemic complications and functional loss.^[9] Although neuromuscular function recovers with no additional tissue damage, the patient expired due to cardiac arrest by brain edema and continuous brain hemorrhage, very unfortunate!

In conclusion, anesthesia providers must repeatedly check insertion site of the IV catheter, especially when rapid massive transfusion is done via IV lines under surgical drapes. In addition, if extravasation occurs, early recognition of extravasation is the most important factor to avoid ACS. The prompt catheter removal and appropriate management are the keystones for minimizing the complications by ACS due

to extravasation. Early fasciotomy was indicated in ACS due to increased intra-compartmental pressure.

Declaration of patient consent

The authors certify that they have obtained all appropriate patient consent forms. In the form, the patient has given his consent for his images and other clinical information to be reported in the journal. The patient understands that his name and initials will not be published and due efforts will be made to conceal his identity, but anonymity cannot be guaranteed.

Financial support and sponsorship

Nil.

Conflicts of interest

There are no conflicts of interest.

References

1. Matsen FA 3rd, Winquist RA, Krugmire RB Jr. Diagnosis and management of compartmental syndromes. *J Bone Joint Surg Am* 1980;62:286-91.
2. Le A, Patel S. Extravasation of noncytotoxic drugs: A review of the literature. *Ann Pharmacother* 2014;48:870-86.
3. Schummer W, Schummer C, Bayer O, Muller A, Bredle D, Karzai W. Extravasation injury in the perioperative setting. *Anesth Analg* 2005;100:722-7.
4. Khokhar RS, Aqil M, Al-Zahrani T, Gelidan A, Al Khayal K. Novel management of methylene blue extravasation: A case report and review of literature. *Saudi J Anaesth* 2015;9:211-3.
5. Muirhead B, Weiss ADH. Massive hemorrhage and transfusion in the operating room. *Can J Anaesth* 2017;64:962-78.
6. Weber PW, Coursey CA, Howle LE, Nelson RC, Nichols EB, Schindera ST. Modifying peripheral IV catheters with side holes and side slits results in favorable changes in fluid dynamic properties during the injection of iodinated contrast material. *Am J Roentgenol* 2009;193:970-7.
7. Kvistedal YA, Nielsen PM. Estimating material parameters of human skin *in vivo*. *Biomech Model Mechanobiol* 2009;8:1-8.
8. Dunn D, Wilensky M. Median and ulnar nerve palsies after infiltration of intravenous fluid. *South Med J* 1984;77:1345.
9. Guo J, Yin Y, Jin L, Zhang R, Hou Z, Zhang Y. Acute compartment syndrome: Cause, diagnosis, and new viewpoint. *Medicine* 2019;98:e16260.