

Received: 2020.02.24

Accepted: 2020.06.14

Available online: 2020.06.30

Published: 2020.08.22

Mendelson's Syndrome: Chemical Pneumonitis After Pesticide Intake

Authors' Contribution:
Study Design A
Data Collection B
Statistical Analysis C
Data Interpretation D
Manuscript Preparation E
Literature Search F
Funds Collection G

ABCDEFG 1,2,3

ABCDEF 2,3

ABCD 3

CDEF 2,4

CDEF 1,2

CDEFG 5

ABCDEFG 6,7

Killen H. Briones-Claudett
Mónica H. Briones-Claudett
Cesar Andrade Cabrera
Killen H. Briones Zamora
Diana C. Briones Márquez
Jaime Benites Solís
Michelle Grunauer

1 Faculty of Medical Sciences, University of Guayaquil, Guayaquil, Ecuador
2 Physiology and Respiratory Center Briones-Claudett, Guayaquil, Ecuador
3 Intensive Care Unit, Ecuadorian Institute of Social Security (IESS), Babahoyo, Ecuador
4 Faculty of Medical Sciences, Universidad Espíritu Santo, Samborondón, Ecuador
5 Intensive Care Unit, OMNI-Hospital, Guayaquil, Ecuador
6 School of Medicine, Universidad San Francisco de Quito, Quito, Ecuador
7 Critical Care Unit, Hospital de los Valles, Quito, Ecuador

Corresponding Author:

Killen H. Briones-Claudett, e-mail: killenbri@hotmail.com, killen.brionesc@ug.edu.ec, kyllenbri@yahoo.com

Conflict of interest:

None declared

Patient: Female, 15-year-old
Final Diagnosis: Chemical pneumonitis • Mendelson's syndrome
Symptoms: Emesis • hypoxemia
Medication: —
Clinical Procedure: Bronchoalveolar lavage
Specialty: Critical Care Medicine • General and Internal Medicine

Objective: Rare co-existence of disease or pathology**Background:** Mendelson's syndrome consists of pulmonary aspiration of acidic gastric contents that results in acute lung injury (chemical pneumonitis).**Case Report:** We present the case of a 15-year-old girl who was admitted to the Emergency Department 1 h after ingestion of an organophosphate pesticide. The patient had abundant emesis of aqueous, transparent content, accompanied by drowsiness and moderate sialorrhea. We observed drooling and foaming at the mouth and tachycardia, and her oxygen saturation dropped to 75%, requiring immediate invasive ventilation. Computed tomography (CT) revealed opacities in both lung bases, while bronchoscopy evidenced burn lesions along the airway. A bronchoalveolar lavage (BAL) was performed and microbiological results were negative. Following the BAL, the patient showed a satisfactory evolution and full recovery.**Conclusions:** This case report describes chemical pneumonitis due to pulmonary aspiration of sterile gastric contents following ingestion of a pesticide. We discuss the importance of timely diagnosis, the characteristic burn lesions found in bronchoscopy, and the role of bronchoalveolar lavage, which most likely allowed for a rapid recovery with favorable results.**MeSH Keywords:** Bronchoalveolar Lavage Fluid • Bronchoscopy • Respiratory Aspiration of Gastric Contents**Abbreviations:** CT – computed tomography; ICU – Intensive Care Unit; SO₂ (%) – oxygen saturation by pulse oximeter; RR – respiratory rate; MBP – medium blood pressureFull-text PDF: <https://www.amjcaserep.com/abstract/index/idArt/923776>

1448



—



2



5



Background

Chemical pneumonitis occurs when aspirated material is toxic to the lungs, which results in more severe irritation than seen in infections. Chemical pneumonitis can also result from the inhalation of substances such as laxative oils (e.g., mineral oil, castor oil, paraffin oil) and hydrocarbons (e.g., gasoline, kerosene, petroleum products) [1]. Upon inhalation, dyspnea suddenly appears, and coughing starts within minutes or hours. Other symptoms may include fever and a pink and foamy sputum, as well as loss of sensory input. In less severe cases, symptoms of aspiration pneumonia may appear 1 or 2 days following inhalation of the toxic agent [2].

Mendelson's syndrome is a chemical pneumonitis that results from pulmonary aspiration of >25 mL of stomach acid contents with a pH <2.5 [3]. The clinical manifestation includes hypoxemia, tachypnea, tachycardia, atelectasis, and respiratory distress, with progression to acute respiratory distress syndrome and subsequent pulmonary necrosis. Patients are generally admitted to the Intensive Care Unit (ICU). Bronchoscopy can show the extent of the airway lesions, and BAL can limit further progression of the disease. Many patients are severely ill and need ventilatory support [3].

We report an unusual case of a 15-year-old girl who presented with Mendelson's syndrome after ingestion of a pesticide led to pulmonary aspiration of sterile gastric contents. We discuss the importance of a timely diagnosis, the characteristic burn lesions found in bronchoscopy, and the role of bronchoalveolar lavage, which most likely allowed for a rapid recovery with favorable results.

Case Report

Patient history

A 15-year-old girl was admitted to the Emergency Department 1 h after ingestion and inhalation of a powder-based pesticide. Her vital signs were arterial blood pressure 127/77 mmHg, heart rate 166 bpm, and oxygen saturation (SO₂ pulse oximeter) of 98% on room air.

A physical examination revealed a depressible abdomen with slight pain. Suddenly, the patient presented an abundant and transparent aqueous emesis, drooling and foaming at the mouth, and drowsiness, followed by oxygen desaturation of 75% as measured by pulse oximeter, tachycardia, diaphoresis, fasciculations, and sensory deterioration. Supplementary oxygen by mask was administered, and we gave gastric protection, antiemetics, and 125 mg of methylprednisolone, with-out improvement. Atropine was administered upon arrival but

it did not result in an immediate favorable clinical response. Endotracheal intubation and mechanical ventilation were initiated, and the patient was transferred to the ICU. A chest CT scan revealed opacities in both lung bases.

Laboratory test results evidenced leukocyte count: 14 560 per mm³ (normal range, 4400 to 11 300 mm³), hemoglobin 11.7 g/dL (normal range, 12 to 16 g/dL), hematocrit 35.3% (normal range, 42% to 50%), uncompromised renal function, and slight hypokalemia (3.1 meq/L) (normal range, 3.5 to 4.5 mEq/l). Liver enzymes were normal.

In the ICU, the patient was placed on invasive mechanical ventilation and vasopressor support and a low dose of Norepinephrine was initiated (0.05 mg/kg/min), as well as Propofol (1 mg/kg/h) and Fentanyl (0.5 µg/kg/h).

Details of the ingested pesticide

Mocap® G (etoprophos 10%; Certis Group, Singapore) is a potent nematicide with insecticidal action; its active substance, etoprophos, is a nonsystemic organophosphorus with contact activity. It has a good penetration capacity and acts by interfering with the transmission of nerve impulses through inhibition of acetylcholinesterase. Once applied and incorporated into the soil, Mocap® G is retained in the substrate and acts by contact in the root development zone by controlling nematodes and insects. Mocap® contains 10% etoprophos p p, formulated as a granulate (active ingredient: 10%). The International Union of Pure and Applied Chemistry's name is O-ethyl S, S-dipropyl phosphorodithioate.

Evolution

On Day 1 in the ICU, the patient presented hyper-reactive pupils and required invasive ventilatory support. Empirical antibiotic coverage with ampicillin/sulbactam plus clindamycin was initiated. A chest CT demonstrated opacities in both pulmonary bases (Figure 1). Arterial blood gas (ABG) tests showed respiratory acidosis, (pH 7.33, PaCO₂: 46.4 mmHg, PaO₂: 112 mmHg, HCO₃: 24.0 mmol/L, BE: -1.6 mEq/L, SO₂: 95.2%) (FiO₂ 70%). Vital signs were as follows: blood pressure 115/68 mmHg, MBP: 84 mmHg, HR: 98 bpm, respiratory rate (RR): 15 bpm, SO₂: 95%, and temperature: 36.4°C. Laboratory test results evidenced a considerable decrease in leukocytes: 8400 per mm³ (normal range, 4400 to 11 300 mm³), Hb: 10.8 g/dL (normal range, 12 to 16 g/dL), hematocrit: 31.7% (normal range, 42% to 50%), platelets: 284 000 per mm³ (normal range, 150 000 to 450 000 per mm³).

On Day 2, the evolution remained unchanged and bronchoscopy demonstrated multiple burn-type lesions with erosion of the mucosa, redness, hemorrhagic stitches, and bleeding,

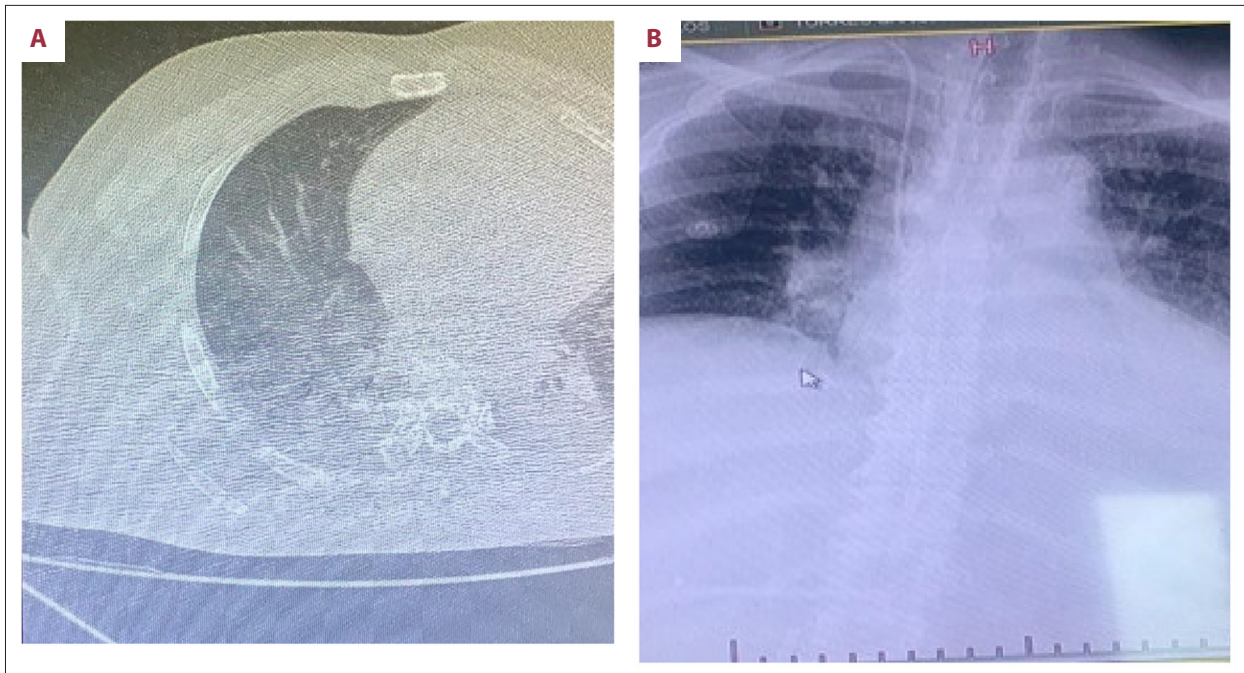


Figure 1. (A) Chest X-ray shows infiltrate of the right hilum and (B) shows opacity in both lung bases.

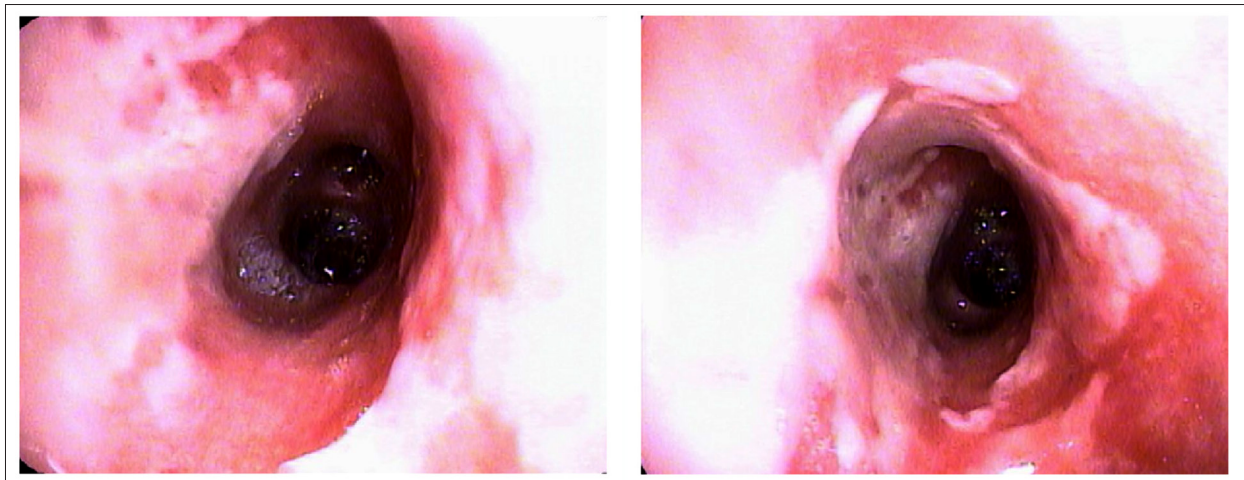


Figure 2. Presence of erosive burn-type lesions, plus erythematous lesions. Reddish bronchial walls are identified.

particularly in the right bronchus. Bronchial lavage was performed with physiological saline and bronchioalveolar lavage and brush samples were taken for microbiological studies (Figure 2). Twelve hours after this procedure, the patient was weaned from mechanical ventilation.

On Day 3, vasopressor support was discontinued. Her blood pressure was 122/67 mmHg, HR was 72/min, RR was 20 bpm, and SO_2 was 99% (FiO_2 40%). Laboratory studies showed a leukocyte count of 8000 mm^3 (normal range 4400 to 11 300 mm^3), hemoglobin was 9.8 gr/dL (normal range, 12 to 16 g/dL), hematocrit was 28.9% (normal range, 42% to 50%), and platelet

count was 287 000 mm^3 (normal range, 150 000 to 450 000 per mm^3).

On Day 4, the patient breathed spontaneously on room air (FiO_2 : 0.21), with good clinical evolution.

On Day 5, microbiological cultures from the BAL were negative and antibiotics were discontinued. The patient was discharged from the ICU and 2 days later was discharged from the hospital.

Discussion

We report a case of chemical pneumonitis due to acid pulmonary aspiration occurring a few hours after the accidental ingestion and inhalation of an organophosphate pesticide.

Aspiration of large quantities of stomach acid contents can lead to pulmonary complications, especially chemical burns to the lungs and pneumonitis, as acid contents in lung tissue can trigger edema and alveolar destruction [4]. Lung aspiration of acid gastric contents often results in initial nonsignificant lung damage; however, consistent hypoxemia is present. Tissue damage tends to occur after further lung injury, with alveolar edema, destruction, and damage to the pulmonary surfactant.

In our patient, the neuromuscular symptoms that resulted from organophosphate pesticide toxicity, such as tachycardia, diaphoresis, and fasciculations, were finally reversed with the administration of atropine sulfate. However, the chemical lesions caused by pulmonary aspiration resulted in hypoxemia and respiratory failure that required mechanical ventilatory support.

The main clinical manifestation of this condition is hypoxemia and respiratory failure that depends upon the extent of aspiration of the gastric contents. Unlike aspiration pneumonia, in which the aspirated substance is usually colonized by bacterial pathogens that results in infectious complications, in chemical pneumonitis, the aspirated contents, as reported in this case, involved a significant volume of sterile gastric acid of approximately 0.3 mL/kg. Mendelson's syndrome is a chemical injury that results from the aspiration of gastric acid as opposed to aspiration pneumonia caused by the aspiration of oropharyngeal contents that colonize the airway with pathogens, especially bacteria. However, in some cases, these 2 syndromes overlap. Intact defense mechanisms that act in the prevention of aspiration are fundamental – in particular, cough reflex, a normal level of consciousness, and an adequate immune response.

There are some factors that distinguished between chemical pneumonitis and aspiration pneumonia in our patient. Bronchoscopic visualization evidenced typical burn injuries, such as ulcerations, congestion, hyperemia, and bleeding. BAL

and bronchial brushing analyses did not demonstrate bacterial growth. Finally, the patient was asymptomatic before the ingestion and presented to the ED in acute illness, with abundant emesis of liquid aqueous material, with subsequent depression of sensory input, and in respiratory failure. Inhalation of the pesticide to some extent explains our findings, but we recovered acid gastric contents in the BAL.

A rational antibiotic therapy management was initiated, but was discontinued when negative microbiological results were obtained of samples recovered from bronchoalveolar brushing and lavage.

Both the IDSA (Infectious Diseases Society of America) and ATS (American Thoracic Society) recommend that patients with gingivitis and risk of aspiration due to sensory depression should receive a limited antibiotic regimen [5].

Our patient received high doses of corticosteroids, which might explain her leukocytosis. However, limited data exist on the use of corticosteroids in this therapeutic approach, on short courses of antibiotics, and on aspiration episodes in which the patient develops fever, leukocytosis, and pulmonary infiltrates.

Conclusions

In conclusion, we present a rare case of chemical pneumonitis due to pulmonary aspiration of stomach acid contents after the intake of a pesticide. We discuss the typical burn injuries evidenced through bronchoscopy that led to timely administration of therapy. Bronchoalveolar lavage allowed for rapid patient recovery with a favorable outcome.

Department and Institution where work was done

Intensive Care Unit, Ecuadorian Institute of Social Security (IESS), Babahoyo, Ecuador.

Conflict of interest

None.

References:

1. Salik I, Doherty TM: Mendelson syndrome. 2019 Jun 4. StatPearls [Internet]. Treasure Island (FL): StatPearls Publishing; 2019 Available from: <http://www.ncbi.nlm.nih.gov/books/NBK539764/>
2. Kalbessa A, Dekebo A, Tesso H et al: Chemical constituents of root barks of gnidia involucreta and evaluation for antibacterial and antioxidant activities. *J Trop Med*, 2019; 2019: 8486214
3. Marik PE: Aspiration pneumonitis and aspiration pneumonia. *N Engl J Med*, 2001; 344(9): 665–71
4. Komiya K, Ishii H, Kadota J: Healthcare-associated pneumonia and aspiration pneumonia. *Aging Dis*, 2014; 6(1): 27–37
5. Mandell LA, Wunderink RG, Anzueto A et al., Infectious Diseases Society of America; American Thoracic Society: Infectious Diseases Society of America/American Thoracic Society consensus guidelines on the management of community acquired pneumonia in adults. *Clin Infect Dis*, 2007; 44(2): S27–72