

Original paper

Noninvasive evaluation of renal tissue oxygenation with blood oxygen level-dependent magnetic resonance imaging early after transplantation has a limited predictive value for the delayed graft function

Agata Sławińska^{1B,D,E,F}, Zbigniew Serafin^{1A,B,C,D,E,F,G}, Elżbieta Zawada^{1A,B,D}, Marcin Białecki^{1A,B,D},
Katarzyna Wypych^{1A,B,D,E}, Aleksandra Woderska^{2A,B}, Maciej Słupski^{3A,B}, Zbigniew Włodarczyk^{2A,B}

¹Department of Radiology and Diagnostic Imaging, Nicolaus Copernicus University, Collegium Medicum, Bydgoszcz, Poland

²Department of General and Transplant Surgery, Nicolaus Copernicus University, Collegium Medicum, Bydgoszcz, Poland

³Department of Hepatobiliary and General Surgery, Nicolaus Copernicus University, Collegium Medicum, Bydgoszcz, Poland

Abstract

Purpose: The aim of this study was to evaluate the feasibility of renal oxygenation assessment using blood oxygen level-dependent (BOLD) magnetic resonance imaging (MRI) in the early period after kidney transplantation and to estimate its prognostic value for delayed graft function.

Material and methods: Examinations were performed in 50 subjects: 40 patients within a week after the kidney transplantation and 10 healthy controls, using T2*-weighted sequence. Measurements in transplant patients were correlated to basic laboratory parameters in the early period after transplantation and at follow-up.

Results: Examinations of seven patients (18%) were rejected due to their poor technical quality. Mean R2* values in transplant recipients were lower than in controls (11.6 vs. 15.9 Hz; $p = 0.0001$). An R2* value of 0.28 Hz was calculated as the minimal detectable change. There was no relation between R2* values and laboratory parameters. However, patients eGFR ≥ 40 ml/min/1.73 m² presented higher R2* values than recipients eGFR < 40 ml/min/1.73 m² (12.0 vs. 11.1 Hz; $p = 0.0189$). In ROC analysis R2* of ≤ 11.7 predicted an early reduced graft function with 0.82 sensitivity and 56% specificity (AUC = 0.708; $p = 0.024$) but was not useful for delayed graft function prediction ($p > 0.7$).

Conclusions: Evaluation of renal graft oxygenation using BOLD MRI is technically challenging in the early period after transplantation. An R2* value of 0.28 Hz may in practice be considered as the minimal detectable change. The delayed graft function seems not to be dependent on early oxygenation values. Further, large-scale studies are necessary to confirm the latter observation.

Key words: renal graft oxygenation, BOLD MRI, blood oxygen level dependent (BOLD) magnetic resonance, kidney transplantation.

Introduction

Renal transplantation is the most effective therapeutic method for end-stage chronic kidney disease (CKD). Unfortunately, there are currently no good markers of early allograft injury, and a kidney biopsy is often required for

diagnostic purposes [1]. However, the clinical utility of this approach is not clear. Biopsy also carries the risk of significant graft injury, and it cannot be performed in patients who take anticoagulants [2]. Therefore, current best practice involves vigilant monitoring of simple markers of allograft function, such as serum creatinine and pro-

Correspondence address:

Prof. Zbigniew Serafin, Department of Radiology and Diagnostic Imaging, Nicolaus Copernicus University, Collegium Medicum, 9 Skłodowskiej-Curie St., 85-094 Bydgoszcz, Poland, e-mail: serafin@cm.umk.pl

Authors' contribution:

A Study design · B Data collection · C Statistical analysis · D Data interpretation · E Manuscript preparation · F Literature search · G Funds collection

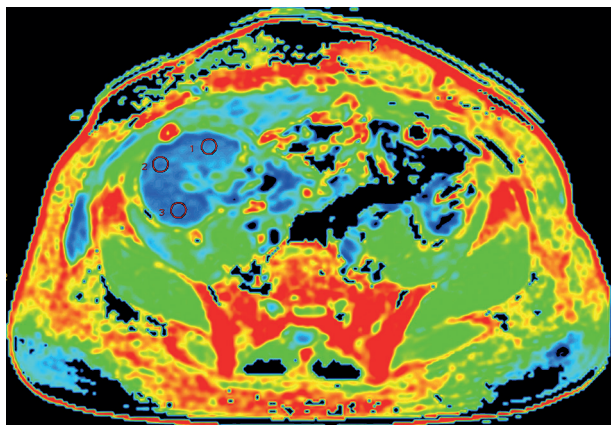


Figure 1. Example of ROIs placement in a transplanted kidney on axial R2* map

teinuria. More complex and expensive approaches, such as monitoring of serum anti-HLA antibodies, remain unproven [3]. Thus, a non-invasive, fast, and specific tool that would detect acute allograft parenchymal pathologies is desirable [2].

Magnetic resonance imaging (MRI) could become a one-stop shop modality for transplanted kidney evaluation, as it is an established method for renal graft morphology and vasculature assessment [4,5]. Recently, several MRI techniques that evaluate renal graft function have been introduced [6-8]. For instance, blood oxygen level-dependent (BOLD) imaging can depict blood flow and parenchymal oxygen bioavailability [9,10], which may be related to renal graft metabolism and thus can become a surrogate biomarker of graft survival.

BOLD MRI can be used for non-invasive estimation of renal parenchymal oxygen concentration. BOLD MRI is based on the paramagnetic effect of deoxyhaemoglobin for indirect depiction of renal oxygenation, whereby an increased oxygen consumption results in an increased deoxygenated haemoglobin concentration. This leads to decreased T2* relaxation times on renal parenchyma images, which can be measured as the rate of spin dephasing ($R2^* = 1/T2^*$) [9]. Thus, R2* may be considered as an indicator of renal metabolism [10]. However, factors other than oxygenation, such as perfusion, haematocrit, or microstructure, can influence the deoxyhaemoglobin concentration and thus the R2* values.

It was shown that renal cortical oxygenation, measured with BOLD imaging, was reduced in patients with CKD, and cortical oxygenation level correlated with CKD severity [11]. BOLD imaging was also suggested as a method to diagnose early kidney graft failure [12-17]. To our knowledge, no study has assessed the role of renal cortex oxygenation measurement early after transplantation in the prediction of delayed renal graft function. Therefore, we aimed to assess the feasibility of BOLD imaging in the early period after kidney transplantation in order to establish R2* measurement variability and to verify the value of R2* in predicting delayed graft function.

Material and methods

We performed renal BOLD examinations in 40 kidney graft recipients (patients) and 10 healthy controls. Patients were included if their clinical state enabled MRI examination within the first week after transplantation. Controls with no history of kidney disease were included if their eGFR was ≥ 90 ml/min/1.73 m². Exclusion criteria were as follows: claustrophobia, metallic implants, dyspnoea, and peritoneal dialysis. Informed consent was obtained from all participants. The study was approved by our University Review Board.

MRI examinations were performed with a 1.5-T scanner (GE Optima 450wGEM, General Electric Healthcare, Waukesha, USA). In patients, the examinations were performed within one week after surgery. Breath-hold, axial, T2WI, multi-gradient-recalled-echo sequences were acquired (TR, 56.4 ms; TE, 1.2-20.6 ms; flip angle, 25°; slice thickness, 8 mm; matrix, 128 × 128). The R2*-parametric maps were generated with a two-parameter fitting algorithm and a confidence level of 0.01. The R2* values were averaged across three ROIs of 10 mm in diameter. ROIs were placed on the largest cross-section of the kidney and were located peripherally within the renal parenchyma in the anterior, middle, and posterior part of the graft (Figure 1).

Measurements in transplant patients were correlated with basic laboratory parameters in the early period after transplantation, including eGFR, serum creatinine concentration (SCr), proteinuria, serum uric acid and glucose concentration, white blood cell count (WBC), red blood cell count (RBC), and haematocrit (HCT). The R2* values were also correlated with eGFR and SCr at long-term follow-up. To establish inter-reader reproducibility of measurements, R2* was measured on parametric maps in three cortical regions of interest (ROIs) by two observers, both with five years of experience in abdominal MRI. For intra-reader reproducibility calculation both observers repeated their measurements after six months. Images were anonymised before analysis.

Data were presented as means with 95% confidence intervals (95% CI). Intra-reader variability and inter-reader variability were assessed with the coefficient of variation (CV) and the intraclass correlation coefficient (ICC). The results from both observers were also tested for differences with repeated measures ANOVA. Standard error of measurement (SEM) was a measure of absolute agreement: $SEM = SD$ (standard deviation) \times root (1-ICC). Finally, the minimal detectable change (MDC) was calculated as the smallest change in R2* value that could be interpreted as a real difference [18]: $MDC = 1.96 \times$ square root of $2 \times SEM$. Differences in oxygenation estimates between patients and controls were tested with the independent samples *t*-test. The relationship between R2* values, graft function, and laboratory parameters was analysed with multiple regression and logistic regression. $P < 0.05$ was considered significant.

Table 1. Clinical characteristics of patients

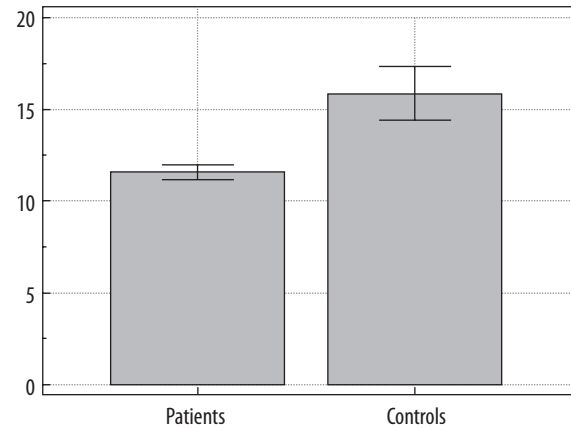
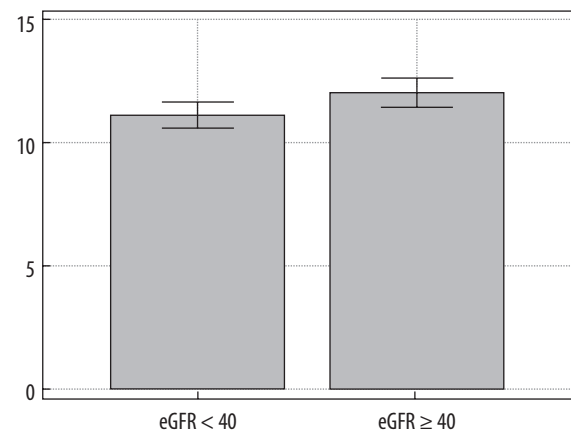
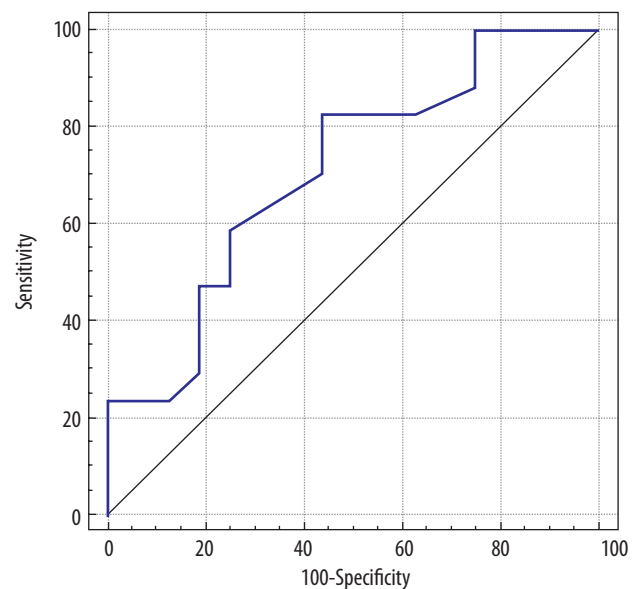
Parameter	Mean value (95% CI)	Range
Age (years)	51.8 (46.1-57.5)	18-81
SCr (mg/dl)	2.81 (1.95-3.68)	0.47-9.86
eGFR (ml/min/1.73 m ²)	42.5 (31.3-53.6)	4.8-149.1
Proteinuria (g/24 h)	0.55 (0.37-0.73)	0.00-1.00
Uric acid (mg/dl)	4.10 (3.39-4.81)	2.10-9.20
Glucose (mg/dl)	96.4 (79.9-112.8)	69.0-318.0
WBC (10 ⁹ /l)	8.06 (7.05-9.07)	3.89-16.1
RBC (10 ⁹ /l)	3.42 (3.25-3.60)	2.69-5.43
HCT (%)	31.1 (29.7-32.6)	25.6-47.2

Results

The clinical characteristics of patients are presented in Table 1. We rejected examinations of seven patients (18%) due to subjective poor image quality that was related to motion artefacts. Repeated measures ANOVA did not show significant differences between the three ROI values in either of the observers. In a per-ROI analysis, the mean intra-reader CV was 6% for observer A and 9% for observer B, respectively. The intraclass correlation coefficient was 0.79 and 0.87 for observer A and observer B, respectively. In a per-patient analysis, the mean inter-reader CV was 11%, with a wide range of 0% to 66%. The overall inter-reader CV was 14.6%, SEM was 0.10 Hz, and MDC was 0.28 Hz.

The mean cortical R2* value was 11.6 Hz (95% CI: 11.2 to 12.0) in transplant recipients and 15.9 Hz (95% CI: 14.4 to 17.3) in controls ($p = 0.0001$, Figure 2). On multiple regression analysis, we did not observe any significant relationship between the R2* values and the studied clinical parameters. However, patients with eGFR ≥ 40 ml/min/1.73 m² had higher R2* values than those with eGFR < 40 ml/min/1.73 m² (12.0 Hz vs. 11.1 Hz, respectively; $p = 0.0189$; Figure 3). On ROC analysis, R2* values ≤ 11.7 predicted impaired graft function defined as eGFR < 40 ml/min/1.73 m²; sensitivity of 82%, specificity of 56%, area under the curve (AUC) = 0.708 ($p = 0.024$; Figure 4).

The mean follow-up duration was 31.3 months (range: 26-45 months). Two patients were lost to follow-up. On the last measurements, the mean SCr was 1.39 (95% CI: 1.20 to 1.58), and the mean eGFR was 53.1 (95% CI: 46.3 to 59.8). At the long-term follow-up, R2* was not a significant predictor of kidney function, and there was no significant difference in post-transplant R2* values between patients with eGFR ≥ 40 ml/min/1.73 m² and those with eGFR < 40 ml/min/1.73 m² (11.6 vs. 11.9, respectively). Multiple regression analysis of R2* values

**Figure 2.** Comparison of cortical R2* values in transplant recipients and controls. Mean values and 95% CIs are given**Figure 3.** Comparison of cortical R2* values between patients with eGFR < 40 ml/min/1.73 m² and those with eGFR ≥ 40 ml/min/1.73 m²**Figure 4.** A ROC curve presents R2* values as a predictor of an early impaired graft function defined as eGFR < 40 ml/min/1.73 m²

and laboratory parameters did not allow the generation of any model to predict either early or delayed graft function.

Discussion

To our knowledge, we showed for the first time that BOLD imaging performed early after transplantation has a limited value in predicting delayed renal graft function. We found that $R2^*$ values were moderately related to early graft function. Finally, based on inter-reader reproducibility analysis, the minimal detectable change in $R2^*$ was only 0.28 Hz.

In our study, 18% of patients were excluded from the analysis due to inadequate image quality. Similar rejection rates were reported by Sadowski *et al.* [14] and Niles *et al.* [19] but not by other researchers [15,16,20,21]. We suspect that this could have been due to the short time between renal transplantation and scanning. Breathing motions were the main source of image artefacts because, due to pain and common overhydration, patients in the early period after renal transplantation have a limited ability to hold their breath and to lie still in a supine position throughout the entire MRI examination. Thus, neither respiratory-gated nor breath-hold techniques guarantee images free from movement artefacts in this group of patients. However, we preferred breath-hold sequences because of shorter total examination times. Xiao *et al.* observed a loss of signal in the marginal area of the transplanted kidney [21] because the bowel gas surrounding the kidney caused inhomogeneity in local magnetic fields and susceptibility artefacts. We did not notice this problem in our group.

To our knowledge, renal $R2^*$ measurement variability has not been studied. In the current study, the intra-reader CV ranged between 6% and 9%, and the inter-reader variability was 14.6%. In a per-patient analysis, the mean inter-reader presented a wide range of values (0% to 66%), which may be explained by the fact that ROI placement was left to the discretion of observers. The calculated MDC indicated that a difference of 0.28 Hz may be considered significant for different observers or different ROI placement methods. However, it does not take into account the physiological differences that may introduce some variability to repeated scanning. Recently, two studies have assessed the reproducibility of repeated BOLD examinations. In four patients, Park *et al.* reported that the mean difference in cortical or medullary $R2^*$ values between two MRI examinations at a one-month interval was 0.6–3.8%, depending on the sequence used [20]. However, that study lacked statistical power due to a small sample. Thoeny *et al.*, who studied only seven subjects, reported an inter-scan cortical $R2^*$ variability of 4.0% [22].

Several authors have previously tested the relationship between $R2^*$ values and graft function. Vermathen *et al.* did not observe any relationship between eGFR and oxygenation estimates in repeated examinations performed 7 ± 3 months after transplantation and 32 ± 2 months after initial MRI [17]. Similar results were reported by Seif *et al.* [23]. In the study by Xiao *et al.*, Scr levels were negatively correlated with $R2^*$ values; however, that correlation was

weak (Spearman coefficient of -0.29) [21]. In our study, there was no relationship between cortical $R2^*$ values and clinical parameters, including eGFR, SCr, and proteinuria. However, we observed a difference in renal cortical oxygenation between patients with $eGFR \geq 40$ ml/min/1.73 m² and those with $eGFR < 40$ ml/min/1.73 m², which may indicate decreased graft function. Using this eGFR threshold, $R2^*$ values ≤ 11.7 predicted impaired kidney function with good sensitivity (82%) and poor specificity (56%). Thus, the test may be considered to rule out the graft failure but not to confirm it. Based on previous studies and our data, we can suppose that renal cortical $R2^*$ values are not strongly related to the common parameters of renal early graft function, including eGFR. Moreover, the role of this method in predicting delayed graft function is limited. We found no relationship between the $R2^*$ values measured within a week after transplantation and follow-up eGFR, even if the threshold of 40 ml/min/1.73 m² was used.

Our study had some limitations. First, we included a small number of participants, but our sample size was comparable to previous studies on renal graft oxygenation. What is more, only two patients were lost for follow-up. However, the role of early $R2^*$ measurement for graft function prediction should be assessed in a larger study. Since the mean follow-up duration was over 2.5 years, several factors other than the initial post-transplant renal cortex oxygenation might have influenced the final outcome. To account for such confounders, a larger study will have to be performed. Second, we only measured cortical oxygenation, which was in line with previous studies, such as the significant work by Milani *et al.* [11]. Finally, averaging over three ROIs might have led to some measurement errors, and averaging over whole cross-sections or even over whole cortical volumes could have been better [11,19]. However, such methods are still experimental and require validation before clinical application.

Conclusions

In conclusion, BOLD MRI-based evaluation of renal graft oxygenation early after transplantation is technically challenging. In practice, an $R2^*$ value of 0.28 Hz can be considered as the minimal detectable change. Despite the fact that $R2^*$ values are related to eGFR, BOLD has limited potential to predict early graft function. Delayed graft function does not seem to be dependent on early renal cortical oxygenation.

Ethical approval

All procedures performed in studies involving human participants were in accordance with the ethical standards of the institutional and/or national research committee and with the 1964 Helsinki Declaration and its later amendments or comparable ethical standards. For this type of study, formal consent is not required.

The Institutional Review Board approved the study and did not require additional informed consent for reviewing the patients' medical records and image.

Conflict of interest

The authors report no conflict of interest.

References

- Sharfuddin A. Renal relevant radiology: Imaging in kidney transplantation. *Clin J Am Soc Nephrol* 2014; 9: 416-429.
- Thölking G, Schuette-Nuetgen K, Kentrup D, et al. Imaging-based diagnosis of acute renal allograft rejection. *World J Transplant* 2016; 6: 174-182.
- Baker R, Jardine A, Andrews P. Clinical Practice Guidelines: Post-operative care of the kidney transplant recipient, UK Renal Association. 5th ed. Final version (10th December 2010).
- Mahmoud H, Buchanan C, Francis ST, Selby NM. Imaging the kidney using magnetic resonance techniques: structure to function. *Curr Opin Nephrol Hypertens* 2016; 25: 487-493.
- Gaddikeri S, Mitsumori L, Vaidya S, et al. Comparing the diagnostic accuracy of contrast-enhanced computed tomographic angiography and gadolinium-enhanced magnetic resonance angiography for the assessment of hemodynamically significant transplant renal artery stenosis. *Curr Probl Diagn Radiol* 2014; 43: 162-168.
- Wang YT, Li YC, Yin LL, et al. Functional assessment of transplanted kidneys with magnetic resonance imaging. *World J Radiol* 2015; 7: 343-349.
- Wypych-Klunder K, Adamowicz A, Lemanowicz A, et al. Diffusion-weighted MR imaging of transplanted kidneys: Preliminary report. *Pol J Radiol* 2014; 79: 94-98.
- Robson PM, Madhuranthakam AJ, Smith MP, et al. Volumetric arterial spin-labeled perfusion imaging of the kidneys with a three-dimensional fast spin echo acquisition. *Acad Radiol* 2016; 23: 144-154.
- Notohamiprodjoa M, Reiser MF, Sourbron SP. Diffusion and perfusion of the kidney. *Eur J Radiol* 2010; 76: 337-347.
- Prasad PV, Edelman RR, Epstein FH. Noninvasive evaluation of intrarenal oxygenation with BOLD MRI. *Circulation* 1996; 94: 3271-3275.
- Milani B, Ansaloni A, Sousa-Guimaraes S, et al. Reduction of cortical oxygenation in chronic kidney disease: evidence obtained with a new analysis method of blood oxygenation level-dependent magnetic resonance imaging. *Nephrol Dial Transplant* 2016; pii: gfw362.
- Sadowski EA, Fain SB, Alford SK, et al. Assessment of acute renal transplant rejection with blood oxygen level-dependent MR imaging: initial experience. *Radiology* 2005; 236: 911-919.
- Djamali A, Sadowski EA, Samaniego-Picota M, et al. Noninvasive assessment of early kidney allograft dysfunction by blood oxygen level-dependent magnetic resonance imaging. *Transplantation* 2006; 82: 621-628.
- Sadowski EA, Djamali A, Wentland AL, et al. Blood oxygen level-dependent and perfusion magnetic resonance imaging: detecting differences in oxygen bioavailability and blood flow in transplanted kidneys. *Magn Reson Imaging* 2010; 28: 56-64.
- Park SY, Kim CK, Park BK, et al. Assessment of early renal allograft dysfunction with blood oxygenation level-dependent MRI and diffusion-weighted imaging. *Eur J Radiol* 2014; 83: 2114-2121.
- Liu G, Han F, Xiao W, et al. Detection of renal allograft rejection using blood oxygen level-dependent and diffusion weighted magnetic resonance imaging: a retrospective study. *BMC Nephrol* 2014; 15: 158.
- Vermathen P, Binsler T, Boesch C, et al. Three-year follow-up of human transplanted kidneys by diffusion-weighted MRI and blood oxygenation level-dependent imaging. *J Magn Reson Imaging* 2012; 35: 1133-1138.
- Haley SM, Fragala-Pinkham MA. Interpreting change scores of tests and measures used in physical therapy *Phys Ther* 2006; 86: 735-743.
- Niles DJ, Artz NS, Djamali A, et al. Longitudinal assessment of renal perfusion and oxygenation in transplant donor-recipient pairs using arterial spin labeling and blood oxygen level-dependent magnetic resonance imaging. *Invest Radiol* 2016; 51: 113-120.
- Park SY, Kim CK, Park BK, et al. Evaluation of transplanted kidneys using blood oxygenation level-dependent MRI at 3 T: a preliminary study. *AJR Am J Roentgenol* 2012; 198: 1108-1114.
- Xiao W, Xu J, Wang Q, et al. Functional evaluation of transplanted kidneys in normal function and acute rejection using BOLD MR imaging. *Eur J Radiol* 2012; 81: 838-845.
- Thoeny HC, Zumstein D, Simon-Zoula S, et al. Functional evaluation of transplanted kidneys with diffusion-weighted and BOLD MR imaging: initial experience. *Radiology* 2006; 241: 812-821.
- Seif M, Eisenberger U, Binsler T, et al. Renal blood oxygenation level-dependent imaging in longitudinal follow-up of donated and remaining kidneys. *Radiology* 2016; 279: 795-804.