

Preliminary Experience With Robot-Assisted Laparoscopic Staging of Gynecologic Malignancies

R. Kevin Reynolds, MD, William M. Burke, MD, Arnold P. Advincula, MD

ABSTRACT

Objective: To evaluate the feasibility of integrating robot-assisted technology in the performance of laparoscopic staging of gynecologic malignancies.

Methods: Seven patients underwent robot-assisted laparoscopic staging procedures for gynecologic cancers. Data were collected and analyzed as a retrospective case series analysis.

Results: We attempted 7 robot-assisted laparoscopic staging procedures with no conversions to laparotomy. The median lymph node count for lymphadenectomy was 15 (range, 4 to 29). Mean operating time was 257 minutes (range, 174 to 345). The average estimated blood loss was 50 mL. One patient developed sinusitis and required intravenous antibiotics. The median hospital stay was 2 days.

Conclusion: Robot-assisted laparoscopic staging is a feasible technique that may overcome the surgical limitations of conventional laparoscopy.

Key Words: Robot-assisted laparoscopy, Cancer staging, Gynecologic cancer, Surgical technique.

INTRODUCTION

Historically, gynecologic cancers have been treated with multimodal therapy including radical surgery combined with radiation and chemotherapy based on the stage and type of disease. Although this approach has resulted in a substantial improvement in outcomes, it has come at the cost of significant patient morbidity. In the last 15 years, laparoscopic approaches for many gynecologic surgical procedures for cancer have been developed, resulting in a reduction in postoperative morbidity and emerging evidence of outcomes that appear to match those of laparotomy. Complete staging procedures including abdominal exploration, hysterectomy, pelvic and para-aortic lymphadenectomy, omentectomy, and peritoneal biopsies can be performed in a minimally invasive setting with laparoscopy.¹⁻³

Limitations to the conventional laparoscopic approach to gynecologic oncology surgery include lack of depth perception due to 2-dimensional imaging, instruments with limited range of motion, poor ergonomics for the surgical team including unstable camera images and awkward operating positions, and a lengthy training interval to attain laparoscopic competence. Despite these pitfalls, a number of manuscripts have been published demonstrating the feasibility and applicability of the laparoscopic approach to gynecologic oncology surgery.

The da Vinci telerobotic laparoscopic system is an innovative technology that addresses many of the current limitations of laparoscopy, including development of a 3-dimensional vision system for the surgeon, and laparoscopic instruments with a wrist-like mechanism, allowing full replication of the range of motion of the surgeon's hand with an 8-mm instrument. The da Vinci Robotic Surgical System (Intuitive Surgical, Inc. Sunnyvale, CA) is composed of 3 components (**Figure 1**). The first component is the surgeon's console, located away from the patient bedside. The surgeon sits at the surgeon's console and uses a stereoscopic viewer in addition to hand manipulators ("masters") and foot pedals that translate coordinated hand and foot movements into identical movement of the instruments within the patient (**Figure 2**). The second component of the da Vinci Robotic Surgical System is the InSite Vision System that provides a 3-dimensional image through a 12-mm endoscope containing stereoscopic cameras and dual optical channels. The third component of the

Department of Obstetrics and Gynecology, University of Michigan Medical Center, Ann Arbor, Michigan, USA (all authors).

Address reprint requests to: R. Kevin Reynolds, MD, Division of Gynecologic Oncology, Department of Obstetrics and Gynecology, University of Michigan Medical Center, L 4000 Women's Hospital, 1500 East Medical Center Dr, Ann Arbor, MI 48109-0276, USA. Telephone: 734 615 3773, Fax: 734 764 7261, E-mail: rkr@umich.edu

© 2005 by JSLs, *Journal of the Society of Laparoendoscopic Surgeons*. Published by the Society of Laparoendoscopic Surgeons, Inc.

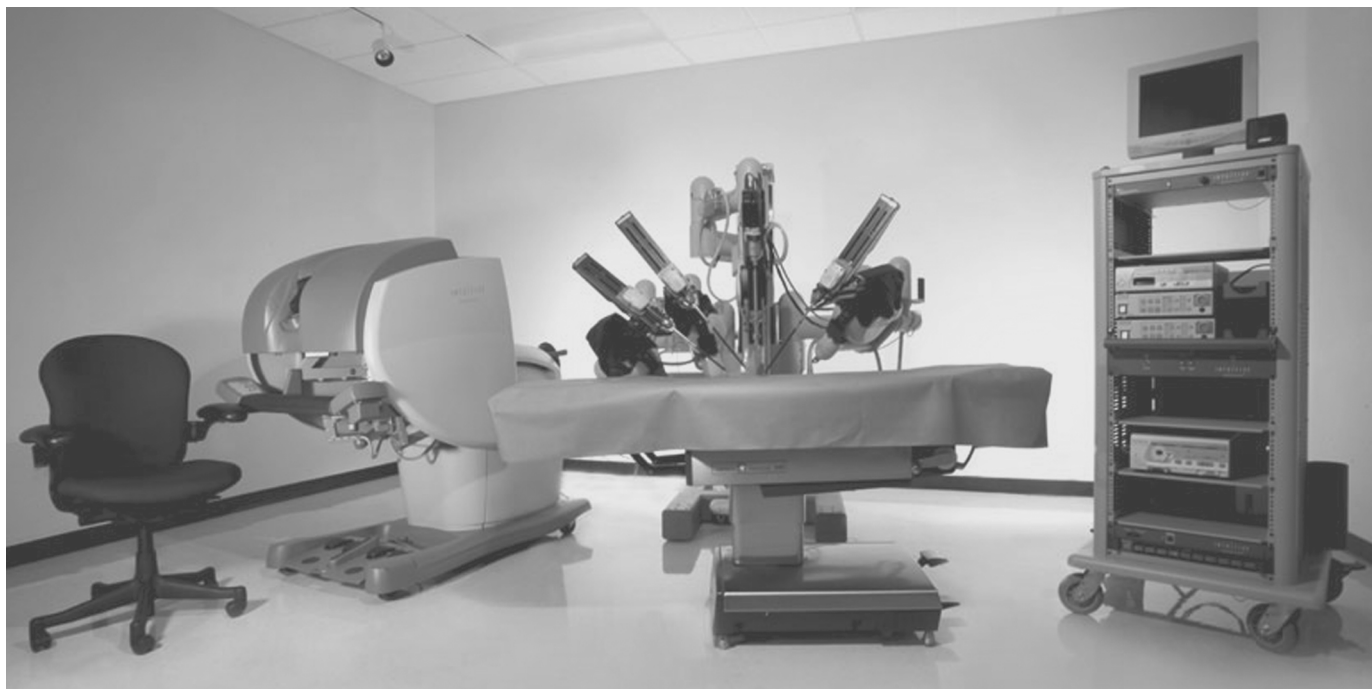


Figure 1. Photograph of the da Vinci Robotic Surgical System. From left to right: surgeon's console, patient-side surgical cart, and InSite vision tower. Photo courtesy of Intuitive Surgical.

da Vinci Robotic Surgical System is the patient-side cart with telerobotic arms and EndoWrist instruments. Currently, this system is available with either 3 or 4 robotic arms. One of the arms holds the laparoscope while the other 2 to 3 arms hold the various laparoscopic surgical instruments. These EndoWrist instruments are unique in that they possess a mechanical wrist that allows 7 degrees of freedom of motion, thereby replicating the full range of motion of the surgeon's hand. Movement is intuitive, and therefore the fulcrum effect seen with conventional laparoscopy is eliminated. A series of EndoWrist instruments can be interchanged on either of the lateral robotic arms.

Recent publications⁴⁻⁹ have illustrated the applicability of robot-assisted (telerobotic) laparoscopy for heart surgery, fallopian tube reanastomosis, ovarian transposition, bowel resection and anastomosis, hysterectomy, and pelvic lymphadenectomy. As yet, no publications in the peer review literature describe the technique and outcomes for many gynecologic procedures that are currently approached with conventional laparoscopic instrumentation, such as gynecologic oncology staging procedures, or myomectomy.

In November 2001, the University of Michigan Department of Obstetrics and Gynecology began a structured robot-assisted laparoscopy program. To date, 83 patients have undergone gynecologic procedures in this

program, including the 7 cancer staging procedures to be reported here. This report will outline the technique and initial results of gynecologic oncology staging procedures using the da Vinci telerobotic laparoscopy surgical system.

METHODS

We performed a review of data collected from the initiation of our robot-assisted surgery program, after obtaining approval from our Institutional Review Board (IRB #2003-0763). All robot-assisted laparoscopic staging procedures attempted at the University of Michigan Medical Center between August 2002 and May 2004 were analyzed based on the intent to treat. A robot-assisted approach was offered to patients with complex gynecologic pathology. The authors performed all the procedures.

All patients were placed in the low dorsal lithotomy position with arms padded and tucked after general anesthesia was administered. For patients with an intact uterus, a RUMI uterine manipulator was placed in conjunction with a Koh colpotomy ring and vaginal pneumo-occluder balloon (**Figure 3**). Four ports were typically used after pneumoperitoneum was obtained. A 12-mm camera port



Figure 2. Photograph of the da Vinci master controls showing translation of surgeon hand movement to the EndoWrist instruments attached to the robotic arms. Photo courtesy of Intuitive Surgical.

was placed either at or above the umbilicus, depending on the size of the uterus (**Figure 4**). Two 8-mm ports that mount directly to the operating arms on the patient-side cart were placed in the left and right lower quadrants, respectively. A fourth port served as an accessory port and was placed between the camera port and the right lower quadrant port. This was typically a 12-mm port to facilitate introduction of suture and instruments for assisting with exposure in addition to specimen removal.

Once all 4 ports were in place, the patient was placed in a steep Trendelenburg position, and the patient-side cart was brought between the patient's legs and docked, meaning that each port was attached to the assigned robotic arm with the exception of the accessory port. The assisting surgeon, at the right side of the patient, was responsible for EndoWrist instrument exchanges and for use of the assist port to aid in traction and exposure or removal of specimens. EndoWrist instruments used in-

cluded Cadiere (fenestrated) forceps, DeBakey forceps, round-tip scissors, needle driver, monopolar electrocautery using a hook tip, and bipolar cautery forceps.

A survey of the operative field was performed and washings were obtained. The retroperitoneum was opened by incising lateral and parallel to the infundibulopelvic ligament from the pelvic brim to the round ligament. Peritoneal edges were elevated and underlying connective tissues were bluntly separated with careful opposing traction parallel to the vessels to open the retroperitoneal space by using the Cadiere and monopolar hook instruments. Once pelvic vessels and ureters were identified, lymph nodes were isolated and removed by incising tissues lateral and parallel to the external iliac artery extending from the bifurcation of the common iliac artery to the crossover of the deep circumflex iliac vein over the external iliac artery. The lymphatic bundle was retracted medially and dissected from the external iliac artery and vein. The obturator space was exposed by lateral retraction of the external iliac vein and lymphatic tissues were dissected free from posterior attachment to the external iliac vein and lateral attachment to the pelvic sidewall. Care was taken to identify the obturator nerve, which was stripped free of attachment to the lymphatic tissues. Common iliac and para-aortic nodes up to the level of the inferior mesenteric artery were obtained with the same port and patient-side cart placements. It was rarely necessary to change to different EndoWrist instruments during the lymphadenectomy. Common iliac nodes were obtained by extending the peritoneal incision above the pelvic brim and reflecting the peritoneum medially to expose the common iliac vessels. Low para-aortic nodes were obtained by incising peritoneum over the right common iliac artery and extending along the aorta.

Para-aortic nodes above the inferior mesenteric artery are difficult to obtain without redocking the patient-side cart due to limitation in the range of motion of the joints in the robotic arms. To attain high para-aortic nodes, the patient-side cart is undocked from the patient, and the operating room table is rotated 180 degrees such that the surgical tower is brought in over the patient's head and shoulders. The robot is redocked to the existing ports for para-aortic access. Alternatively, the upper para-aortic nodes can be removed by undocking the robot and using the laparoscope and ports in a conventional laparoscopic approach.

The approach to hysterectomy was consistent with the American Association of Gynecologic Laparoscopists (AAGL) type IVE laparoscopic hysterectomy.¹⁰ The technique for hysterectomy included division of the round

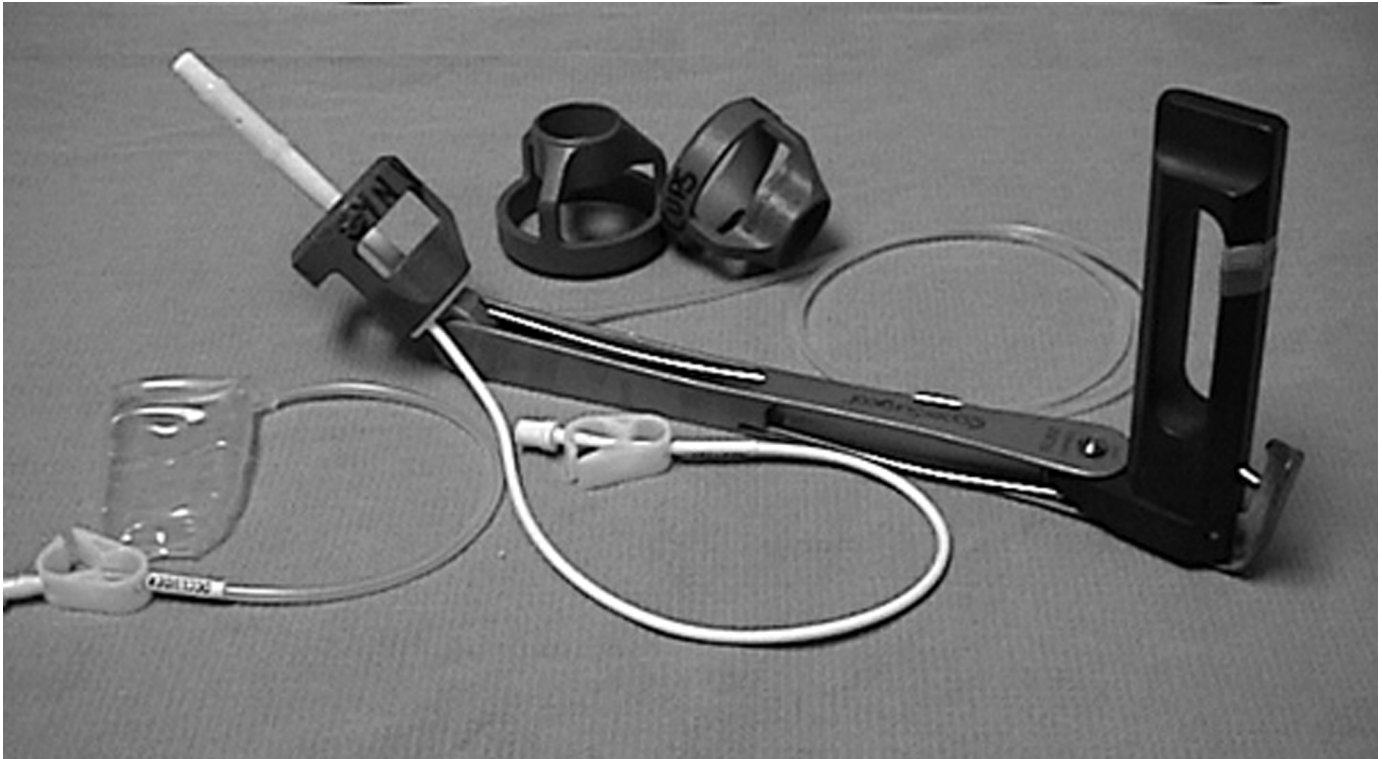


Figure 3. RUMI uterine manipulator is used to manipulate the uterus during surgery, and the Koh colpotomy ring is used to provide an insulated backstop for the colpotomy incision. The vaginal pneumo-occluder balloon maintains the pneumoperitoneum once the colpotomy incision is made. (Cooper Surgical Inc., Trumbull, CT)

ligament with the monopolar hook. Peritoneum overlying the vesico-uterine fold was incised using the monopolar hook after elevating peritoneum and using the uterine manipulator to deflect the uterus. Infundibulopelvic ligaments were doubly ligated with 0-Vicryl suture tied intracorporeally with the EndoWrist DeBakey and needle driver. Uterine arteries were skeletonized by using the monopolar hook and countertraction. The uterine vessels were then suture ligated using 0-Vicryl suture placed using the EndoWrist needle driver. The monopolar hook was utilized to develop the colpotomy incision overlying the Koh colpotomy ring. The vaginal vault was closed with interrupted figure of eight stitches made by using 0-Vicryl suture on CT-2 needles.

In cases where omentectomy was required for staging, the omentum was placed on gentle traction, elevating from the transverse colon, and the underlying vascular tissues were divided using EndoWrist harmonic shears, which, unlike the other EndoWrist instruments, have 4 degrees of freedom rather than 7 degrees of freedom, resulting in a decreased ability to manipulate the instrument optimally. The omentum was cut into strips for removal through the accessory port.

Upon completion of the staging procedure, the pelvis was irrigated, and a low pressure check was performed to ensure hemostasis. The patient-side cart was undocked. All ports larger than 8 mm in diameter were closed with interrupted 0-Vicryl suture on the fascia.

RESULTS

To date, we have completed 7 procedures with no conversions to laparotomy. Four patients underwent a total laparoscopic hysterectomy (AAGL type IVE) and 2 patients previously had undergone hysterectomy for various indications. One of the 4 patients who underwent laparoscopic hysterectomies had undergone a recent da Vinci robot-assisted procedure performed for a benign indication after which an occult fallopian tube carcinoma was detected. She underwent a second da Vinci robot-assisted procedure for staging that is reported in this series as patient #2 (**Tables 1 and 2**). Four patients underwent staging for endometrial cancer: 2 were staged for ovarian cancer, and 1 was staged for fallopian tube cancer. Six patients underwent pelvic and para-aortic lymphadenec-

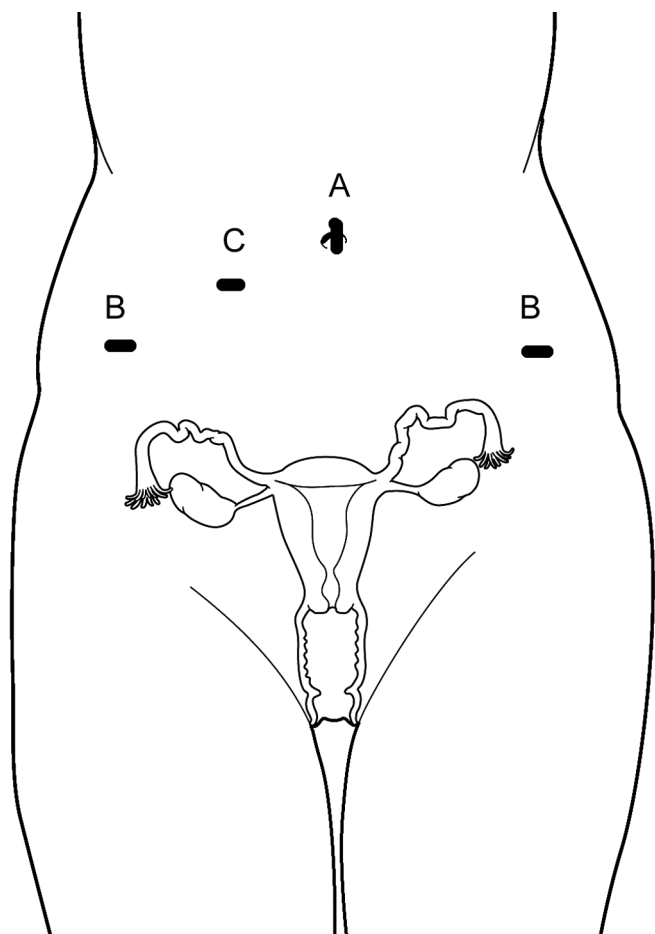


Figure 4. Port Placement. (A) The 12-mm camera port was placed in the umbilicus or above, depending on the size of the uterus. (B) The 8-mm lateral ports for robotic instruments mount directly to the robotic arms and were placed 2 cm to 3 cm medial and superior to the anterior superior iliac spine with modification based on size of the uterus. (C) The assist port was placed between the camera port and the right lower quadrant port. This was typically a 12-mm port, used to facilitate introduction of suture and suction/irrigation instruments.

tomy, and 1 patient underwent pelvic lymph node sampling. Omentectomy and peritoneal staging biopsies were performed for the patients with ovarian and fallopian cancers. Most of these patients had prior abdominal or pelvic surgery and were therefore thought to have a significantly higher risk for adhesions (**Table 1**).

The mean age was 47.6 years (range, 42 to 68). The mean body mass index was 27 kg/m² (range, 22 to 39.6). The median number of lymph nodes removed in patients undergoing lymphadenectomy was 15 (range, 4 to 29) (**Table 1**). The node count provided by our pathology de-

partment uses only macroscopic lymph nodes with an identifiable capsule and does not count microscopic nodes or lymphoid aggregates in the specimen. **Figure 5** demonstrates the EndoWrist instruments in use for the pelvic lymphadenectomy, and **Figure 6** illustrates the level of completeness of the lymphadenectomy.

Estimated blood loss (EBL) was calculated by noting the difference between the volumes of aspirated and irrigated fluids. The mean estimated blood loss was 50 mL. No blood transfusions were administered in our series. The mean operating time was 257 minutes (range, 174 to 345). Operative time was counted from the initial examination with the patient under anesthesia until the dressing was applied. The median hospital stay for all patients in our series was 2 days (range, 1 to 6).

Stages determined by robot-assisted staging are listed in **Table 2**. All stages were defined by using International Federation of Gynecology and Obstetrics (FIGO) rules. Adjuvant therapy, such as radiation or chemotherapy, was chosen based on tumor type, grade, and stage. All patients were alive and without evidence of recurrent disease at the time this series was reported. Duration of follow-up ranged between 4 months and 25 months (**Table 2**). One patient (#5) has subsequently conceived and is nearing term with a pregnancy that has proceeded normally.

The only complication in this series was sinusitis in 1 patient that developed postoperatively and was felt to be a complication of anesthesia. The patient required intravenous antibiotics for 5 days. No intraabdominal complications, port-site metastases, or recurrences were noted.

DISCUSSION

Endometrial cancer is the most common gynecologic cancer in the United States. Current staging and surgical treatment of early-stage endometrial cancer include cytologic washings of the peritoneum, hysterectomy, and bilateral salpingo-oophorectomy. Selective pelvic and para-aortic lymphadenectomy is usually performed based on risk factors, such as tumor grade and depth of myometrial invasion. A recent study by Eltabbakh² reports on 90 women with clinical stage I disease. In this series, 90% of patients underwent complete laparoscopic staging. Among women who underwent laparoscopy, 5.8% required conversion to laparotomy. The authors found that laparoscopic patients had significantly smaller body mass indices, longer surgical times, more pelvic lymph nodes retrieved, a smaller change in postoperative hematocrit, lower pain medication requirements, and shorter hospital stays compared with patients who had the same

Table 1.
Preoperative and Intraoperative Data

Patient	Cancer Type	Prior Pelvic Surgery*	Robotic Procedure*	Node Count
1	Endometrial	Appendectomy, distant past. Abdominal hysterectomy 6 weeks prior	BSO, PLN	5
2	Fallopian tube	da Vinci TLH 2 weeks prior	PLN, PAN, omentectomy, peritoneal biopsies	17
3	Endometrial	Abdominal hysterectomy, bilateral salpingo-oophorectomy 10 weeks prior	PLN	4
4	Endometrial	Appendectomy, distant past	TLH, BSO, PLN, PAN, peritoneal biopsies	29
5	Ovarian	Right ovarian cystectomy, 8 weeks prior	Right oophorectomy, right PLNS, omentectomy, peritoneal biopsies	1
6	Ovarian	None	TLH, BSO, PLN, PAN, omentectomy, peritoneal biopsies	15
7	Endometrial	None	TLH, BSO, PLN, PAN	18

*BSO=bilateral salpingo-oophorectomy; PLN=pelvic lymphadenectomy; PLNS=pelvic lymph node sampling; PAN=paraortic lymphadenectomy; TLH=total laparoscopic hysterectomy, AAGL Class IV-E.

Table 2.
Postoperative Data

Patient	Cancer Type	Grade*	FIGO Stage	Adjuvant Therapy	Disease Status*	Follow Up (mos.)
1	Endometrial	2	IB	None	NED	25
2	Fallopian tube	2	IA	Carboplatin-paclitaxel chemo, 3 cycles	NED	21
3	Endometrial	3	IA	None	NED	17
4	Endometrial	3	IIIA	Pelvic radiotherapy, 4500 cGy	NED	14
5	Ovarian	LMP	IC	None	NED	12
6	Ovarian	3	IV	Carboplatin-paclitaxel chemo, 3 cycles preop and 3 cycles postop	NED	7
7	Endometrial	2	IB	None	NED	4

*LMP=ovarian tumor of low malignant potential; NED=no evidence of disease.

procedure via laparotomy. A recent, randomized, prospective comparison of laparoscopy versus laparotomy for treatment of 70 women with endometrial cancer revealed no difference in recurrence rate or duration of survival.¹¹ The power of the study was low due to the small sample size of the 2 groups. The Gynecologic Oncology Group is currently accruing patients into a large phase III, randomized trial of laparoscopic versus laparotomy surgery for endometrial carcinoma. The primary objectives of this study are to compare

complications, length of stay, quality of life, and cancer outcome.

Ovarian cancer is the deadliest gynecologic malignancy. The accepted approach for treatment of ovarian cancer is surgical staging and debulking followed in most cases by adjuvant chemotherapy based on tumor type and stage of disease. Epithelial ovarian cancers are the most common type, with malignant germ cell and stromal tumors each

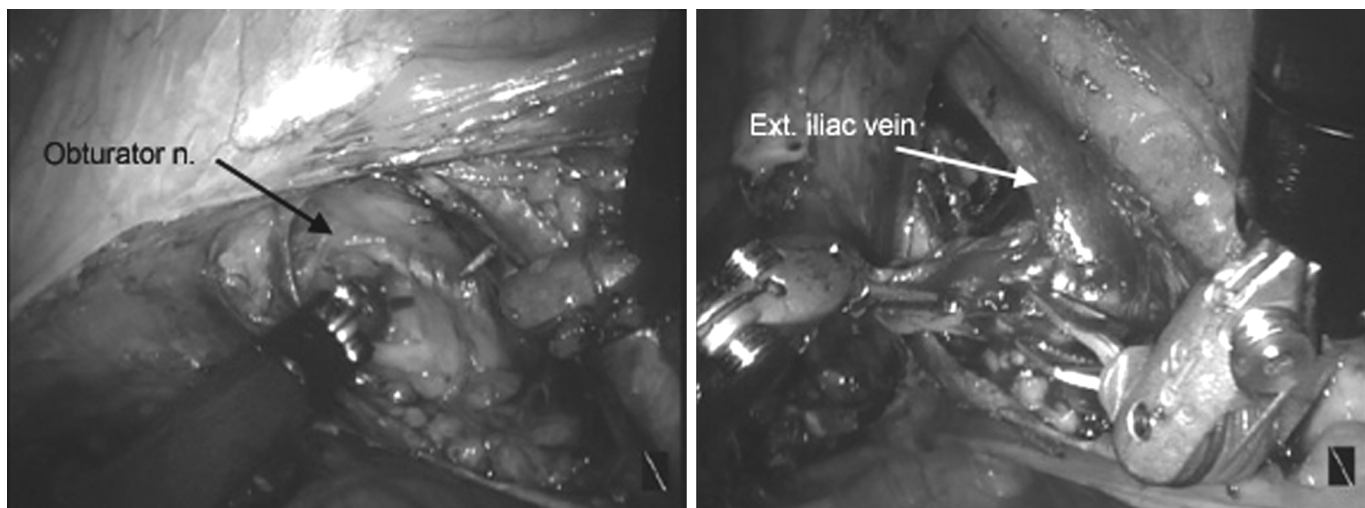


Figure 5. Photographs of retroperitoneal dissection during right pelvic lymphadenectomy. In the left frame, EndoWrist DeBakey and monopolar hook instruments are used to dissect out the obturator nerve. In the right frame, an EndoWrist bipolar forceps is used to remove a node bundle from the external iliac vein.

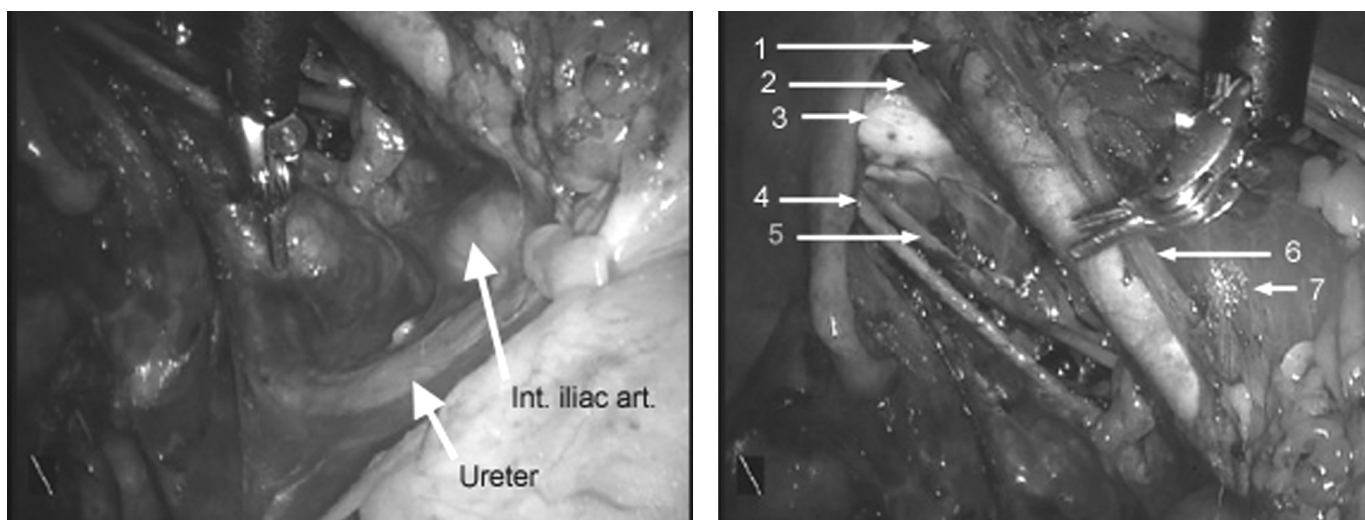


Figure 6. Photographs of the right pelvic lymphadenectomy. In the left frame, an EndoWrist DeBakey is elevating a node from the underlying ureter and internal iliac artery. In the right frame, the pelvic node dissection has been completed, showing the skeletonized external iliac artery (1) and vein (2), ischial periosteum (3), anterior division of the hypogastric artery (4), obturator nerve (5), genitofemoral nerve (6), and psoas muscle (7).

accounting for about 5% of the total. Epithelial cancers are most common in perimenopausal women and are most often detected in advanced stages, whereas germ cell and stromal malignancies are usually unilateral and occur predominately in young, reproductive-age women. These variations of natural history alter the surgical approach. For example, a young woman presenting with a unilateral germ cell malignancy would more likely be treated with a unilateral salpingo-oophorectomy and staging procedure

with preservation of fertility as an option and would be a good candidate for laparoscopic staging. On the other hand, a postmenopausal woman presenting with a disseminated ovarian epithelial carcinoma would require a radical debulking procedure for which laparoscopy is ill suited. In the last 13 years, many small, retrospective series¹ have been published, demonstrating the feasibility of laparoscopic staging for ovarian cancer. In an early series by Surwit and Childers,¹² 138 patients underwent

laparoscopic staging for ovarian cancer. Laparoscopic detection of abdominal and lymphatic metastases was equivalent to historical controls for staging by laparotomy. Eight percent were converted to laparotomy and 50% were able to be fully staged laparoscopically. A recent series by Querleu³ evaluated 30 individuals who underwent laparoscopic staging. All were able to be laparoscopically staged with a mean operative time of 165 minutes; a 7% major complication rate and a 2.7-day mean length of stay. As yet, no, prospective, randomized comparisons of laparoscopy to laparotomy for staging and treatment of ovarian cancer have been published.

Our hypothesis is that two of the most significant reasons that laparoscopy is not used for more patients with ovarian and endometrial cancer are the relative paucity of outcomes data as discussed above, in addition to technical limitations of laparoscopy. The technical limitations can be patient-specific, or technique-specific. Patient-specific limitations include issues like obesity, the presence of a large mass, or ascites. Technique-specific limitations include lack of depth perception due to 2-dimensional imaging; instruments with a limited range of motion due to fixed, straight shafts with a fulcrum effect; cancer-associated issues like port-site metastases; and the increased importance of training and experience for laparoscopy compared with laparotomy.¹³ The fulcrum effect, where the motion of the instrument tip is opposite to the direction of movement of the operator's hand, occurs because the instrument pivots across the fulcrum of the abdominal wall. Compensation for this counterintuitive motion lengthens the laparoscopy learning curve.

Obesity is a major impediment to the completion of laparoscopic procedures. Because obesity is one of the major predisposing risk factors for developing endometrial cancer, many patients who ultimately need surgical staging are well above their ideal body weight. In one study,¹⁴ 42 women with endometrial cancer and a body mass index (BMI) ≥ 28.0 were offered laparoscopic staging and were compared with a group of matched controls who underwent abdominal procedures. The mean BMI for patients was 35.8. Conversion to laparotomy occurred in 7.5% of patients. The BMI of patients in this series was as high as 39.6 kg/m². No case was converted to laparotomy in this series. Obesity has thus far not proven to be a contraindication to robot-assisted laparoscopic staging.

Although no absolute upper limit exists for the size of the mass for laparoscopy, laparotomy is indicated if the size and position of the mass precludes safe placement of ports. Masses with a significant solid component or mul-

tle septations are not amenable to removal through a laparoscopic port because they cannot be readily reduced in size without likely spillage into the peritoneal cavity. No patient in this series had a large or predominantly solid mass, ascites, or fixation to adjacent organs. Port-site metastasis is reported to occur in 1% to 2% of cases and may be associated with implantations caused by surgical technique; positive intraabdominal pressure, causing leakage around port sites (chimney effect); and pneumoperitoneum effects on local immune reactions and tumor cells.¹⁵ None of the patients reported in this series has had a port-site metastasis.

Qualifications of the surgeon are critical for all laparoscopic staging procedures. First, it is well documented that operative laparoscopy has a lengthy learning curve before competence is high and complication rates are reduced. Training and credentialing for advanced operative laparoscopy should be a high priority to maximize patient safety. Second, several published reports document increased accuracy of surgical staging, increased likelihood of optimal debulking, and prolongation of survival for ovarian cancer patients who are staged by a gynecologic oncologist. This resulted in a recommendation by the National Cancer Institute that women with masses having a significant risk of malignancy should be given the opportunity to have surgery performed by a gynecologic oncologist.¹⁶

Despite improvements in endoscopic technology and increasing application of the laparoscopic approach, laparoscopic hysterectomy procedures remain in the minority of all hysterectomies performed. One reason is the lack of laparoscopic surgical training of gynecologic surgeons.¹⁷ A report¹⁸ on the rate of laparoscopic hysterectomy in 23 French medical centers revealed that only 9 centers carried out total laparoscopic hysterectomies and that training was found to be a major factor in the choice of technique. When access to surgical training is available, the learning curve for conventional laparoscopy and prevention of associated complications are still significant limitations to widespread application. Although no absolute contraindications exist for laparoscopic hysterectomy and staging, a surgeon's experience and the pathology encountered remain the limiting factors for performing laparoscopic hysterectomy. A recent publication from Finland¹⁹ revealed an equivalent complication rate for laparoscopic hysterectomy compared with abdominal hysterectomy, once the surgeon passes a learning threshold of the first 30 procedures. In a prospective, randomized Italian study,²⁰ it was shown that total laparoscopic hysterectomy could be effectively performed within reasonable time limits and that operating times are comparable

with those of abdominal hysterectomy, provided that operators are experienced surgeons.

Robot-assisted laparoscopy addresses many of the limitations of conventional laparoscopy. The strengths of the da Vinci Robotic Surgical System include 3-dimensional depth perception for the operating surgeon and coordinated, complex movements of the EndoWrist instruments that mimic the surgeon's hands. Tasks like instrument tying and suturing can be performed with the same fluidity, ease, and rapidity of an open surgical procedure.

The use of robotic technology to facilitate laparoscopic procedures has increased dramatically. In numerous studies, it has been shown to be a safe and effective alternative to conventional laparoscopic surgery in a variety of surgical disciplines. In the gynecology literature, reports^{5,6} exist of robot-assisted laparoscopy for tubal reanastomosis and hysterectomy. One of our hypotheses is that the use of robot-assisted laparoscopy may rapidly bridge the gap between assimilation of technique and the actual application of the procedure. A recent study²¹ confirmed this principle: the impact of robotics on surgical skills was assessed by comparing conventional laparoscopy with the da Vinci Robotic Surgical System in the performance of 4 training drills. Surgeons completed drills faster with the robotic system. Most importantly, the study concluded that the "playing field" between novice and expert laparoscopic surgeons was leveled with the use of the robotic system.²¹

The cases in our series could have been completed by conventional laparoscopy, but we believe completion of these complex cases was facilitated by the robotic system. This was especially true in cases where patients had previously undergone several pelvic surgeries. As seen in **Table 1**, 4 of the 7 patients had one or more prior pelvic surgical procedures that resulted in scarring or partial obliteration of the cul de sac in all 4 patients. The mechanical-wrist instruments of the da Vinci Surgical System allowed improved dexterity that readily overcame these difficulties.

A limitation of the system in its current form is the lack of tactile feedback for the operating surgeon. Consequently, it is easy to break sutures or to apply excessive force to tissues until the operating surgeon learns to recognize force applied by visual cues, such as tissue blanching or deflection of soft tissue structures. In addition, the assistant does not have the advantage of a 3-dimensional view and must work around bulky equipment when the robotic surgical tower is docked. As technology evolves, this issue will need to be addressed.

Operative times were much longer than those reported in

most published studies of conventional laparoscopic staging. This can be broken down into several areas for analysis and discussion. First, we measured operative time starting with the examination with the patient under anesthesia rather than only the time for use of the robot. We felt this was the most realistic method for estimation of operating room time and resources. Second, published reports do not use a standardized definition of operative time, and many authors report only the laparoscopic time. The operative times reported in this manuscript are therefore longer than times in many other reports because of this definition. In our institution, a comparison of laparoscopic staging of gynecologic malignancies by using conventional laparoscopic technology versus robot-assisted staging reveals less than 30 additional minutes for robot-assisted procedures (unpublished data). We expect to see substantial improvement as our experience increases.³ Despite longer operative times with the robot-assisted approach, the length of hospital stay was comparable to that reported for other studies of laparoscopic staging procedures and better than those for abdominal staging procedures. Blood loss in this series was minimal, and no transfusions were needed.

Lymph node count in our institution is based on identifying macroscopic nodes with a discreet capsule rather than microscopic nodes or lymphoid aggregates without a capsule. The surgical procedure performed at our institution is complete lymphadenectomy rather than lymph node sampling, regardless of surgical approach (laparotomy versus conventional laparoscopy versus robot-assisted laparoscopy). **Figure 6** illustrates the completeness of dissection. No differences existed between lymph node count as a function of the surgical approach at our institution (unpublished data).

One patient in this series had a postoperative complication. She developed sinusitis thought to be due to her anesthetic. She required intravenous antibiotics for 5 days following surgery. This complication was not felt to be attributable to the use of a robot-assist device. No intra-abdominal complications occurred.

A frequent criticism of laparoscopic surgery is the high surgical cost due to prolonged operative time, complex equipment, and expensive disposable instruments. Spiros²² compared cost and quality of life associated with surgical treatment of early stage endometrial cancers treated with laparoscopy versus laparotomy in 30 women. Patients undergoing laparoscopy had higher operating room and anesthesia costs but were noted to have a significant reduction in their overall medical costs (\$13,809 compared to \$19,158) and improved quality of

life. The cost of using a robot-assist device is substantially higher than the cost of conventional laparoscopy. We are tracking cost data, but will need a substantially larger series to provide a comparison of benefit versus cost.

CONCLUSION

This is the first series to report technique and outcome for robot-assisted laparoscopic staging of gynecologic malignancies. Based on our early experience, the use of robot-assisted technology like the da Vinci Surgical System is feasible for total hysterectomy and staging of gynecologic malignancies. As our experience evolves, a more accurate comparison of robot-assisted to conventional laparoscopic staging outcomes can be developed to assess relative advantages and disadvantages of this new technology. The evolving literature on robot-assisted surgery suggests that surgical limitations of conventional laparoscopy can be overcome and that the skill level of the surgeon may be enhanced independently of prior laparoscopic experience. Although the first-generation da Vinci Robotic Surgical System provides improved imaging and instrumentation, the absence of tactile feedback and the high cost of the technology remain limitations. Future areas of study will include improvement of technique, and evaluation of robotic technology on surgical training and competence, in addition to development of cost reduction strategies.

References:

1. Reynolds RK, Burke WM. The evolving role of laparoscopic surgery for treatment of gynecologic masses and cancers. *Female Patient*. 2004;29(4):25–32.
2. Eltabbakh GH, Shamonki MI, Moody JM, Garafano LL. Laparoscopy as the primary modality for the treatment of women with endometrial carcinoma. *Cancer*. 2001;91(2):378–387.
3. Querleu D, Papageorgiou T, Lambaudie E, Sonoda Y, Narducci F, Leblanc E. Laparoscopic restaging of borderline ovarian tumors: results of 30 cases initially presumed as stage IA borderline ovarian tumour. *BJOG*. 2003;110:201–204.
4. Carpentier A, Loulmet D, Aupecele B, Berrebi A, Relland J. Computer-assisted cardiac surgery. *Lancet*. 1999;353:379–380.
5. Degueldre M, Vandromme J, Huong PT, Cadiere GB. Robotically-assisted laparoscopic microsurgical tubal reanastomosis: a feasibility study. *Fertil Steril*. 2000;74:1020–1022.
6. Diaz-Arrastia C, Jurnalov C, Gomez G, Townsend C. Laparoscopic hysterectomy using a computer-enhanced surgical robot. *Surg Endosc*. 2002;16:1271–1273.
7. Molpus KL, Wedergren JS, Carlson MA. Robotically assisted endoscopic ovarian transposition. *JSLS*. 2003;7:59–62.
8. Weber PA, Merola S, Wasielewski A, Ballantyne GA. Telerobotic-assisted laparoscopic right and sigmoid colectomies for benign disease. *Dis Colon Rectum*. 2002;45:1689–1696.
9. Guillonneau B, Cappele O, Martinez JB, Navarra S, Vallancien G. Robotic assisted, laparoscopic pelvic lymph node dissection in humans. *J Urol*. 2001;165:1078–1081.
10. Olive DL, Parker WH, Cooper JM, Levine RL. The AAGL classification system for laparoscopic hysterectomy. *J Am Assoc Gynecol Laparosc*. 2000;7:9–15.
11. Malur S, Possover M, Michels W, Schneider A. Laparoscopic-assisted vaginal versus abdominal surgery in patients with endometrial cancer- a prospective randomized trial. *Gynecol Oncol*. 2001;80:239–244.
12. Surwit EA, Childers JM. Cancer of the ovary. In: Querleu D, Childers JM, Dargent D, eds. *Laparoscopic Surgery in Gynaecological Oncology*. London: Blackwell Science; 1999.
13. Wattiez A, Soriano D, Cohen SB, et al. The learning curve of total laparoscopic hysterectomy: comparative analysis of 1647 cases. *J Am Assoc Gynecol Laparosc*. 2002;9:335–341.
14. Eltabbakh GH, Shamonki MI, Moody JM, Garafano LL. Hysterectomy for obese women with endometrial cancer: Laparoscopy or laparotomy? *Gynecol Oncol*. 2000;78:329–335.
15. Ramirez PT, Wolf JK, Levenback C. Laparoscopic port-site metastases: etiology and prevention. *Gynecol Oncol*. 2003;91:179–189.
16. National Institutes of Health Consensus Development Conference Statement. Ovarian cancer: screening, treatment, and follow-up. *Gynecol Oncol*. 1994;55:S4–S14.
17. Wattiez A, Cohen SB, Selvaggi L. Laparoscopic hysterectomy. *Cur Opin Obstet Gynecol*. 2002;14:417–422.
18. Chapron C, Laforest L, Ansquer Y, Fauconnier A, et al. Hysterectomy techniques used for benign pathologies: results of a French multicenter study. *Hum Reprod*. 1999;14:2464–2470.
19. Makinen J, Johansson J, Tomas C, et al. Morbidity of 10,110 hysterectomies by type of approach. *Hum Reprod*. 2001;16:1473–1478.
20. Perino A, Cucinella G, Venezia R, et al. Total laparoscopic hysterectomy versus total abdominal hysterectomy: an assessment of the learning curve in a prospective randomized study. *Hum Reprod*. 1999;14:2996–2999.
21. Sarle R, Tewari A, Shrivastava A, Peabody J, Menon M. Surgical robotics and laparoscopic training drills. *J Endourol*. 2004;18:63–67.
22. Spirtos NM, Schlaerth JB, Gross G, et al. Cost and quality-of-life analyses of surgery for early endometrial cancer: laparotomy versus laparoscopy. *Am J Obstet Gynecol*. 1996;174:1795–1800.