

## Sialadenitis following blepharoplasty: An unusual sequelae

Harsha S Reddy, Phillip A Tenzel, Akshay Gopinathan Nair<sup>1</sup>

**Key words:** Anesthesia, blepharoplasty, parotid, sialadenitis, sialolithiasis, swelling

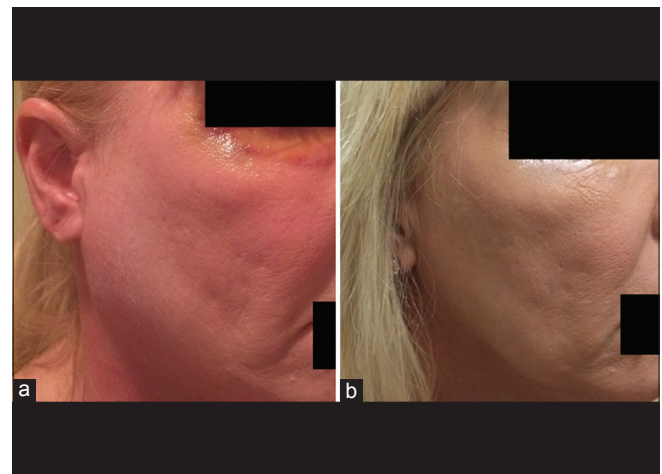
A 64-year-old female underwent an uneventful bilateral upper and lower lid blepharoplasty under local anesthesia with sedation. Postoperatively, painless right lower facial swelling [Fig. 1a] was noted. Visual acuity, intraocular pressures, and ocular motility were normal. Ocular examination showed no unexpected findings. The evaluation revealed induration and tenderness of the body and tail of the parotid gland, and a clinical diagnosis of sialadenitis was made. Warm compresses, oral amoxicillin/clavulanic acid, and anti-inflammatory medication helped in resolution of the condition over the next 1 week. Her subsequent recovery was uneventful.

Sialadenitis is a relatively common condition and can occur after any surgical procedure and should be distinguished from lymphedema or cellulitis. Our patient did not have any underlying systemic illness that could predispose to sialadenitis such as Sjögren's syndrome, diabetes, or HIV infection. Anesthesia and surgery themselves are known risk factors for salivary stasis.<sup>[1]</sup> We hypothesize that in addition to these factors, the immobilization during the surgery, followed by postoperative low fluid intake, and the subsequent relative dehydration were the contributing factors that led to salivary stasis that precipitated sialadenitis. As was the case with our patient [Fig. 1b], symptoms generally resolve with antibiotics, warm compresses, and lemon juice intake that stimulate increase in the flow of saliva from the glands. Imaging to rule out abscess should be considered if conservative management fails.

Acute unilateral enlargement of the parotid gland or "anesthesia mumps" is an entity described in both surgical and anesthesia literature. This condition has been described previously in the elderly, dehydrated, poorly nourished, and

postoperative patients.<sup>[2,3]</sup> This condition has been commonly reported after endotracheal general anesthesia. Matsuki *et al.* reported that transient swelling of the parotid glands following general anesthesia could be attributed to inadequate anesthesia during intubation, overactive pharyngeal reflex stimulation of the salivary gland through the parasympathetic nerves, and succinylcholine-stimulated copious secretions.<sup>[4]</sup> In the pediatric age group, postoperative sialadenitis is seen following cranial surgeries, especially skull base surgeries that require extreme head positioning for long hours.<sup>[5]</sup> Perioperative use of medications with anticholinergic effects can also predispose patients to salivary stasis. By inducing diuresis or through the anticholinergic process, many drugs such as antihistamines, phenothiazines,  $\beta$ -blockers, barbiturates, and diuretics can contribute to systemic dehydration, which increases the risk of salivary stasis.<sup>[1]</sup> Other predisposing conditions include unusual head and neck positioning, straining and coughing during anesthesia, vascular congestion and venous engorgement of head and neck.<sup>[6]</sup>

In summary, anesthesia-related inflammatory sialadenitis is rare sequelae that may follow surgery in the elderly. Clinicians



**Figure 1:** (a) Postoperative external photography showing parotid swelling. (b) The resolution of the swelling can be appreciated after 1 week of conservative treatment

Access this article online	
<b>Quick Response Code:</b>	<b>Website:</b> www.ijjo.in
	<b>DOI:</b> 10.4103/ijjo.IJO_79_17

Department of Ophthalmic Plastic Surgery, New York Eye and Ear Infirmary, New York, NY, USA, <sup>1</sup>Ophthalmic Plastic Surgery and Ocular Oncology Services, Advanced Eye Hospital and Institute, Navi Mumbai, India

**Correspondence to:** Dr. Harsha S Reddy, Department of Ophthalmic Plastic Surgery, New York Eye and Ear Infirmary, 310 E 14<sup>th</sup> Street, New York, NY 10003, USA. E-mail: hsreddy01@gmail.com

**Manuscript received:** 30.01.17; **Revision accepted:** 25.03.17

This is an open access article distributed under the terms of the Creative Commons Attribution-NonCommercial-ShareAlike 3.0 License, which allows others to remix, tweak, and build upon the work non-commercially, as long as the author is credited and the new creations are licensed under the identical terms.

**For reprints contact:** reprints@medknow.com

**Cite this article as:** Reddy HS, Tenzel PA, Nair AG. Sialadenitis following blepharoplasty: An unusual sequelae. Indian J Ophthalmol 2017;65:316-7.

should be aware of this condition to ensure prompt referral and treatment to avoid long-term complications.

#### Financial support and sponsorship

Nil.

#### Conflicts of interest

There are no conflicts of interest.

#### References

1. Kim LJ, Klopfenstein JD, Feiz-Erfan I, Zubay GP, Spetzler RF. Postoperative acute sialadenitis after skull base surgery. *Skull Base* 2008;18:129-34.
2. Lampropoulos P, Rizos S, Marinis A. Acute suppurative parotitis: A dreadful complication in elderly surgical patients. *Surg Infect (Larchmt)* 2012;13:266-9.
3. Rowell J, Lynn AM, Filardi TZ, Celix J, Ojemann JG. Acute unilateral enlargement of the parotid gland immediately post craniotomy in a pediatric patient: A case report. *Childs Nerv Syst* 2010;26:1239-42.
4. Matsuki A, Wakayama S, Oyama T. Acute transient swelling of the salivary glands during and following endotracheal anaesthesia. *Anaesthesist* 1975;24:125-8.
5. Singha SK, Chatterjee N. Postoperative sialadenitis following retromastoid suboccipital craniectomy for posterior fossa tumor. *J Anesth* 2009;23:591-3.
6. Asghar A, Karam K, Rashid S. A case of anesthesia mumps after sacral laminectomy under general anesthesia. *Saudi J Anaesth* 2015;9:332-3.