

## Case Report

# Angiojet System Used in the Treatment of Submassive Pulmonary Embolism: A Case Report of Two Patients

Jinbo Liu <sup>1,2</sup> Tianrun Li,<sup>2,3</sup> Wei Huang,<sup>1</sup> Na Zhao,<sup>1</sup> Hongwei Zhao,<sup>1</sup>  
and Hongyu Wang <sup>1,2</sup>

<sup>1</sup>Department of Vascular Medicine, Peking University Shougang Hospital, Beijing 100144, China

<sup>2</sup>Vascular Health Research Center of Peking University Health Science Center, Beijing, China

<sup>3</sup>Department of Interventional Vascular Surgery, Peking University Third Hospital, Beijing 100191, China

Correspondence should be addressed to Hongyu Wang; [dr.hongyuwang@foxmail.com](mailto:dr.hongyuwang@foxmail.com)

Received 29 April 2022; Accepted 1 August 2022; Published 23 August 2022

Academic Editor: Hiroyuki Nakajima

Copyright © 2022 Jinbo Liu et al. This is an open access article distributed under the Creative Commons Attribution License, which permits unrestricted use, distribution, and reproduction in any medium, provided the original work is properly cited.

**Background.** Massive or submassive pulmonary embolism (PE) carries a high mortality. Percutaneous mechanical thrombectomy using the Angiojet system is accepted for the treatment of PE. Here, we reported two submassive PE cases who were treated with the Angiojet system successfully, to provide some advice for the therapy of submassive PE. **Method.** Two patients with suffocation were admitted to our hospital. One patient was accompanied by lower blood pressure (20% lower than basal blood pressure) and higher pulmonary artery pressure (89 mmHg); the other patient had larger right ventricular transverse diameter (46 mm), decreased left ventricular end diastolic anteroposterior diameter (34 mm), and higher heartbeats (107 heartbeats per minute). Pulmonary artery computed tomography angiography showed bilateral pulmonary embolism. **Result.** The Angiojet system with a high-pressure jet spray pattern (urokinase 25 wiu + sodium chloride injection 50 ml) was used. Intravascular thrombolysis by urokinase (100 wiu/day for 1 day) was done after being back in the ward. And low molecular weight heparin was used in hospitalization, and rivaroxaban was used after discharge. Both patients were treated successfully. However, the level of platelet was significantly lower in one patient after Angiojet system usage and recovered to the preoperative level the next day. Another patient suffered from bradyarrhythmias during the usage of Angiojet, and bradyarrhythmias disappeared when the Angiojet system stopped. Pulmonary embolism was cured after 3 months in both patients. **Conclusion.** Angiojet could be a simple, safe, and well-tolerated treatment for massive or submassive PE. And hematocrit, platelet, kidney function, and heart rhythm should be monitored during perioperation.

## 1. Introduction

Pulmonary embolism (PE) especially massive or submassive PE carries a high mortality, associated with haemodynamic instability [1]. Thrombolytic therapy and surgical embolectomy are accepted for the treatment of massive PE [2]. However, these therapies might be accompanied by complications such as bleeding and surgical complications. So, percutaneous mechanical thrombectomy (PMT) using a variety of devices has been developed [3]. Akam-Venkata et al. [4] showed that catheter-directed therapy was an emerging alternative therapy for submassive and massive PE in children. And catheter-directed

mechanical thrombectomy as the primary treatment for massive PE and submassive PE had a high rate of technical and clinical success in a high-risk patient population [5]. The Angiojet system is a device originally designed for thrombectomy in peripheral vessels or saphenous vein grafts [6]. And the Angiojet system showed an increasing use in emergency and election patients such as deep venous thrombosis [7]. A recent study showed that percutaneous rheolytic thrombectomy using the Angiojet system might be a valid treatment option for patients with massive or submassive pulmonary embolism with rapid and significant haemodynamic improvement and encouraging results at early and long-term follow-up [8].

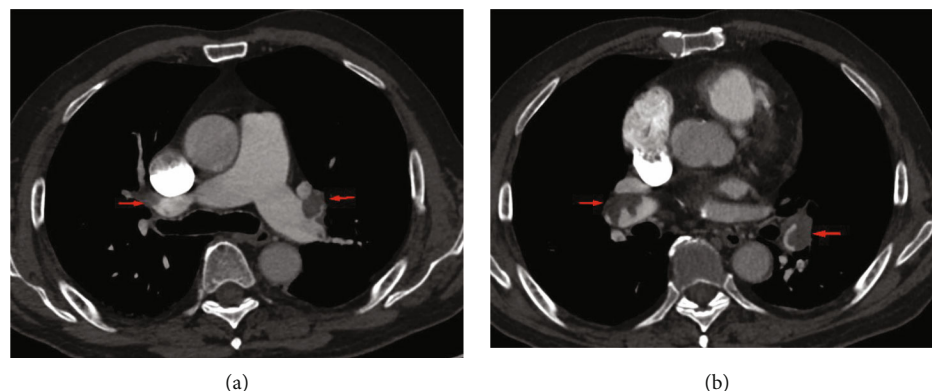


FIGURE 1: Computed tomography angiography (CTA) showed pulmonary embolism (yellow arrow) in the first patient (a, b).

Here, we reported two submassive PE cases who were treated with the Angiojet system successfully, to provide some advice for the therapy of submassive PE.

## 2. Case Presentation

A patient (man, 87 years old) visited our hospital with suffocation for 3 days on August 31, 2019. This patient had a history of hypertension treated with valsartan amlodipine compound, with blood pressure 150/70 mmHg and 60 heartbeats per minute in peacetime. In addition, this patient had a history of lower extremity varicose veins without any therapy. We did some laboratory tests and examinations for this patient immediately after admission to the hospital. Whole blood count analysis revealed a white blood cell count of  $9.1 \times 10^9/l$  (reference range  $3.5-9.5 \times 10^9/l$ ), haemoglobin level of 134 g/l (reference range 115-150 g/l), hematocrit level of 37.3% (reference range 40-50%), and a platelet count of  $154 \times 10^9/l$  (reference range  $125-350 \times 10^9/l$ ). The results of NT-proBNP and creatine were 10671 pg/ml (reference range 0-1800 pg/ml) and  $125.7 \mu\text{mol/l}$  (reference range 20-98  $\mu\text{mol/l}$ ), respectively. The level of troponin was normal. Further examination showed that autoantibodies were normal. The blood pressure was 120/80 mmHg, with 80 heartbeats per minute when admitted to the hospital. No thrombus was found in the lower extremity venous ultrasound examination. And pulmonary artery computed tomography angiography (CTA) showed bilateral pulmonary embolism (Figures 1(a) and 1(b)). Electrocardiogram showed right bundle branch block, and echocardiogram showed larger right ventricular transverse diameter (43 mm), decreased left ventricular end diastolic anteroposterior diameter (43 mm), and higher pulmonary artery pressure (89 mmHg). According to the clinical manifestations, blood pressure (20% lower than basal blood pressure), CTA, NT-proBNP, and echocardiogram, this patient was diagnosed with submassive pulmonary embolism. Pulmonary angiography was done on August 31, 2019, and the result confirmed pulmonary embolism. In addition, percutaneous mechanical pulmonary thrombectomy was done using the Angiojet system. The injection pattern by urokinase (urokinase 25 wiu + sodium chloride injection 50 ml) was used. And the main left pulmonary artery was treated

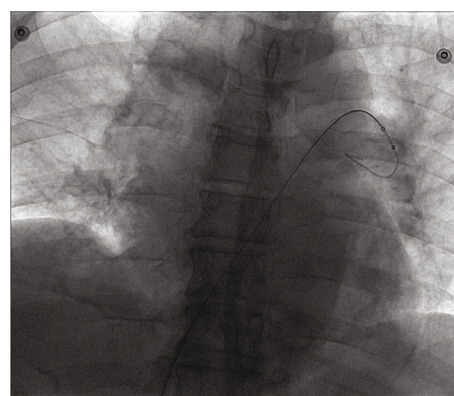


FIGURE 2: Angiographic imaging of Angiojet system in the first patient.

with the Angiojet system for 20 s, and the main right pulmonary artery was treated with the Angiojet system for 15 s (Figure 2). However, this treatment was finished because of bradyarrhythmia, and bradyarrhythmia disappeared after catheter withdrawal. And we placed the catheter in the inferior vena cava; intravascular thrombolysis by urokinase (100 wiu/day, 1 day) was done after being back in the ward. And low molecular weight heparin was used in hospitalization, and rivaroxaban was used after discharge. In addition, whole blood count analysis revealed a white blood cell count of  $11.5 \times 10^9/l$  (reference range  $3.5-9.5 \times 10^9/l$ ), haemoglobin level of 140 g/l (reference range 115-150 g/l), hematocrit level of 41% (reference range 40-50%), and a platelet count of  $161 \times 10^9/l$  (reference range  $125-350 \times 10^9/l$ ) on September 1. The results of NT-proBNP and creatine were 801 pg/ml (reference range 0-1800 pg/ml) and  $110 \mu\text{mol/l}$  (reference range 20-98  $\mu\text{mol/l}$ ) on September 9, respectively. And echocardiogram showed decreased right ventricular transverse diameter (42 mm), normal left ventricular end diastolic anteroposterior diameter (52 mm), and higher pulmonary artery pressure (72 mmHg) on September 11.

Another patient (man, 67 years old) visited our hospital with chest tightness after activity for 1 day on September 10, 2019. This patient had a history of left lower limb trauma 2 months ago without history of hypertension, diabetes mellitus, and smoking. We did some laboratory tests and

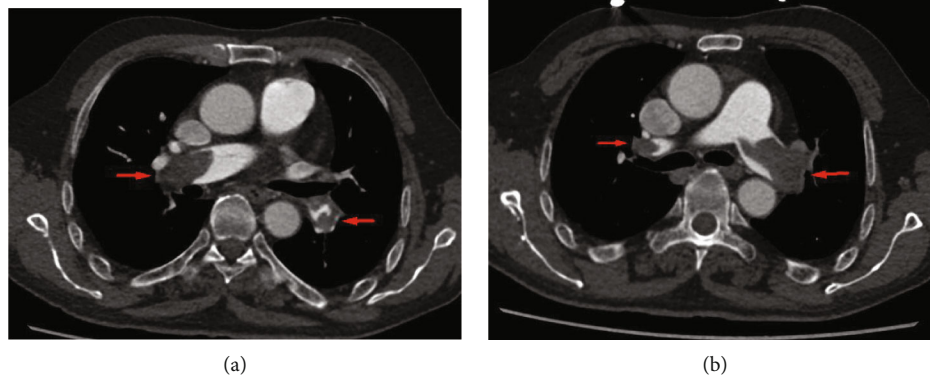


FIGURE 3: Computed tomography angiography (CTA) showed pulmonary embolism (yellow arrow) in the second patient (a, b).

examinations for this patient immediately after admission to the hospital. Whole blood count analysis revealed a white blood cell count of  $7.0 \times 10^9/l$  (reference range  $3.5-9.5 \times 10^9/l$ ), haemoglobin level of 138 g/l (reference range 115-150 g/l), hematocrit level of 39.1% (reference range 40-50%), and a platelet count of  $103 \times 10^9/l$  (reference range  $125-350 \times 10^9/l$ ). The results of NT-proBNP and creatine were 5305 pg/ml (reference range 0-1800 pg/ml) and 76.1  $\mu\text{mol/l}$  (reference range 20-98  $\mu\text{mol/l}$ ), respectively. The level of troponin was normal. Further examination showed that autoantibodies were normal. The blood pressure was 110/70 mmHg, with 107 heartbeats per minute when admitted to the hospital. An old thrombus was found in the left lower extremity venous ultrasound examination. And pulmonary artery computed tomography angiography (CTA) showed bilateral pulmonary embolism (Figures 3(a) and 3(b)). Electrocardiogram showed  $S_1Q_3T_3$  sign, and echocardiogram showed larger right ventricular transverse diameter (46 mm), decreased left ventricular end diastolic anteroposterior diameter (34 mm), and higher pulmonary artery pressure (44 mmHg). According to the clinical manifestations, CTA, NT-proBNP, and echocardiogram, this patient was diagnosed with submassive pulmonary embolism. Pulmonary angiography was done on September 10, 2019, and the result confirmed pulmonary embolism. In addition, percutaneous mechanical pulmonary thrombectomy was done using the Angiojet system (Figure 4). The injection pattern by urokinase (urokinase 25 wiu + sodium chloride injection 50 ml) was used. And the main left pulmonary artery was treated by the Angiojet system for 20 s, and the main right pulmonary artery was treated by the Angiojet system for 20 s. Thrombus aspiration was performed in both pulmonary arteries using a catheter by 50 ml syringe, and a massive thrombus was extracted (Figures 5(a) and 5(b)). And we placed the catheter in the inferior vena cava. Intravascular thrombolysis by urokinase (100 wiu/day, 1 day) was done after being back in the ward. And low molecular weight heparin was used in hospitalization, and rivaroxaban was used after discharge. In addition, whole blood count analysis revealed a white blood cell count of  $6.6 \times 10^9/l$  (reference range  $3.5-9.5 \times 10^9/l$ ), haemoglobin level of 134 g/l (reference range 115-150 g/l), hematocrit level of 37.8% (ref-

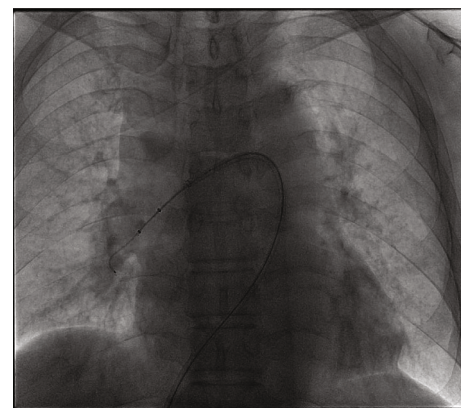


FIGURE 4: Angiographic imaging of Angiojet system in the second patient.

reference range 40-50%), and a platelet count of  $74 \times 10^9/l$  (reference range  $125-350 \times 10^9/l$ ) on September 11. And the level of platelet count was  $125 \times 10^9/l$  (reference range  $125-350 \times 10^9/l$ ) on September 12. The results of NT-proBNP and creatine were 1391 pg/ml (reference range 0-1800 pg/ml) and 54.1  $\mu\text{mol/l}$  (reference range 20-98  $\mu\text{mol/l}$ ) on September 12 and 22, respectively. And echocardiogram showed decreased right ventricular transverse diameter (29 mm), normal left ventricular end diastolic anteroposterior diameter (51 mm), and normal pulmonary artery pressure (26 mmHg) on September 26. The clinical characteristics of these two patients are shown in Table 1.

In addition, pulmonary artery computed tomography angiography showed pulmonary embolism disappearance in the second patient after 3 months (Figure 6).

### 3. Intervention Process

The patient was supine, and the conventional bilateral inguinal region skin was disinfected by sterile drapes. 1% lidocaine anesthesia was done in the right femoral vein puncture point, the right femoral vein puncture, implanted with a 5 f sheath pipe. By going through the sheath pipe, the pigtail catheter was placed at the level of L5 by an ultrasound guide wire. The patency of inferior vena cava and



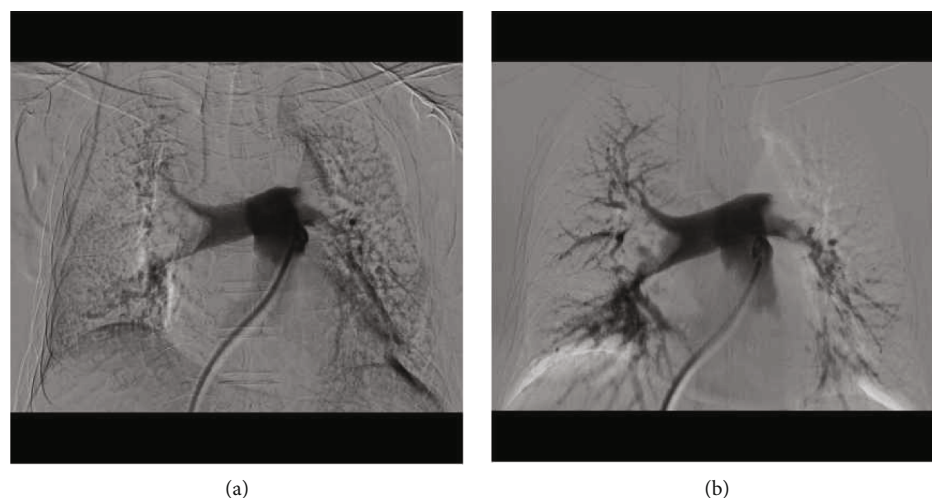

FIGURE 5: Angiographic imaging before (a) and after (b) Angiojet system therapy in the second patient.

TABLE 1: Clinical characteristics in these two patients.

Characteristics	Patient 1		Patient 2	
	Pre-Angiojet therapy	Post-Angiojet therapy	Pre-Angiojet therapy	Post-Angiojet therapy
White blood cell ( $\times 10^9/l$ )	9.1	11.5	7	6.6
Haemoglobin (g/l)	134	140	138	134
Hematocrit (%)	37.3	41.1	39.1	37.8
Platelet ( $10^9/l$ )	154	161	103	74
NT-proBNP (pg/ml)	10671	801	5305	1391
Creatine ( $\mu\text{mol/l}$ )	125.7	110	76.1	54.1
Blood pressure (mmHg)	120/80	140/80	110/70	126/70
Heart rate (per minute)	80	65	107	74
Right ventricular transverse diameter (mm)	43	42	46	29
Left ventricular end diastolic anteroposterior diameter (mm)	43	52	34	51
Pulmonary artery pressure (mmHg)	89	72	44	26

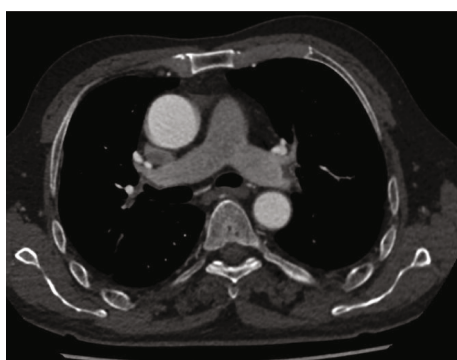


FIGURE 6: Computed tomography angiography (CTA) showed pulmonary embolism disappearance in the second patient.

bilateral renal vein open position were confirmed by angiography. The tail catheter and sheath tube were removed, and the ultrasmooth guide wire was retained. The special long sheath for the filter was replaced using an ultrasmooth guide wire, and the inferior vena cava filter (DENALI) was

implanted in the lower segment of the renal vein and the vertical segment of the inferior vena cava. The long sheath of the filter was replaced by a soft sheath tube with a hard guide wire, and the sheath tube was placed near the heart position of the inferior vena cava. Guided by the sheath tube and ultrasmooth guide wire, the pigtail catheter was placed in the main pulmonary artery, and pulmonary angiography was performed to confirm pulmonary embolism. The stiff guide wire through the pigtail catheter at the main left pulmonary artery was placed, the pigtail catheter was removed, and the sheath catheter was placed through the guide wire at the main pulmonary artery. The Angiojet system was placed in the main pulmonary artery through the sheath tube, and the injection device was used for thrombolysis treatment. And then, the Angiojet system was removed, and the catheter was placed into the main pulmonary artery through a sheath tube, with a 50 ml syringe at the end of the catheter for thrombus aspiration. Finally, the pigtail catheter was placed through the sheath at the main pulmonary artery for reexamination. The sheath was withdrawn to the inferior vena cava L5 level under the support from the thread. And

we placed the catheter in the inferior vena cava. Intravascular thrombolysis by urokinase (100 wiu/day, 1 day) was done after being back in the ward. After 24 hours, the catheter and sheath tube were pulled out, and local pressure was applied for 10 minutes. Then, the bandages were bandaged. The bandage was removed, and the patient could move out of bed after 24 hours.

#### 4. Discussion

Pulmonary embolism (PE) especially massive or submassive PE associated with haemodynamic instability was a threatening factor for human life. Early aggressive treatment restoring patency of occluded pulmonary arteries was the principal factor affecting mortality in massive PE [9]. According to the guidelines of the European Society of Cardiology, shock or systemic hypotension is an accepted indication for urgent thrombolysis in patients with massive PE, and surgical or endovascular thrombectomy can be an option in selected cases [10].

The Angiojet system is a device originally designed for thrombectomy in peripheral vessels or saphenous vein grafts. The Angiojet system incorporates mechanical fragmentation, pharmacologic lysis, and rheolytic aspiration of clots. And many studies confirmed the successful usage of the Angiojet system in deep venous thrombosis [11].

However, there was little research about the usage of the Angiojet system in PE, and most research was case reports of small samples, and this might be caused by the characteristics of massive or submassive PE. A previous study showed that Angiojet system technical success was obtained in 92.2% of PE patients, with a significant improvement in obstruction, perfusion, and Miller indexes [12]. The Angiojet system procedure might be safely performed in PE patients with cardiogenic shock [13]. Another study about the combined therapy including the catheter-directed thrombolysis method using adjunctive power-pulse spray technique using the Angiojet system showed that there were no major or minor adverse events and no procedure-related complications in treating massive and submassive acute PE. And this study offered several potential advantages compared with current options, allowing safer and faster thrombus resolution [14]. Guo et al. showed that the Angiojet system combined with catheter fragmentation was successfully used in the treatment of massive PE [15]. There were some studies about massive PE patients with thrombolytic therapy contraindicated. Zuin et al. reported a patient with acute PE, heparin-induced thrombocytopenia type II, and recent ischemic stroke, and this patient was successfully treated with rheolytic thrombectomy by the Angiojet system, suggesting the usefulness of the Angiojet system in treating acute PE in clinically difficult scenarios, especially when thrombolytic therapy is contraindicated [16]. Vecchio et al. reported a patient who developed acute intermediate-risk PE, with right ventricular dysfunction and major myocardial necrosis, and this patient was successfully treated with the Angiojet system [17]. These studies confirmed at early and long-term follow-up the effectiveness and safety of rheolytic thrombectomy using the Angiojet system for PE [18, 19].

However, there might be some complications with the usage of the Angiojet system. First, Angiojet will cause not only clot dissipation, with its high-pressure jet spray, but also some destruction of blood cells, so hematuria was a corollary and “self-limited” side effect on patients treated with Angiojet [20]. Second, a recent study showed that procedure-related anemia was one significant minor complication [21]. Third, another study showed that bradyarrhythmia might appear during the usage of the Angiojet system. This might be related to the effects of the hydrodynamic jets on stretch-activated receptors present on the vascular endothelium, and pretreatment with gadolinium or streptomycin might prevent activation of these receptors [22]. Fourth, Angiojet usage was an independent risk factor for acute kidney injury, and this might be related to haemolysis from the device [23]. And a recent study found that Angiojet system usage would raise the risk of postoperative acute kidney injury, especially in patients with a history of major surgery within 3 months of endovascular intervention, and hematocrit drop > 14% might indicate upcoming acute kidney injury [24]. In addition, pulmonary artery CTA and interventional therapy required the participation of contrast material, which might cause renal insufficiency, especially in the elderly. And troponin values would be expected to increase in a patient with impaired renal function. However, we did not measure postoperative troponin levels in the present study, and this process should be perfected in future cases. In the present study, our results showed that there was no difference in the level of hematocrit, haemoglobin, and kidney function before and after Angiojet system usage. However, the level of platelet was significantly lower in one patient after Angiojet system usage, and the level of platelet recovered to the preoperative level the next day. We thought this might be related to high-pressure jet spray and mechanical damage of the Angiojet device, and this complication was first reported so far. In addition, one patient suffered from bradyarrhythmias during the usage of Angiojet, and bradyarrhythmias disappeared when the Angiojet system stopped, similar to a previous study.

In conclusion, Angiojet could be a simple, safe, and well-tolerated treatment for massive or submassive PE. And hematocrit, platelet, kidney function, and heart rhythm should be monitored during perioperation.

#### Abbreviations

PE: Pulmonary embolism  
PMT: Percutaneous mechanical thrombectomy.

#### Consent

Informed consent has been obtained from the patient for publication of the case report.

#### Conflicts of Interest

No conflicts of interest, financial or otherwise, are declared by the authors.

## Authors' Contributions

Jinbo Liua and Tianrun Li are equal contributors.

## Acknowledgments

This work was supported by the Capital's Funds for Health Improvement and Research (2020-2-6042), Key Medical Disciplines/Schools of Shijingshan District (Vascular Medicine), and Key clinical projects in Peking University Shougang Hospital (2019-Yuan-LC-01; SGYYZ202105).

## References

- [1] W. Kasper, S. Konstantinides, A. Geibel et al., "Management strategies and determinants of outcome in acute major pulmonary embolism: results of a multicenter registry," *Journal of the American College of Cardiology*, vol. 30, no. 5, pp. 1165–1171, 1997.
- [2] N. Kucher, E. Rossi, M. De Rosa, and S. Z. Goldhaber, "Massive pulmonary embolism," *Circulation*, vol. 113, no. 4, pp. 577–582, 2006.
- [3] J. A. Suarez, G. E. Meyerrose, S. Phisitkul et al., "Review of catheter thrombectomy devices," *Cardiology*, vol. 102, no. 1, pp. 11–15, 2004.
- [4] J. Akam-Venkata, T. J. Forbes, T. Schreiber et al., "Catheter-directed therapy for acute pulmonary embolism in children," *Cardiology in the Young*, vol. 21, pp. 1–7, 2018.
- [5] N. Nassiri, A. Jain, D. McPhee et al., "Massive and submassive pulmonary embolism: experience with an algorithm for catheter-directed mechanical thrombectomy," *Annals of Vascular Surgery*, vol. 26, no. 1, pp. 18–24, 2012.
- [6] P. Stähr, H. J. Rupprecht, T. Voigtländer et al., "A new thrombectomy catheter device (AngioJet) for the disruption of thrombi: an in vitro study," *Catheterization and Cardiovascular Interventions*, vol. 47, no. 3, pp. 381–389, 1999.
- [7] A. M. Ierardi, G. Xhepa, G. Piffaretti et al., "Clinical experience with Angiojet: a comprehensive review," *International Angiology*, vol. 34, no. 6, pp. 1–14, 2015.
- [8] S. Vecchio, G. Vittori, T. Chechi et al., "Percutaneous rheolytic thrombectomy with AngioJet for pulmonary embolism: methods and results in the experience of a high-volume center," *G Ital Cardiol (Rome)*, vol. 9, no. 5, pp. 355–363, 2008.
- [9] A. T. Cohen, G. Agnelli, F. A. Anderson et al., "Venous thromboembolism (VTE) in Europe. The number of VTE events and associated morbidity and mortality," *Thrombosis and Haemostasis*, vol. 98, no. 4, pp. 756–764, 2007.
- [10] S. V. Konstantinides, A. Torbicki, G. Agnelli et al., "2014 ESC guidelines on the diagnosis and management of acute pulmonary embolism," *European Heart Journal*, vol. 35, no. 43, pp. 3033–3080, 2014.
- [11] R. J. Weinberg, T. Okada, A. Chen, W. Kim, C. Chen, and P. H. Lin, "Comparison of ASPIRE mechanical thrombectomy versus AngioJet thrombectomy system in a porcine iliac vein thrombosis model," *Annals of Vascular Surgery*, vol. 42, pp. 254–262, 2017.
- [12] T. Chechi, S. Vecchio, G. Spaziani et al., "Rheolytic thrombectomy in patients with massive and submassive acute pulmonary embolism," *Catheterization and Cardiovascular Interventions*, vol. 73, no. 4, pp. 506–513, 2009.
- [13] R. F. Bonvini, M. Roffi, H. Bounameaux et al., "AngioJet rheolytic thrombectomy in patients presenting with high-risk pulmonary embolism and cardiogenic shock: a feasibility pilot study," *Euro Intervention*, vol. 8, no. 12, pp. 1419–1427, 2013.
- [14] L. Villalba, T. Nguyen, R. L. Feitosa Jr., P. Gunanayagam, N. Anning, and K. Dwight, "Single-session catheter-directed lysis using adjunctive power-pulse spray with AngioJet for the treatment of acute massive and submassive pulmonary embolism," *Journal of Vascular Surgery*, vol. 70, no. 6, pp. 1920–1926, 2019.
- [15] J. Guo, Y. Gu, L. Guo, Z. Tong, and X. Gao, "Angiojet rheolytic thrombectomy combined with catheter fragmentation in a patient presenting with massive pulmonary embolism and cardiogenic shock," *Technology and Health Care*, vol. 25, no. 1, pp. 157–161, 2017.
- [16] M. Zuin, G. Rigatelli, and L. Roncon, "Rheolytic thrombectomy in patient with acute pulmonary embolism, heparin-induced thrombocytopenia and recent stroke. When percutaneous treatment is the only therapeutic alternative," *Perfusion*, vol. 31, no. 8, pp. 703–705, 2016.
- [17] S. Vecchio, E. Varani, A. Nuzzo et al., "Percutaneous rheolytic thrombectomy with the AngioJet system for the treatment of intermediate-risk acute pulmonary embolism: a case report and an appraisal of contemporary indications and technique," *Minerva Cardioangiologica*, vol. 62, no. 2, pp. 221–228, 2014.
- [18] M. Margheri, G. Vittori, S. Vecchio et al., "Early and long-term clinical results of AngioJet rheolytic thrombectomy in patients with acute pulmonary embolism," *The American Journal of Cardiology*, vol. 101, no. 2, pp. 252–258, 2008.
- [19] P. Latacz, M. Simka, P. Brzegowy et al., "Treatment of high- and intermediate-risk pulmonary embolism using the AngioJet percutaneous mechanical thrombectomy system in patients with contraindications for thrombolytic treatment - a pilot study," *Wideochir Inne Tech Maloinwazyjne*, vol. 13, no. 2, pp. 233–242, 2018.
- [20] K. Ouriel, "Endovascular techniques in the treatment of acute limb ischemia: thrombolytic agents, trials, and percutaneous mechanical thrombectomy techniques," *Seminars in Vascular Surgery*, vol. 16, no. 4, pp. 270–279, 2003.
- [21] S. Das, N. Das, H. Serota, and S. Vissa, "A retrospective review of patients with massive and submassive pulmonary embolism treated with AngioJet rheolytic thrombectomy with decreased complications due to changes in thrombolytic use and procedural modifications," *Vascular*, vol. 26, no. 2, pp. 163–168, 2018.
- [22] D. Dwarka, S. A. Schwartz, S. H. Smyth, and M. J. O'Brien, "Bradyarrhythmias during use of the AngioJet system," *Journal of Vascular and Interventional Radiology*, vol. 17, no. 10, pp. 1693–1695, 2006.
- [23] G. A. Escobar, D. Burks, M. R. Abate et al., "Risk of acute kidney injury after percutaneous pharmacomechanical thrombectomy using AngioJet in venous and arterial thrombosis," *Annals of Vascular Surgery*, vol. 42, pp. 238–245, 2017.
- [24] Y. Shen, X. Wang, S. S. Jin, R. L. Zhang, W. J. Zhao, and G. Chen, "Increased risk of acute kidney injury with percutaneous mechanical thrombectomy using AngioJet compared with catheter-directed thrombolysis," *Journal of Vascular Surgery. Venous and Lymphatic Disorders*, vol. 7, no. 1, pp. 29–37, 2019.