

Campomelic dysplasia with 10 pairs of ribs in a preterm neonate: A case report

Laxman Basani, Roja Aepala, Naresh Macha¹

Departments of Neonatology and ¹Radiology, Dolphin Children's Hospital, Hyderabad, Telangana, India

Correspondence: Dr. Laxman Basani, Dolphin Children's Hospital, 17-87, Road No. 1, Kamalanagar, Chaitanyapuri, Hyderabad - 500 060, Telangana, India. E-mail: laxmanbasani@yahoo.co.in

Abstract

Campomelic dysplasia (CD) is a rare form of skeletal dysplasia (incidence 1:200,000 births) which is associated with characteristic phenotypes including bowing of the limbs, a narrow thoracic cage, 11 pairs of ribs, hypoplastic scapulae, macrocephaly, flattened supraorbital ridges and nasal bridge, cleft palate, and micrognathia. In addition to the skeletal abnormalities, hydrocephalus, hydronephrosis, and congenital heart disease have been reported. We describe a preterm neonate who presented with respiratory failure and clinical features of CD. Our case had only 10 pairs of ribs, and to the best of our knowledge this is the first case report of CD with 10 pairs of ribs.

Key words: Campomelic dysplasia; neonate; skeletal dysplasia; 10 pairs of ribs

Introduction

Campomelic dysplasia (CD) is a rare autosomal dominant short-limbed dwarfism with skeletal and developmental abnormalities.^[1,2] It is a rare form of skeletal dysplasia (incidence 1 in 40,000–200,000 live births) caused by dysregulation of SOX9 expression during chondrogenesis.^[3] First described in 1971 by Maroteaux *et al.*, CD is a haploinsufficiency disorder with characteristic features of bowing and shortening of the long bones with pretibial skin dimpling, hypoplastic scapulae, 11 pairs of ribs, a narrow thorax, and bilateral clubfeet.^[4] In addition to skeletal abnormalities, hydrocephalus, hydronephrosis, and congenital heart disease (ventriculoseptal defect, atrioseptal defect, aortic stenosis, and/or tetralogy of Fallot) have been reported.^[5] In about 10% of cases, bending of the long bones is absent, referred to as acampomelic CD.^[6] Patients severely affected with CD usually succumb to respiratory distress in the neonatal period due to small chest, pulmonary hypoplasia, and airway anomalies.

Case Report

A preterm female neonate weighing 2420 g was born to a 23-year-old G2P1L1 mother at 36 weeks of gestation by emergency cesarean section (indication: preterm labor, previous cesarean birth, fetal distress). There was no history of maternal fever or rupture of membranes. She had limited prenatal care, and an antenatal scan done at 19 weeks of gestation was normal. Both parents had normal phenotype, and there was no history of consanguinity. The first sibling was a 3-year-old male child whose growth and development were appropriate for age. Liquor was clear. The baby required resuscitation. Apgar scores were 3, 5, and 8 at 1, 5, and 10 min of age, respectively. The baby developed respiratory distress soon after birth and was referred to our unit.

The baby was admitted at 4 h of age with severe respiratory distress. Arterial blood gas on admission showed severe

This is an open access journal, and articles are distributed under the terms of the Creative Commons Attribution-NonCommercial-ShareAlike 4.0 License, which allows others to remix, tweak, and build upon the work non-commercially, as long as appropriate credit is given and the new creations are licensed under the identical terms.

For reprints contact: reprints@medknow.com

Cite this article as: Basani L, Aepala R, Macha N. Campomelic dysplasia with 10 pairs of ribs in a preterm neonate: A case report. Indian J Radiol Imaging 2018;28:456-9.

Access this article online

Quick Response Code:



Website:
www.ijri.org

DOI:
10.4103/ijri.IJRI_173_18

mixed acidosis with pH of 6.95, PCO_2 101 mmHg, PaO_2 52 mmHg, HCO_3 12.9 mmol/L, and BE of -15.1 mmol/L.

On examination, the baby was dull, with a temperature of 35.6°C , heart rate 158/min, capillary refill 4–5 s, respiratory rate 78/min, subcostal retractions, audible grunt, and SpO_2 of 81%. The baby's anthropometric measurements were as follows: weight 2420 g (37 percentile), length 41 cm (2 percentile), and head circumference 37 cm (100 percentile). The baby had flat facies, macrocephaly, large anterior fontanel (measured 5×4.5 cm), depressed nasal bridge, micrognathia, low set ears, short neck, small chest, short limbs with bowing [Figure 1], and bilateral clubfeet [Figure 2].

The baby was intubated and commenced on conventional ventilation. Infantogram showed small thoracic cage, slender thin ribs, 10 pairs of ribs, hypoplastic scapulae, bowed tibiae, femora and ulnae, short fibulae, short and flat vertebrae, and small iliac wings [Figures 3 and 4]. The clinical features and radiological findings were consistent with the diagnosis of CD.

Laboratory investigations showed hemoglobin of 15.4 g/dL, leucocytosis (white blood cell: $23,800/\text{mm}^3$), platelets 2.14 lakhs/ mm^3 , and C-reactive protein of 3.8 mg/L. Blood culture was taken, and antibiotics (cefotaxime and amikacin) were started. Head ultrasound showed dilatation of both lateral ventricles. Ultrasound of the abdomen showed Mullerian structures. The baby had subtle seizures at 6 h of life. The baby had normal female karyotype with 46XX chromosomes.

The parents were counseled regarding further evaluation (mutation analysis, geneticist consultation). In view of poor prognosis, the parents deferred further care and took the baby from hospital against medical advice.

Discussion

Osteochondrodysplasias or skeletal dysplasias are a heterogeneous group of more than 350 distinct disorders of skeletogenesis. Campomelic dysplasia (from Greek "campto," to bend and "melos," limb), also known as camptomelic syndrome, or campomelic dwarfism is a rare life-threatening genetic disorder (incidence of 1 in 40,000–200,000 live births) caused by mutations in or near the *SOX9* gene (chromosome 17). *SOX9* is important for the development of the skeleton and reproductive system.^[7,8] Mutations in *SOX9* gene cause skeletal deformities, male-to-female sex reversals, abnormal hair growth, fibrosis, and cancer.^[3]

Shortness of the calf and hamstring musculature causes bowing of the tibia and femora and characteristic skin dimples over the curved bones, especially the lower limbs. They usually have short legs, dislocated hips,

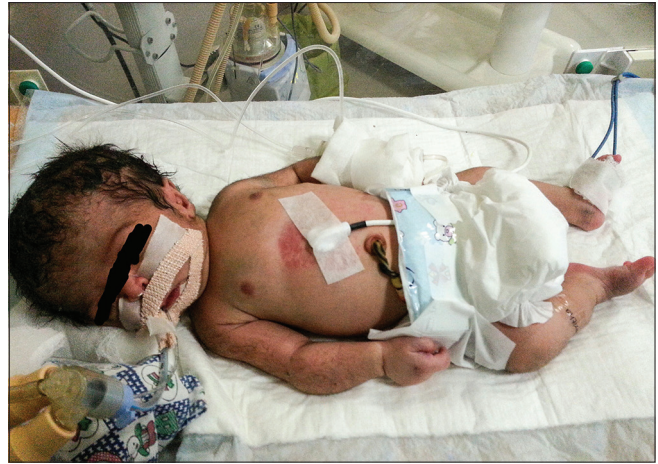

Figure 1: Baby with short and bent limbs, small chest, short neck, and macrocephaly

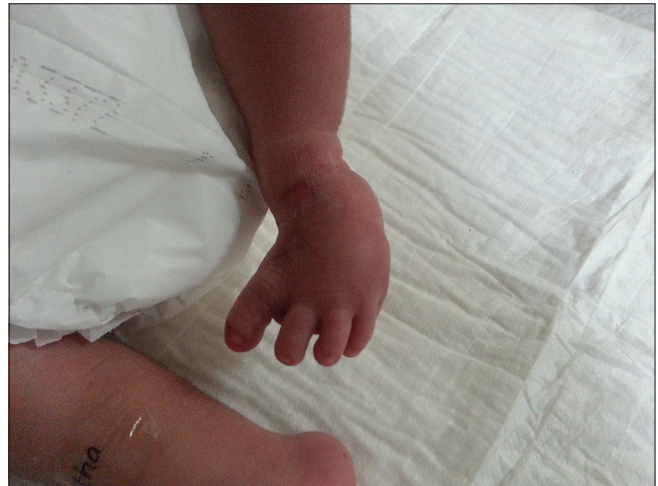

Figure 2: Clubfoot of left lower limb

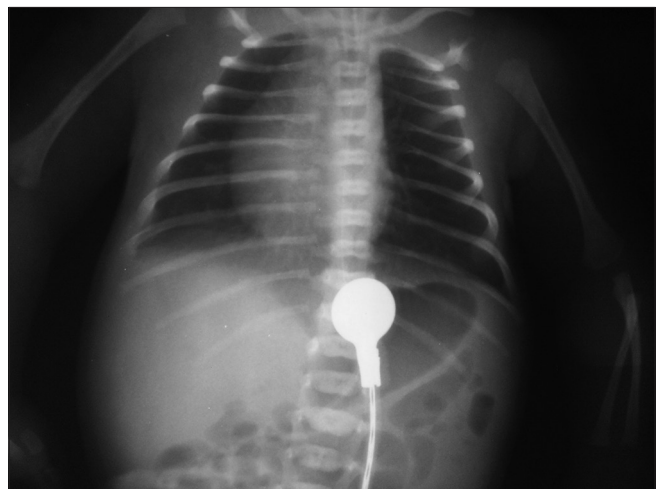


Figure 3: Chest X-ray showing 10 pairs of ribs, thin and slender ribs, hypoplastic scapulae, and short vertebrae

underdeveloped shoulder blades, 11 pairs of ribs instead of 12, bone abnormalities in the neck and clubfeet, small chin,

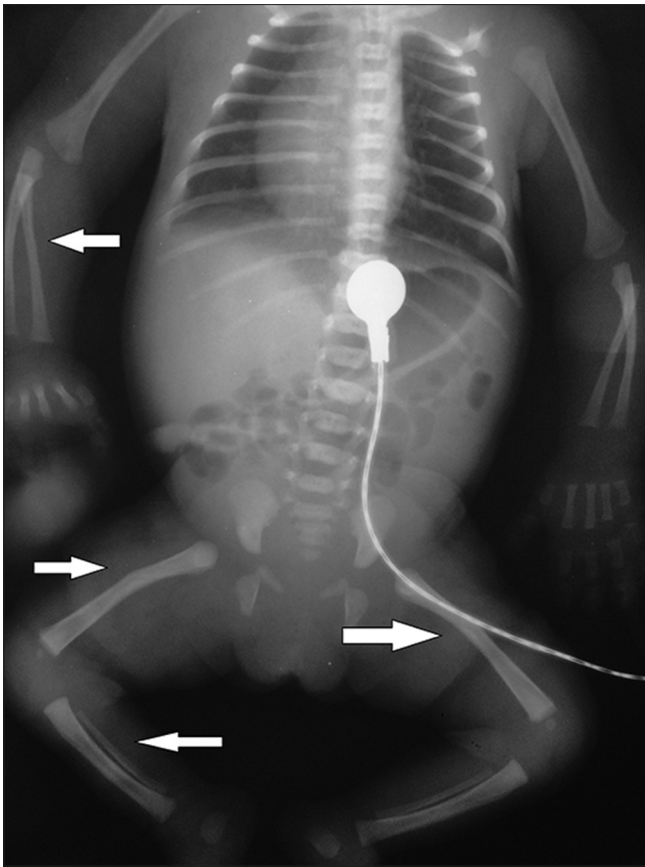


Figure 4: Infantogram showing splayed pubic symphysis, small iliac bones, short and hypoplastic vertebrae, bowing of tibiae, femora, ulnae, and short fibulae. Arrows indicate bent ulna, femora and tibia

prominent eyes, macrocephaly, and flat face. In about 10% of cases, the bending of the long bones is absent, referred to as acampomelic CD. Our case had only 10 pairs of ribs instead of 11 pairs as reported in cases of CD.

Differential diagnoses of CD include thanatophoric dysplasia, osteogenesis imperfecta type II, hypophosphatasia, achondrogenesis, short rib syndromes, atelosteogenesis, mesomelic dysplasia (Reinhart variety), kyphomelic dysplasia (KD), Stüve-Wiedemann osteochondrodysplasia, and unclassifiable varieties of congenital bowing of the long bones. [Table 1].

Thanatophoric dysplasia is diagnosed prenatally by the presence of bowed femora, frontal bossing, cloverleaf skull, short fingers, small chest, and polyhydramnios. Limb shortening would be obvious from as early as 13 weeks' gestation, and our case had antenatal scan at 19 weeks which was normal. Features of thanatophoric dysplasia like cloverleaf skull, frontal bossing, and short fingers were not seen in our case.

Osteogenesis imperfecta type II presents with neonatal fractures, broad crumpled femora, and beaded ribs. Our case did not have beaded ribs or fractures and femora were normal.

Prenatal lethal form of hypophosphatasia is characterized by hypomineralization and osteochondral spurs without clinical features of CD. Atelosteogenesis is a lethal chondrodysplasia characterized by incomplete ossification of the vertebral bodies with coronal clefts of the lumbar vertebrae and hypoplasia of the upper thoracic vertebral bodies, club shape of the humerus and femur, and lack of ossification of single phalanges and metacarpals in most patients.

KD is bent bone skeletal dysplasia that has severe localized and symmetric bowing of the femora without other significant abnormalities. Unlike CD, KD involves principally the femora with sparing of the remainder of the skeleton.

Stüve-Wiedemann osteochondrodysplasia is a rare bent bone dysplasia characterized by bowed long bones, joint restrictions, dysautonomia, respiratory, and feeding difficulties leading to death in the neonatal period and infancy.

Most cases of CD result from new mutations in or near the *SOX9* gene and occur in people with no history of the disorder in their family. Genetically male (XY) individuals appear phenotypically female because defective *SOX9* gene is unable to fulfill its role of sex differentiation (testis development). Approximately 75% of the affected individuals with a male karyotype (46XY) have ambiguous genitalia or normal female genitalia, which is known as sex reversal.^[9] Our case had female genitalia and karyotype showed 46 XX chromosomes.

Most cases succumb during neonatal period due to respiratory failure, and around 5% cases survive beyond infancy. Respiratory distress results from the small size of the chest, pulmonary hypoplasia, and laryngotracheobronchomalacia which are usually fatal in the neonatal period. Those who survive into early infancy frequently have feeding problems and difficulty in breathing.

CD can be diagnosed antenatally through chorionic villus sampling or amniocentesis, if the gene defect is identified in the previously affected individual.^[10] In females with CD who have a Y chromosome, the gonads do not develop into normal ovaries and should be surgically removed because of the risk of malignancy.

Conclusion

CD is a rare form of lethal skeletal dysplasia. We report a preterm neonate who presented with respiratory distress and characteristic clinical and radiological features of CD. To the best of our knowledge, this is the first case report of CD with 10 pairs of ribs.

Table 1: Differential diagnosis of skeletal dysplasias

Disorder	Skeletal manifestations	Other possible observations	Prognosis	Inheritance
Achondroplasia ^[5]	Rhizomelic shortening of the limbs; frontal bossing; depressed nasal bridge	Trident hand; polyhydramnios	Intelligence and lifespan are normal; possible obstructive apnea in the infantile period.	AD: mutations in the FGFR3 gene
Atelosteogenesis ^[10]	Deficient ossification of humerus, femur, thoracic spine and phalanges, micromelic dwarfism with incurvated legs, club feet, dislocation of the elbows, club shape of humerus and femur	Cleft palate		AR: mutations in the DTDST gene, gene encoding filamin B (FLNB)
Campomelic dysplasia	Anterior bowing of the long bones, particularly lower limbs; bell-shaped/narrow chest; scoliosis	IUGR; hydrocephalus; mild hydramnios; low set/malformed ears; ambiguous genitalia; micrognathia	Neonatal or infant death due to respiratory complications in almost all cases	AD: mutations in the SOX 9 gene
Diastrophic dysplasia	Lateral projection of thumbs; normal HC; kyphoscoliosis; joint contractures; disproportionate shortening of limbs	Cleft palate	Mortality depends on respiratory obstruction; for neonatal survivors, prognosis generally good	AR: mutations in the DTDST gene
Hypophosphatasia ^[10]	Generalized lack of ossification; poorly mineralized cranium; hypoplastic, demineralized bone	Polyhydramnios	Neonatal or infant death due to respiratory complications in almost all cases	AR: mutations in the ALPL gene
Kyphomelic dysplasia (KD) ^[6]	Severe localized and symmetric bowing of the femora, narrow chest, 11 pairs of ribs, short and flared ribs, platyspondyly, metaphyseal flaring with relative sparing of the remainder of the skeleton.	Micrognathia	Normal cranium and psychomotor development	AR
Osteogenesis imperfecta ^[5,10]	Multiple in utero fractures; rib deformities; variable shortening of the long bones; narrow thorax/funnel chest	Normal or mildly increased fluid	Depends on the severity of the specific phenotype (type I and IV, health generally good; type II, neonatal lethal)	AD: mutations in either COL1A1 or
Stüve Wiedemann osteochondrodysplasia ^[6]	Bowed long bones, joint restrictions, unusual bone fractures, abnormal trabecular pattern	Dysautonomia, respiratory and feeding difficulties, middle face hypoplasia	Death in the neonatal period and infancy	AR: mutations in the leukemia inhibitory factor receptor gene (LIFR)
Thanatophoric Dysplasia ^[10]	Narrow thorax/funnel chest; macrocephaly; proportionate shortening of limbs	Hydrocephalus; polyhydramnios; decreased fetal activity	Lethal micromelic dwarfism due to respiratory complications	AD: mutations in the FGFR3 gene

AD: Autosomal dominant; AR: Autosomal recessive; HC: Head circumference; IUGR: Intrauterine growth restriction

Declaration of patient consent

The authors certify that they have obtained all appropriate patient consent forms. In the form the patient(s) has/have given his/her/their consent for his/her/their images and other clinical information to be reported in the journal. The patients understand that their names and initials will not be published and due efforts will be made to conceal their identity, but anonymity cannot be guaranteed.

Financial support and sponsorship

Nil.

Conflicts of interest

There are no conflicts of interest.

References

- Taybi H, Lachman RS. Campomelic dysplasia. In: Radiology of Syndromes, Metabolic Disorders and Skeletal Dysplasias, 3rd ed. London: Year Book Medical Publishers; 1990. p. 694-5.
- Houston CS, Opitz JM, Spranger JW, Macpherson RI, Reed MH, Gilbert EF, *et al.* The campomelic syndrome: Review, report of 17 cases, and follow up on the currently 17-year-old boy first reported by Maroteaux *et al.* in 1971. Am Med Genet 1983;15:3-28.
- Jo A, Denduluri S, Zhang B, Wang Z, Yin L, Yan Z, *et al.* The versatile functions of Sox9 in development, stem cells, and human diseases. Genes Dis 2014;1:149-61.
- Maroteaux P, Spranger J, Opitz JM, Kucera J, Lowry RB, Schimke RN, *et al.* The campomelic syndrome. Presse Med 1971;79:1157-62.
- Jones KL. Smith's Recognizable patterns of Human Malformation, 5th ed. Philadelphia: WB Saunders; 1997. p. 344-5.
- Superti-Furga A, Unger S, The Nosology Group of the International Skeletal Dysplasia Society. International Nosology and Classification of Skeletal Disorders F2006 Revision. Am J Med Genet A 2007;143A: 1-18.
- Bi W, Deng JM, Zhang Z, Behringer RR, de Crombrughe B. Sox9 is required for cartilage formation. Nat Genet 1999;22:85-9.
- Bell DM, Leung KK, Wheatley SC, Ng LJ, Zhou S, Ling KW, *et al.* SOX9 directly regulates the type-II collagen gene. Nat Genet 1997;16:174-8.
- Wagner T, Wirth J, Meyer J, Zabel B, Held M, Zimmer J, *et al.* Autosomal sex reversal and campomelic dysplasia are caused by mutations in and around the SRY-related gene SOX9. Cell 1994;79:1111-20.
- Romero R, Pilu G, Jeanty P, Ghidini A, Hobbins JC. Prenatal diagnosis of congenital anomalies. East Norwalk, CT: Appleton and Lange; 1988.