



## Case Report

# “PERT-inent” Management: The Role of the Pulmonary Embolus Response Team in Managing Paradoxical Embolus in Transit

Dinesh Selvakumar, MBBS, FRACP,<sup>a,b</sup> and Jimmy Chien, BMed, PhD, FRACP<sup>b,c</sup>

<sup>a</sup> Department of Cardiology, Westmead Hospital, Westmead, New South Wales, Australia

<sup>b</sup> School of Medicine, The University of Sydney, Sydney, New South Wales, Australia

<sup>c</sup> Department of Respiratory & Sleep Medicine, Westmead Hospital, Westmead, New South Wales, Australia

### ABSTRACT

A 52-year-old man presented with palpitations and dyspnea. Extensive bilateral pulmonary emboli (PEs) were identified on computed tomography pulmonary angiogram. Transthoracic echocardiography demonstrated a mobile bi-atrial thrombus straddling the interatrial septum. Consensus decision of a multidisciplinary pulmonary embolus response team was made for emergency thrombectomy of the pulmonary and intra-cardiac clot. Intraoperatively, a patent foramen ovale was identified and repaired. He had an excellent outcome and was discharged home on oral anticoagulation. In this unique case of a bi-atrial thrombus and sub-massive PEs, we demonstrate the utility of dedicated pulmonary embolus response teams in providing rapid and individualized management decisions for complex PE patients.

### RÉSUMÉ


Un homme de 52 ans s'est présenté avec des palpitations et une dyspnée. Des embolies pulmonaires (EP) bilatérales étendues ont été identifiées sur l'angiographie pulmonaire par tomodensitométrie. L'échocardiographie transthoracique a mis en évidence un thrombus mobile biauriculaire à cheval sur le septum interauriculaire. Une équipe multidisciplinaire spécialisée dans la réponse à l'embolie pulmonaire a décidé par consensus de procéder à une thrombectomie d'urgence du caillot pulmonaire et intracardiaque. En peropératoire, un foramen ovale a été identifié et réparé. Le patient a reçu un excellent pronostic et a été renvoyé chez lui sous anticoagulation orale. À travers ce cas inhabituel de thrombus biauriculaire et d'EP limitée, nous démontrons l'utilité d'équipes spécialisées dans la réponse aux embolies pulmonaires pour des décisions rapides et individualisées de prise en charge des patients souffrant d'EP complexes.

A previously well 52-year-old man with no risk factors for pulmonary embolus (PE) presented with a 1-week history of palpitations and worsening dyspnea. He was normotensive but in rapid atrial fibrillation with a heart rate of 140 beats per minute. He was also hypoxic, saturating at 88% on room air, which corrected with low-flow supplemental oxygen.

His right leg was swollen, and D-dimer and high-sensitive troponin I levels were elevated ( $> 10$  mg/L [Ref:  $< 0.46$  mg/L] and 181 ng/L [Ref:  $< 17$  ng/L], respectively). Duplex ultrasonography showed extensive deep vein thrombosis in the right leg. Computed tomography pulmonary angiogram identified features of right ventricular strain (flattening of the interventricular septum and right ventricular enlargement, with right: left ventricle ratio  $> 0.9$ ), along with large, bilateral PEs

involving the left and right main pulmonary arteries (Fig. 1C). Note was also made of filling defects in both the left and right atria, suggestive of bi-atrial thrombus (Fig. 1B).

A diagnosis of sub-massive PE was made, and treatment with unfractionated heparin was initiated.

Transthoracic echocardiography was promptly performed to further assess right heart function and investigate for the possible intracardiac thrombus. This showed right ventricular dilatation and systolic dysfunction (fractional area change: 26% [Ref:  $> 35\%$ ], right ventricle S prime: 8 mm/s [Ref:  $> 9.5$  mm/s], tricuspid annular plane systolic excursion: 12 mm [Ref:  $> 17$  mm]). A linear mobile echogenic mass, presumed to be a thrombus, was identified within both atria across the interatrial septum, as suggested on the computed tomography pulmonary angiogram (Fig. 2A and Video 1 , view video online).

An urgent case conference was held among the dedicated PE response team (PERT) members—specialists in cardiology, pulmonology, cardiothoracic surgery, hematology, emergency, and intensive care medicine. Given the high risk of further pulmonary or systemic embolization, a consensus decision was made for the patient to undergo emergent

Received for publication March 17, 2020. Accepted June 14, 2020.

**Ethics Statement:** This research adhered to relevant ethical guidelines.

Corresponding author: Dinesh Selvakumar, 176 Hawkesbury Road, Westmead, NSW 2145, Australia. Tel: +1-612 8627 3000.

E-mail: [dinesh.selvakumar@sydney.edu.au](mailto:dinesh.selvakumar@sydney.edu.au)



See page 690 for disclosure information.

### Novel Teaching Points

- Paradoxical embolus in transit is a rarely identified phenomenon in which a thrombus that has embolized to the right heart communicates with the left heart via an abnormal interatrial communication. It may complicate more common conditions such as PE.
- The presence of concomitant paradoxical embolus in transit in patients with PE can drastically alter management decisions. An intra-cardiac thrombus should be considered in patients with PE and high thrombus burden.
- PERTs allow for a rapid, multidisciplinary, individualized, and coordinated approach to the management of patients with complex PE presentations.

surgical clot retrieval via median sternotomy. The option of inserting an inferior vena cava (IVC) filter to mitigate extension of the cardiac and pulmonary clot was also considered. However, given that the patient did not fulfil classic criteria for filter insertion (contraindications to anticoagulation, or recurrent thrombus despite adequate anticoagulation),<sup>1</sup> the decision was made to proceed with embolectomy alone.

This rapid decision-making was made possible by the unique nature of the PERT, and the patient underwent definitive surgical therapy within hours of his initial presentation to the hospital (Fig. 1A).

Intraoperative transoesophageal echocardiography confirmed the presence of a patent foramen ovale that allowed the thrombus to communicate with the left atrium (Fig. 2B and Video 2 , view video online). The thrombus was highly mobile within the left atrium and was noted to prolapse into the left ventricle across the mitral valve (Video 3 , view video online). Extensive clot was successfully retrieved from both atria (Fig. 2C) and the pulmonary arteries, and the patent foramen ovale was concurrently repaired.

He had an excellent perioperative course and was extubated in the intensive care unit on day 0 postoperatively. Based on physical examination, there was no clinical evidence of systemic embolization, and he had reverted to sinus rhythm by the time of discharge. He was discharged from the hospital on warfarin but was transitioned to rivaroxaban on outpatient review. Outpatient investigations for acquired and genetic causes of thrombophilia were negative, and he has been advised to continue anticoagulation treatment indefinitely.

### Discussion

We present a unique case of sub-massive PE complicated by “paradoxical embolus in transit,” also known as “impending paradoxical embolus.” Elevated pulmonary pressure secondary to the PE likely preconditioned the patent foramen ovale to open, permitting extension of the thrombus into the left atrium.<sup>2</sup>

Paradoxical emboli in transit are rare entities, infrequently described in live patients. As such, no consensus guidelines exist regarding management. This condition, however, is acknowledged to be life-threatening, with a 30-day mortality of 18.4%.<sup>3</sup> This statistic, however, does not specifically

include patients with coexisting pulmonary emboli as in our case, who are at considerably higher risk.

Isolated right-heart thrombi complicating PE is relatively more common, with a prevalence of up to 18% among PE patients in the intensive-care setting.<sup>4</sup> They are associated with high early mortality, particularly in patients with right ventricular dysfunction, and can be classified into 2 distinct phenotypes based on morphology and etiology:<sup>5</sup>

- Type A thrombi are characterized as long, thin, and extremely mobile, generally originating from deep vein thrombosis.
- Type B thrombi, in contrast, are short, round, and less mobile. They generally arise from within the heart itself and are associated with conditions such as cardiac failure, intra-cardiac foreign bodies, and pacemaker electrodes.

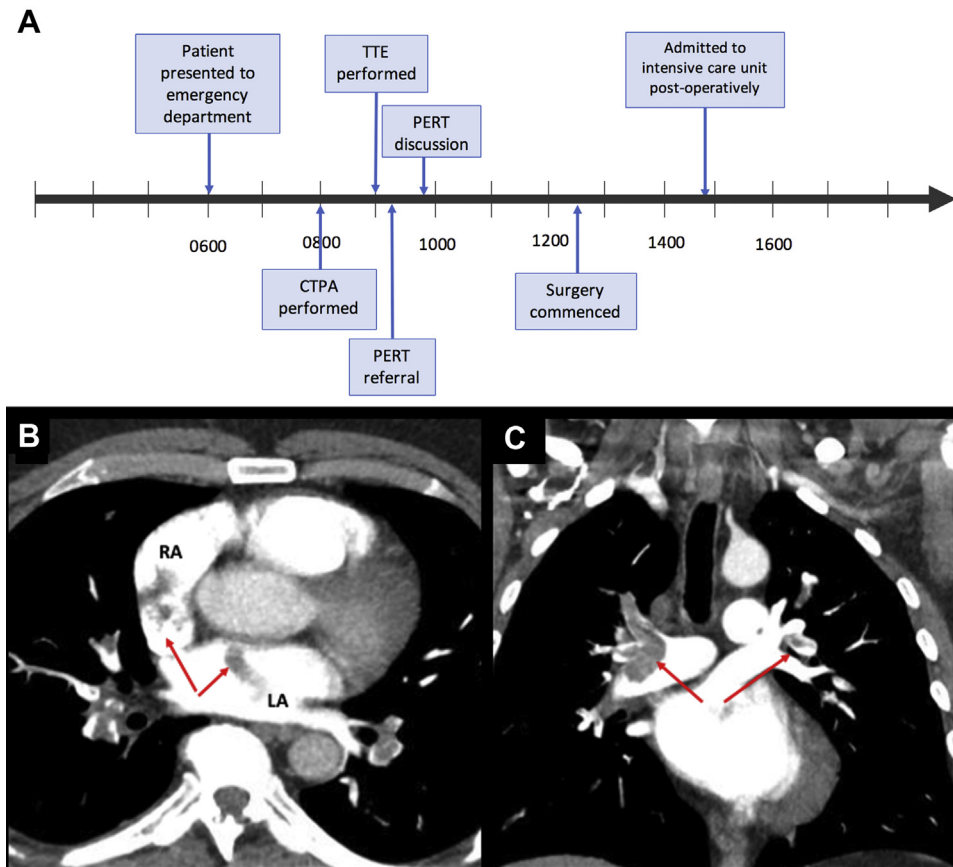
Patent foramen ovale is a well-documented risk factor of paradoxical systemic embolization and has been reported in up to 25% of patients who have acute PE. It is an important independent predictor of death, systemic embolization, and complicated hospital admission in this patient group.<sup>6</sup>

The ideal management of patients with a patent foramen ovale and impending paradoxical embolism remains a subject of debate, with no randomized controlled trial data available to guide decision-making. Options include systemic anticoagulation, thrombolytic (either systemic or catheter-directed), and surgical therapy. Anticoagulation and thrombolytic therapy may reduce thrombus burden but increase the risk of fragmentation and subsequent embolization.<sup>3</sup> Only the surgical approach allows for the simultaneous removal of thrombi and closure of the patent foramen ovale; however, surgery in this setting carries substantial risks, including the risks of general anaesthesia and cardiopulmonary bypass. Depending on the series, the mortality rate after pulmonary embolectomy can approach 50%, with preoperative hemodynamic status regarded as the most important prognostic indicator.<sup>7</sup> In hemodynamically stable patients, however, as in our case, surgical embolectomy can have excellent long-term results.<sup>7</sup>

A systematic review<sup>3</sup> explored these management options by analyzing pooled observational data from 154 studies (174 patients in total). Although not statistically significant, a trend was found toward reduced 30-day mortality in those treated with surgical thrombectomy as compared to thrombolysis or anticoagulation therapy alone. The surgical approach was also shown to significantly reduce systemic embolization as compared to anticoagulation treatment alone.

For now, treatment of this life-threatening condition should be established on a case-by-case basis, although it is universally acknowledged that impending paradoxical embolism is a medical emergency and that delay in treatment of whichever form could have catastrophic consequences.

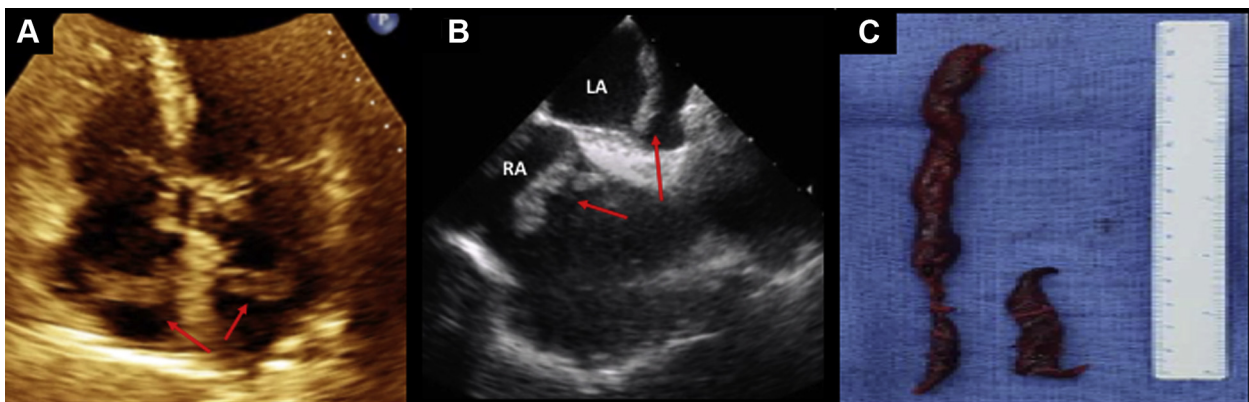
In our case, the management approach was agreed upon by a group of specialists comprising the PERT. PERTs are multidisciplinary teams dedicated to the discussion and management of high-risk PE cases. The management of PE is becoming increasingly complex, with relatively new interventions such as thrombolysis and clot extraction now more commonly used, and the PERT model has emerged as a valuable management tool.<sup>8</sup> In our high-volume tertiary



**Figure 1.** (A) Timeline depiction of events from hospital admission to surgical recovery. Computed tomography pulmonary angiography (CTPA) showing filling defects in (B) left (LA) and right atria (RA) and in (C) left and right main pulmonary arteries. PERT, pulmonary embolism response team; TTE, transthoracic echocardiography.

hospital, the PERT was established to streamline patient care, improve access to interventional therapies, and address limitations associated with the consultation of multiple specialties at different timepoints. The team comprises a group of senior clinicians with demonstrated experience in the management of PE, and it is made up of a respiratory physician, emergency physician, hematologist, interventional radiologist, and

intensivist, at a minimum, with additional input from a cardiologist, cardiothoracic surgeon, or vascular surgeon as required. A PERT call can be activated by the treating emergency or respiratory physician for any complex PE patient. This initiates a rapid-response case conference (either in person or via secure teleconference or video conference) among all specialists, allowing for real-time expert insights



**Figure 2.** Interatrial thrombi. (A) Transthoracic echocardiography apical 4-chamber view demonstrating long and thin echogenic mass within both atria across interatrial septum. (B) Intraoperative transoesophageal echocardiography short-axis view demonstrating bi-atrial thrombus straddling a patent foramen ovale. (C) Gross morphologic appearance of intra-cardiac thrombus after surgical evacuation.

into patient management. The patient case and imaging are presented, followed by discussion on optimal management options for each individual case.

The unique challenges faced by this case were ideally suited to the multidisciplinary structure of a PERT. This allowed an immediate, multidisciplinary case conference and resulted in optimal individualized care and an excellent patient outcome, with the patient having had definitive surgical therapy within hours of his initial presentation to the hospital.

### Funding Sources

This research did not receive any specific grant from funding agencies in the public, commercial, or not-for-profit sectors. This study was self-funded.

### Disclosures

The authors have no conflicts of interest to disclose.

### References

1. Konstantinides SV, Meyer G, Becattini C, et al. 2019 ESC guidelines for the diagnosis and management of acute pulmonary embolism developed in collaboration with the European Respiratory Society (ERS): The Task Force for the Diagnosis and Management of Acute Pulmonary Embolism of the European Society of Cardiology (ESC). *Eur Heart J* 2019;41:543-603.
2. Amin N, Mehta A, Castresana M, Arthur M. Massive thrombus in transit detected by echocardiography. *J Cardiothorac Vasc Anesth* 2008;22:333-6.
3. Myers PO, Bounameaux H, Panos A, Lerch R, Kalangos A. Impending paradoxical embolism: systematic review of prognostic factors and treatment. *Chest* 2010;137:164-70.
4. Torbicki A, Galic N, Covezzoli A, et al. Right heart thrombi in pulmonary embolism: results from the International Cooperative Pulmonary Embolism Registry. *J Am Coll Cardiol* 2003;41:2245-51.
5. The European Cooperative Study on the clinical significance of right heart thrombi. European Working Group on Echocardiography. *Eur Heart J* 1989;10:1046-59.
6. Konstantinides S, Geibel A, Kasper W, et al. Patent foramen ovale is an important predictor of adverse outcome in patients with major pulmonary embolism. *Circulation* 1998;97:1946-51.
7. Sekhri V, Mehta N, Rawat N, Lehrman SG, Aronow WS. Management of massive and nonmassive pulmonary embolism. *Arch Med Sci* 2012;8:957-69.
8. Dudzinski DM, Piazza G. Multidisciplinary pulmonary embolism response teams. *Circulation* 2016;133:98-103.

### Supplementary Material

To access the supplementary material accompanying this article, visit *CJC Open* at <https://www.cjcopen.ca/> and at <https://doi.org/10.1016/j.cjco.2020.06.006>.