

Received: 2022.09.14

Accepted: 2022.11.11


Available online: 2022.12.28

Published: 2023.01.16

A 63-Year-Old Postmenopausal Woman with Uterine Inversion Associated with a Submucosal Geburt Fibroid Successfully Treated by Surgical Reversal Using the Spinelli Procedure

Authors' Contribution:

Study Design A
Data Collection B
Statistical Analysis C
Data Interpretation D
Manuscript Preparation E
Literature Search F
Funds Collection G

A **Eighty Mardiyani Kurniawati**
DEF **Henry M. Masteryanto**
EF **Gatut Hardianto**
DF **Hari Paraton**
DE **Tri Hastono Setyo Hadi** 

Department of Obstetrics and Gynecology, Faculty of Medicine,
Universitas Airlangga, Surabaya, Indonesia

Corresponding Author: Eighty Mardiyani Kurniawati, e-mail: eighty-m-k@fk.unair.ac.id
Financial support: None declared
Conflict of interest: None declared

Patient: Female, 65-year-old
Final Diagnosis: Chronic uterine inversion due to submucous leiomyoma
Symptoms: Complaints of lower abdominal pain, difficulty in defecating, and a mass in the genitals when straining accompanied by clots of bleeding
Medication: —
Clinical Procedure: —
Specialty: Obstetrics and Gynecology

Objective: Rare disease
Background: Reproductive health affects long-term quality of life, including in the elderly. Uterine inversion is common in postpartum women in developing countries and menopausal women are also at risk.
Case Reports: A 65-year-old menopausal woman had 3 children and a history of uterine tumors and curettage. She had received a different diagnosis – a cervical tumor – exactly 3 years ago. She was admitted to a referral hospital for lower abdominal pain, difficulty in defecating, and a mass in the genitals when straining, accompanied by blood clots. There was a 20×20 cm mass protruding from the vagina, and the uterine fundus of the uterus was not palpable. The patient was diagnosed with chronic uterine inversion due to submucous leiomyoma. Management requires the collaboration of multidisciplinary professionals in hospitals. These patients receive therapy to improve their general condition, transfusions, antibiotics, and a hysterectomy plan. The results of the Urogynecology Division showed that a 20×15 cm mass came out of the vagina, with a large necrotic area. The patient was first managed by Spinelli procedure to correct the uterine inversion, followed by an abdominal hysterectomy. Histopathology revealed the final diagnosis as a benign mesenchymal lesion, leiomyoma with myxoid degeneration.
Conclusions: Timely diagnosis and management by a multidisciplinary team can help reduce morbidity and mortality in patients with submucosal uterine leiomyoma leading to chronic uterine inversion.

Keywords: Chronic Disease • Myoma • Uterine Inversion

Full-text PDF: <https://www.amjcaserep.com/abstract/index/idArt/938390>

 2299

 —

 7

 25



Publisher's note: All claims expressed in this article are solely those of the authors and do not necessarily represent those of their affiliated organizations, or those of the publisher, the editors and the reviewers. Any product that may be evaluated in this article, or claim that may be made by its manufacturer, is not guaranteed or endorsed by the publisher

Background

As a result of increased life expectancy, the elderly population is growing rapidly. Older women outnumber older men and the health problems of an aging population are largely related to women's health problems [1]. Understanding reproductive health in the elderly, especially women, is very important because there are so many changes that occur when women enter old age. Women who enter menopause will experience hormonal changes followed by various problems, such as lack of support by the pelvic muscles [2].

Uterine inversion is a condition in which the uterus comes out with the prolapse of the fundus through the cervix [3]. The causes of uterine inversion can be broadly classified as puerperal or non-puerperal. Puerperal uterine inversion is more common than non-puerperal uterine inversion. The acute inversion that occurs immediately or within 24 hours postpartum is the most common type. The differential diagnosis in such patients includes prolapsed fibroids and endometrial polyps [4]. The provisional diagnosis of chronic uterine inversion is made based on vaginal findings of a globular mass protruding from the cervix. This mass approaches the vagina so that cervical effacement occurs around the mass, forming a tight constriction ring, and ultrasound findings can be useful [5]. If these cases are not identified immediately, large and underestimated blood loss can lead to hypovolemic shock. Therefore, early diagnosis and treatment of this condition are crucial [6]

Prevalence studies have found that 5.4% to 77% of women have myomas, but this depends on the study population and the diagnostic technique applied [7]. According to the location, myomas can be divided into the following 3 types: intramural myomas, submucosal myomas, and subserous myomas, among which intramural myomas are the commonest. Surveys show that the incidence of uterine submucosal myomas is about 20% to 40%, and this disease often occurs in women aged 30 to 50 years. However, based on recent research, the incidence of submucosal myomas in the uterus is higher in younger women [8]. Treatment depends on the location and size of the myoma [9]. Because the growth of leiomyomas is estrogen-dependent, they usually regress in postmenopausal women. Our case is interesting in that it was a submucous myoma in a postmenopausal woman that led to chronic uterine inversion and severe anemia, causing severe morbidity.

Case Report

Our patient was a 65-year-old postmenopausal woman who had 3 children. She had a history of uterine tumor and curettage with a benign tumor 3 years ago. She presented her concern of vaginal bleeding at 2 different first-level hospitals. She

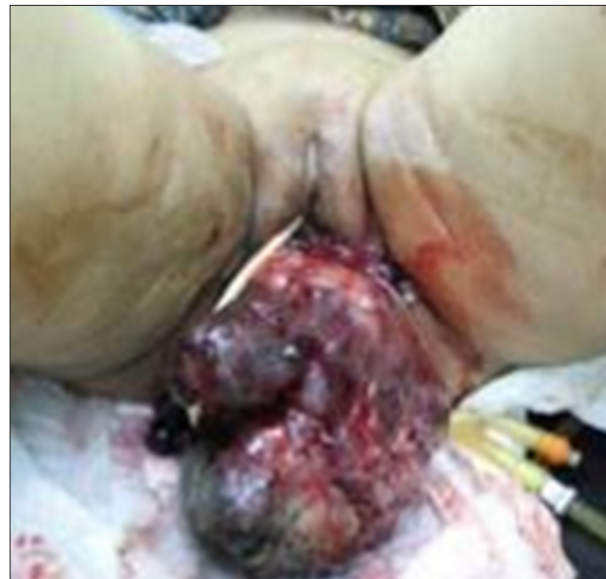

Figure 1. Vaginal mass, humped, brittle.

received a diagnosis of a cervical tumor and was referred to a tertiary health facility but did not continue therapy and instead took traditional herbal medicine. She reported being unable to urinate, as well as discharging blood and clots from the vagina, so she went to a different hospital within 1 week of experiencing this problem. At the last hospital, she was catheterized and was transfused with 2 units of blood. She was diagnosed as having a cervical mass (Figure 1).

The patient finally decided to get treatment at a referral hospital after her general condition improved. On arrival, the patient had lower abdominal pain and difficulty defecating. When she strained during defecation, a lump came out of the genitals the size of a baby's head, accompanied by blood clots. She tried to push the mass back in but could not. The patient showed weakness and anemia. There was a 20x20 cm mass protruding from the vagina and the uterine fundus of the uterus was not palpable. She was initially diagnosed with cervical myoma and anemia due to a hemoglobin level of 7.2 g/dl. On gynecological examination, a 20x20 cm mass seen protruding from the vagina. The hemoglobin level fell to 6.1 g/dl, detected 3 days after the first examination.

Figure 2 shows an ultrasound view of the abdomen, (a) sagittal slice, and (b) transverse slice. The ultrasound examination of the uterus showed normal size and shape, and no visible mass protruding. There was no visible intensity of free fluid echo in the abdominal cavity and right left pleural cavity. There was no visible lymph node enlargement in the para-aortic region. The patient was diagnosed with chronic uterine inversion, uterine myoma, anemia, hypoalbuminemia, and hyponatremia. Her general condition improved after transfusion and administration of antibiotics, and hysterectomy was suggested. She was

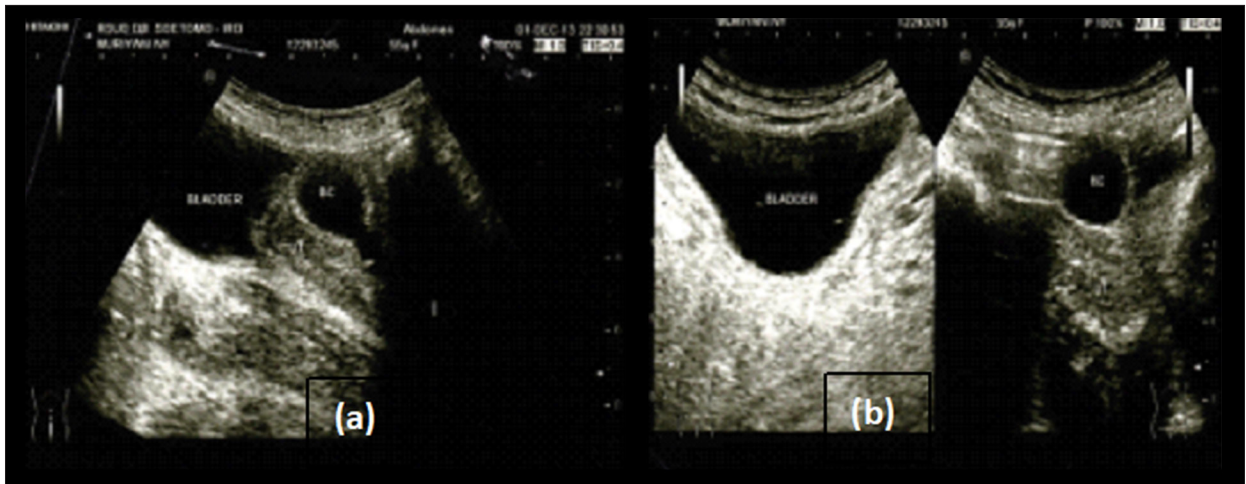


Figure 2. Ultrasound view of the abdomen, (a) sagittal slice, (b) transverse slice.

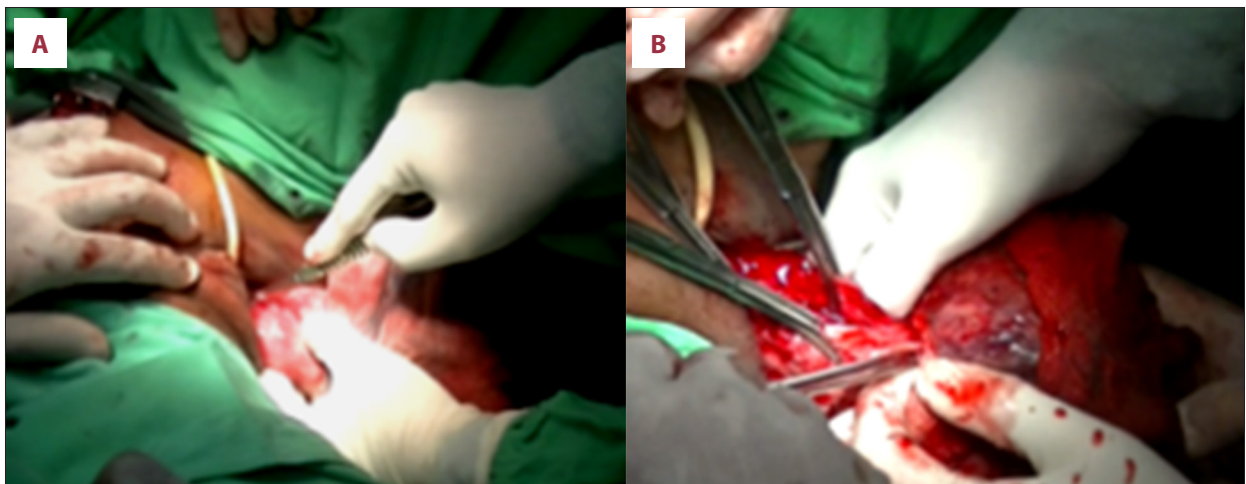


Figure 3. (A, B) Vaginal approach: anterior uterine wall incision presented.

examined at the Oncology Department and received a diagnosis of Geburt myoma and uterine prolapse. She was discharged after her general condition started to improve.

She received a follow-up examination at the Urogynecology Division, which showed a 20x15 cm mass protruding from the vagina, with a large necrotic area, and the uterine body was not palpable. She was diagnosed with chronic uterine inversion and had a differential diagnosis of pedunculated submucosal myoma. Follow-up treatment consisted of the Spinelli procedure and hysterectomy. The Spinelli procedure was done by an incision made on the anterior aspect of the cervix and then the uterus was reinverted. It was not possible to remove the fibroid vaginally because it was pedunculated, so she underwent vaginal hysterectomy because of uterine inversion.

The technique of abdominal hysterectomy was laparotomy, retraction, restoring normal anatomy, uterine elevation, division of the round ligament and accessing the retroperitoneal space,

bladder reflection, exposure of the iliac arteries, division of the ovarian vessels, skeletonization of the uterine artery and vein, dividing the uterine vessels, dissection of the rectum, dividing the broad ligament, dividing the vagina, closing the vaginal cuff, and final examination and closure. Exploration revealed complete uterine inversion, right and left adnexa, tubes within normal limits, and ovarian impression atrophy. The results of the anatomical pathology examination showed a mass in the uterus, which was a benign mesenchymal lesion. This mass also led to leiomyoma with myxoid degeneration. The results of the microscopic immunohistochemistry examination showed positive results in 90% of tumor cells, with strong intensity. Smooth muscle actin (SMA) showed positive results, indicating leiomyoma. At the time of recovery, she had urinary incontinence and was unable to hold urine after the catheter was removed.

The treatment process is carried out with a vaginal approach and an abdominal approach. In the vaginal approach, the anterior uterine wall incision is presented in **Figure 3**, the

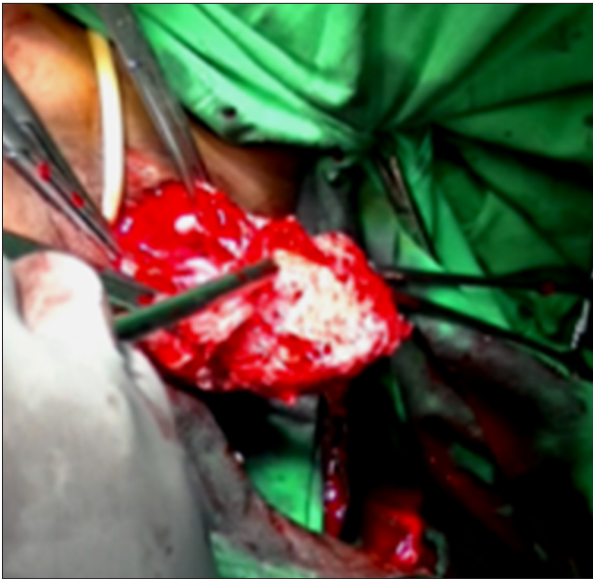


Figure 4. Vaginal approach: uterus after release of the submucous myoma.

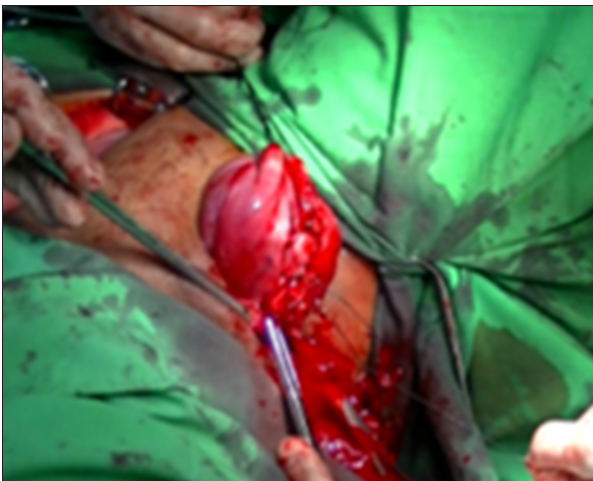

Figure 5. Vaginal approach: suture to the uterine wall incision presented.

uterus after removal of the submucosal myoma is presented in **Figure 4**, and the suture to the incision in the uterine wall is presented in **Figure 5**. In the abdominal approach, the uterus after repositioning the abdominal cavity is presented in **Figure 6** and the condition of the uterus after hysterectomy is presented in **Figure 7**. The patient also underwent biofeedback exercise, which helped to reduce stress urinary incontinence. She also completed a quality-of-life questionnaire, muscle strength testing, and kept a urination diary. She had follow-ups at 6 weeks, 3 months, and 6 months. The results showed a reduction in stress urinary incontinence.

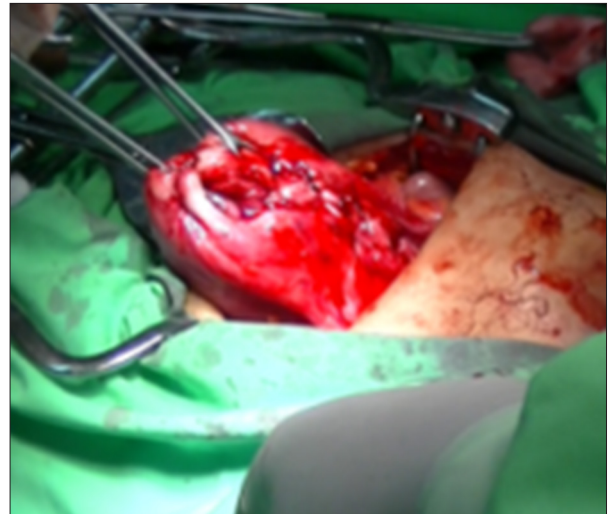

Figure 6. Abdominal approach: uterus after repositioning the cavum abdomen.

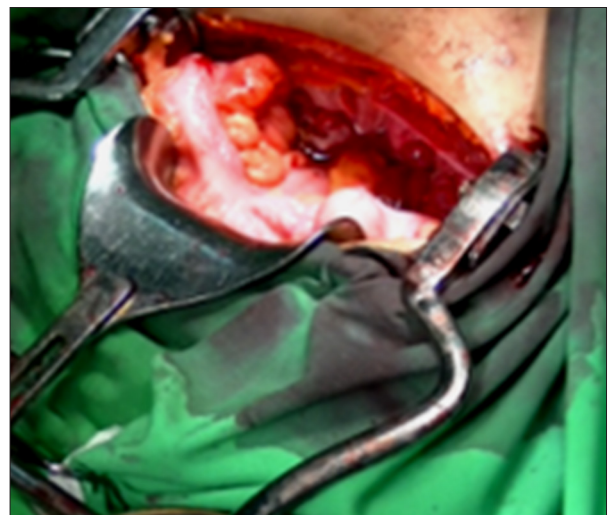

Figure 7. Abdominal approach: after hysterectomy.

Discussion

This is a rare case, so timely diagnosis and management by a multidisciplinary team can help reduce patient morbidity and mortality. The patient received therapy to improve her general condition, as well as transfusions and antibiotics, and a hysterectomy plan was carried out. The patient first underwent a Spinelli procedure to correct the uterine inversion, followed by an abdominal hysterectomy. This treatment varies depending on the type and condition of the patient. Management of a 32-year-old nulliparous woman with 17 years of unexplained infertility and a diagnosis of a large vaginal prolapsed non-pedunculated leiomyoma was performed by the Haultain procedure; this procedure is used to reposition the inverted uterus and remove the leiomyoma through a posterior incision using a laparotomy [10]. The difference in treatment refers to the type

of approach – abdominal approaches and vaginal approaches. The Huntington and Haultain procedures are commonly used abdominal approaches and the Kustner and Spinelli procedures are commonly used vaginal approaches. In the present case, the Spinell procedure was used for chronic uterine inversion. This technique involves dissection of the bladder from the inverted uterus. A midline split is made at the cervix and carefully separated from the bladder. The anterior wall of the everted uterus is split. With pressure from the surgeon's index finger and thumb, the uterus is turned outward. The myometrium is re-approached with 2 layers of sutures, and the serous surface with 1 layer. The vaginal skin is re-approximated with interrupted sutures, as is the entire thickness of the cervix. Vaginal restoration and removal are difficult [11]. Treatment is directed at hysterectomy. In another report, a woman underwent a total abdominal hysterectomy with an anterior longitudinal incision to release a tight ring around the fibroid and fundus, followed by excision of the myoma [12].

The present patient had several changes in diagnosis. For health-care providers, diagnosis is one of the many components necessary during the clinical decision-making process and involves differentiation of the structure of the underlying condition. The diagnostic process involves identification of the etiology, identification of the condition through evaluation of the patient's history, physical examination, and review of laboratory data or diagnostic imaging and provisional diagnosis. In theory, diagnosis is useful for increasing the use of classification tools, improving clarity and communication, providing treatment trajectories, increasing understanding of prognosis, and, in some cases, may be useful for preventive care [13]. Accurate and timely diagnosis with the smallest probability of missed diagnosis or delayed diagnosis is essential in the management of any disease. Misdiagnosis can lead to unnecessary treatment or failure to treat and harms both the patient and the health care system [14]. Chronic inversion should be kept as a differential diagnosis in a patient with a history of irregular bleeding associated with lower abdominal dragging pain and a feeling of a mass protruding from the introitus. Before surgery, it should be differentiated from fibroid polyps, uterine prolapse, and prolapsed hypertrophic ulceration of the cervix [15].

The mechanism of uterine inversion and myoma in this case was likely that the myometrium was swollen due to the tumor in the cavity and the myometrium became irritable and initiated expulsive contractions, which dilated the cervix and aided in the expulsion of the tumor, dragging its fundal attachment. Tumor weight, manual traction of the tumor, or increased intra-abdominal pressure from coughing, straining, and sneezing can also contribute. The area of the uterine wall that is weakened due to growth will enter the cavity so that it is under the influence of the active uterine muscles. Leiomyoma is the most common cause of uterine inversion, and most are caused by

malignancy [16]. Myomas are associated with the capacity of the myoma to dilate the endometrial cavity (with an increase in size and location), whereas this process triggers an inflammatory reaction in the uterine wall, which causes contraction when attempting to remove the tumor [17].

Chronic uterine inversion requires careful management. The chronic nature of this inversion makes restoring the normal uterus per vagina difficult, in contrast to acute inversion, which can be corrected more easily [4]. The treatment, in this case, was the Spinelli technique. The Spinelli and Kustner techniques use a transvaginal approach that involves replacement of the uterine fundus through the anterior and posterior transaction of the cervix. In the Spinelli procedure, an incision is made on the anterior aspect of the cervix and then the uterus is repositioned [18]. This technique is rarely used today, as several newer methods have recently been described [19]. After repositioning, the uterine incision can be repaired or a vaginal hysterectomy can be performed with the uterus in its anatomical position [16]. Kustner's vaginal approach is usually used to treat cases of chronic puerperal inversion. The Spinelli procedure is similar to the Kustner procedure, but the uterine incision is made on the anterior aspect of the uterus after the bladder is dissected upwards [20]. Division of the constricting cervical ring anteriorly through the vagina is used in the Spinelli procedure, which requires careful handling of the bladder and ureter, and it is associated with more urinary and future pregnancy complications than the posterior approach [21]. Our patient was elderly, so there were no concerns about pregnancy. In addition, robotic and laparoscopic surgery have recently been used for chronic uterine inversion. Abdominal cerclage surgery has also been performed to prevent the nucleus from inversion of the uterus [18].

Management tends to be slow and the diagnosis needs to be made carefully, as the condition can be affected by patient behavior. In our patient, taking traditional herbal medicine was part of the reason why she did not undergo further examination. Traditional, complementary, and alternative medicine (TCAM) is a method of treatment used extensively to treat a variety of diseases, especially for patients with 2 or more chronic diseases [22]. It is used in health care as well as in the prevention, diagnosis, and treatment of physical and mental illnesses [23]. The prevalence of the use of traditional and complementary medicine in the general population worldwide ranges from 9.8% to 76%, and it is used due to perceived poor health, to achieve a sense of well-being, and as integrative medicine [24].

Finally, our patient's condition improved. Biofeedback exercise for stress urinary incontinence is an increasing popular method of urinary incontinence treatment, while also teaching women self-awareness of their bodies and the physiological processes taking place [25].

Conclusions

Submucous uterine leiomyoma leading to chronic uterine inversion is rare in the elderly. Timely diagnosis and management by a multidisciplinary team can help reduce morbidity and mortality in patients with submucosal uterine leiomyoma leading to chronic uterine inversion. Patient cooperation with follow-up is also needed to avoid delays in receiving health-care services.

References:

1. Soenar YM, Kasim D. Reproductive health education in the elderly. *Asian Journal of Applied Sciences*. 2019;7(5):624-29
2. Senayakake P. Women and reproductive health in a graying world. *Int J Gynecol Obstet*. 2000;70(1):59-67
3. Rudra S, Naredi N, Duggal BS, Seth A. Chronic uterine inversion: A rare complication of mismanaged labour. *Med J Armed Forces India*. 2010;66(1):91-92
4. Ali E, Kumar M. Chronic uterine inversion presenting as a painless vaginal mass at 6 months post-partum: A case report. *J Clin Diagn Res*. 2016;10(5):QD07-8
5. Garg P, Bansal R. Unusual and delayed presentation of chronic uterine inversion in a young woman as a result of negligence by an untrained birth attendant: A case report. *J Med Case Rep*. 2020;14(1):143
6. Indra UB. Chronic uterine inversion due to myoma geburt. *Open Access Maced J Med Sci*. 2021;8(C):223-25
7. Sparic R, Mirkovic L, Malvasi A, Tinelli, A. Epidemiology of uterine myomas: A review. *Int J Fertil Steril*. 2016;9(4):424-35
8. Liang B, Xie YG, Xu XP, Hu CH. Diagnosis and treatment of submucous myoma of the uterus with interventional ultrasound. *Oncol Lett*. 2018;15(5):6189-94
9. Phaliwong P. The effect of myoma uteri on infertility. *Siriraj Med J*. 2020;72(5):443-50
10. Teimoori B, Esmailzadeh A. A large uterine leiomyoma leading to non-puerperal uterine inversion: A case report. *Int J Reprod Biomed*. 2017;15(1):55-56
11. Shivanagappa M, Bhandiwad A, Mahesh M. A case of acute on chronic uterine inversion with fibroid polyp. *J Clin Diagn Res*. 2013;7(11):2587-88
12. Alsahabi J, Alsomairi A, Elmuzaini F. Non-puerperal uterine inversion due to submucosal fibroid in a nulliparous woman: A case report. *Int J Case Rep Images*. 2019;10:101008
13. Cook CE, Décarý S. Higher order thinking about differential diagnosis. *Braz J Phys Ther*. 2020;24(1):1-7
14. Bolboacă SD. Medical diagnostic tests: A review of test anatomy, phases, and statistical treatment of data. *Comput Math Methods Med*. 2019;2019:1891569
15. Goel J, Sah S, Shashi A, Ruchica G, Nandini A. Chronic uterine inversion associated with fibroid – a case report. *SRMS J. Med. Sci*. 2016;1(2):113-14
16. Herath RP, Patabendige M, Rashid M, Wijesinghe PS. Nonpuerperal uterine inversion: What the gynaecologists need to know? *Obstet Gynecol Int*. 2020;2020:8625186
17. Vieira GTB, Santos GHN, Júnior JBNS, et al. Imaging in medicine. Non-puerperal uterine inversion associated with myomatosis. *Rev Assoc Med Bras*. 2019;65(2):130-35
18. Birge O, Tekin B, Merdin A, et al. Chronic total uterine inversion in a young adult patient. *Am J Case Rep*. 2015;16:756-59
19. Majd SKH, Nawaz T, Ismail L, Luker R. Acute uterine inversion as a cause of major post-partum haemorrhage: A case report and review of the literature. *Internet J. Gynecol. Obstet*. 2020;12(1):56322893
20. Liu H, Bi Z, Hu Q, et al. Non-puerperal uterine inversion with endometrial polyps in an 11-year-old girl: A case report. *J Pediatr Adolesc Gynecol*. 2022;35(2):188-91
21. Mishra S. Chronic uterine inversion following mid-trimester abortion. *J Obstet Gynaecol India*. 2018;68(4):320-22
22. Abidin Z. Determinants of traditional, complementary and alternative medicine (TCAM) Choices: A systematic Review. 3rd Int. Conf. Appl. Sci. Health. 2018
23. Hailu BW. Assessment of learning organization practice and disciplines in case of sire district public health office, Arsi Zone, Oromia Region, Ethiopia. *Eur J Prev Med*. 2018;8(6):106, 202
24. Tangkiatkumjai D, Boardman M, Walker H. Potential factors that influence usage of complementary and alternative medicine worldwide: A systematic review. *BMC Complement Med Ther*. 2020;20(1):363
25. Kopańska M, Torices S, Czech J, et al. Urinary incontinence in women: biofeedback as an innovative treatment method. *Ther Adv Urol*. 2020;12:1756287220934359

Acknowledgements

The authors thank Prof. Prajitno, who has provided knowledge and insight related to the Spinelli Procedure.

Declaration of Figures' Authenticity

All figures submitted have been created by the authors who confirm that the images are original with no duplication and have not been previously published in whole or in part.