

Prospective Evaluation of Role of Limb Reconstruction System (Rail External Fixator) in Open Fractures and Infected Non-union of Femur

Hemant Singh Chahar¹, Mayur Gupta¹, Vinod Kumar¹, Rohit Yadav¹, Jaydeep Patel¹,
Chandra Prakash Pal¹

Learning Point of the Article:

For patients with infected non-union and massive bone loss, limb reconstruction system is an ideal treatment option because of simple method of application, it's good stability, adjustable geometry, lightweight and it can induce/enhance fracture healing by compression and distraction osteogenesis.

Abstract

Introduction: Severe open fractures continue to be a nightmare for orthopedicians even with use of more accepted line of treatment. Open fractures and infected non-union of femur bone are not infrequently seen in orthopedic wards as femur is the most common long bone injured. We present a case series of 14 such patients treated successfully with limb reconstruction system enabling recovery to pre-injury status and activities.

Case Series: The present study was done to assess the role of limb reconstruction system in the management of open femur fractures and in infected non-union with modifications to meet the requirements of each case. We viewed the results of treatment of 14 cases of late presentation with complicated open femur fractures and infected non-unions. Average time of fixator removal was 4 months–24 months. Average follow-up duration was 18 months (range 6–36 months). Evaluation of results was based on ASAMI criteria. The excellent bone results were obtained in 85.72% of cases while 7.14% showed good and 7.14% were poor results. Excellent functional results were observed in 71.43% of cases and 28.57% of cases shows good and fair results.

Conclusion: The use of limb reconstruction system is based on compression and distraction technique. It was found to be a simple and effective modality for open injuries in terms of enhanced union rate, rapid rehabilitation, and easy care of soft-tissue injury along with bone loss, thus avoiding multiple surgeries.

Keywords: Open fracture, non-union, femur, limb reconstruction system, ASAMI criteria.

Introduction

The femur being the most commonly fractured long bone, its fracture treatment has been changing from conservative to surgical management. Road traffic accidents are the most common cause of femur fractures followed by sports related injuries. Because of improper anatomical alignment and associated soft-tissue injuries, the conservative treatment has become less useful. Early return to pre-injury status and pre-injury activities are given as top priority. Non-united fractures of long bones are not only a complex surgical problem but also a chronic and at times debilitating condition. Infected non-union

of long bones is not only a source of functional disability but also can lead to economic hardship and loss of self-esteem. Infected non-union has been defined as a state of failure of union for 6–8 months with persistent infection at the fracture site [1, 2]. Infected non-union can develop after an open fracture, after a previous open reduction and internal fixation, or as sequelae to chronic hematogenous osteomyelitis. The incidence also seems to be increasing especially in view of increasing high-velocity trauma, which is more frequently treated with internal fixation. It is difficult to treat infected non-union [1, 3, 4] because of the following reasons. (1) Previous

Access this article online

Website:
www.jocr.co.in

DOI:
10.13107/jocr.2021.v11.i01.1942

Author's Photo Gallery



Dr. Hemant Singh Chahar



Dr. Mayur Gupta



Dr. Vinod Kumar



Dr. Rohit Yadav



Dr. Jaydeep Patel



Dr. Chandra Prakash Pal

¹Department of Orthopaedics, Sarojini Naidu Medical College, Agra, India.

Address of Correspondence:

Dr. Chandra Prakash Pal,
Department of Orthopaedics, Sarojini Naidu Medical College, Agra, India.
E-mail: drcportho@gmail.com

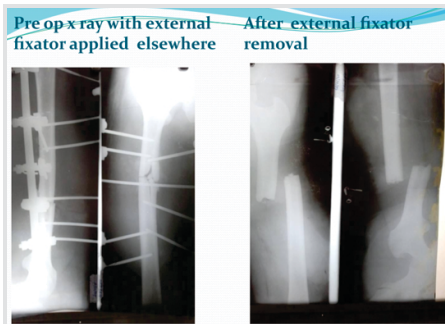


Figure 1: (a) Pre-operative X-ray with external fixator applied elsewhere. (b) After external fixator removal.

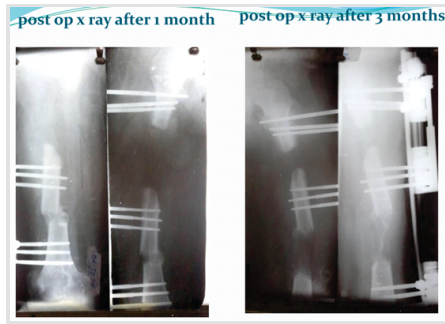


Figure 2: (a and b) Post-operative X-ray after 1 month. (b) Post-operative X-ray after 3 months.

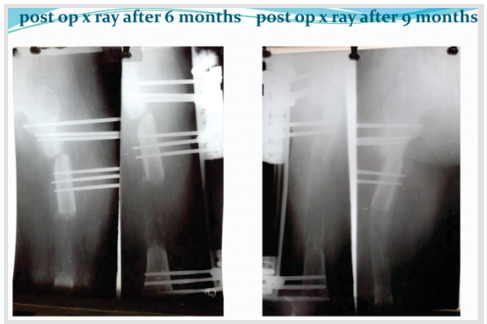

Figure 3: (a) Post-operative X-ray after 6 months. (b) Post-operative X-ray after 9 months.

surgeries would have resulted in cicatrization of the soft tissue with an avascular environment around the fracture site. (2) The sinus tract formation leading on to the fracture site indicating dead bone or sequestrum inside. (3) Necrosis of bone near the nonunion site, to a considerable distance, due to thrombosis of blood vessels of Haversian canals. (4) Prolonged immobilization, multiple surgeries with fibrosis of the muscles leading on to a stiff joint/fracture disease. (5) The microorganism may develop resistance to the antibiotic therapy and poses a problem in controlling the disease. Even after prolonged treatment and repeated surgeries to correct this problem, the outcome is unsure and amputation may be the only alternative left. Hence, the treatment of non-union of long bones associated with infection is a formidable challenge to the orthopedic surgeon. Bone union is not usually obtained until the infection has been eradicated. The method known as the distraction osteogenesis [5] simultaneously addresses deformity, shortening, loss of bone function, osteoporosis, and soft-tissue atrophy. There are various modalities of treatment for infected nonunion. In the past, there were several authors who put their mind in solving this problem by many methods where in all the factors of non-union such as deformity, shortening, infection, and abnormal mobility were managed. According to AO manual [4], external fixator is considered as the standard method of fixation in infected non-union. Internal fixation is deferred in case of infected nonunion for the fear of persistence/recurrence of infection. The dynamic external fixator system is a unilateral external fixator system. With the frequent association of infection, bone defect, limb shortening,

deformity, and soft-tissue problems with atrophic non-union make external fixator an attractive option for skeletal stabilization.

External fixators are more often useful and versatile tools for open fractures. External fixators promote soft-tissue healing, preserve the bone vascularity, accessibility to wound, and cause less blood loss. Limb reconstruction system external fixator is a better option to treat compound fracture femur because of simple procedure of application, it's good fracture stability, adjustable geometry, and lightweight and it can induce/enhance fracture healing by compression and distraction osteogenesis.

The use of LRS external fixation techniques for open femur fracture management includes;

- (a) Compression, neutralization, or fixed distraction of the fracture fragment are possible.
- (b) Early movement of the proximal and distal joints is allowed.
- (c) The method gives a stable fixation with better wound care.
- (d) Alternate compression and distraction promote callus formation.
- (e) LRS external fixator does not cause any additional disruption of soft-tissue envelope or vascularity of fracture fragments.
- (f) In LRS associated treatment can be taken as dressing, flap rotation or skin grafting, bone grafting, and irrigation.
- (g) Bone transport is possible in case of bone loss.
- (h) Stable fixation can be used in infected, acute fracture, or

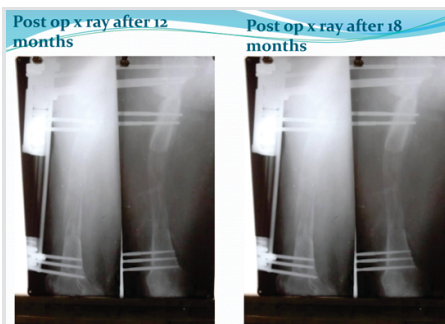


Figure 4: (a) Post-operative X-ray after 12 months. (b) Post-operative X-ray after 18 months.

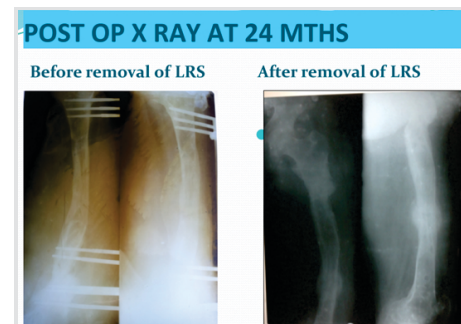


Figure 5: (a) Post-operative X-ray at 24 months. (a) Before removal of LRS, (b) after removal of LRS.

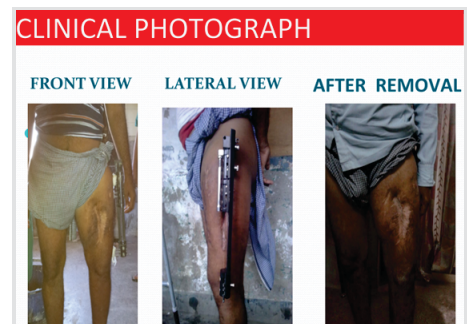

Figure 6: Clinical photograph. (a) Front view, (b) Lateral view, (c) After removal.



Table 1: Post-operative ambulation in cases of fracture shaft femur

Duration (in week)	Knee movement		Partial weight-bearing		Full weight-bearing	
	n	%	n	%	n	%
1	12	85.72	-	-	-	-
3	2	14.29	-	-	-	-
6	-	-	12	85.72	-	-
8	-	-	2	14.29	-	-
12	-	-	-	-	8	57.14
16	-	-	-	-	4	28.57
20	-	-	-	-	2	14.29
Total	14	100	14	100	14	100

non-union.

Limb reconstruction system is an assembly of clamps which can slide on a rigid rail and can be connected by compression-distraction units. The limb reconstruction system may be used to achieve 15 cm or more of lengthening without the need to change the device. It may also be used to correct deformities. In comminuted fractures with bone loss and in situations of nonunion or malunion, the LRS may be used to obtain maximum stability.

Here, the three main indications for its use are: (1) Bone loss with or without shortening, (2) deformity with or without shortening, and (3) extreme shortening.

In these situations, LRS acts through the technique of bone transport, compression distraction, partial acute shortening and transport, multifocal surgery, and bifocal lengthening.

The present study aims to evaluate the results of rail external fixator in compound fractures of middle/3rd and lower/3rd part of shaft femur.

Case Series

The study was hospital-based prospective study centered in the Department of Orthopaedics of Sarojini Naidu Medical College, Agra.

Fourteen cases from age group 20 to 70 years presenting to the outpatient and emergency department of orthopedics and fulfilling the following criteria were selected for the study.

Inclusion criteria

The following criteria were included in the study:

1. Compound diaphyseal fractures of femur.
2. Compound segmental fractures of femur.
3. Compound fracture of femur with bone loss.
4. Old compound fracture with infected non-union.

Exclusion criteria

The following criteria were excluded from the study:

1. Closed diaphyseal fractures.
2. Pathological fractures.
3. Femur fractures with intra articular extension.

The present study comprised 14 cases. Our series had patients in age ranging from 20 to 70 years. The compound fracture was most common in the age group of 31–40 (35.71%), most common in male 12 (85.72%) cases, whereas female was 2 (14.28%) cases.

The most common mode of injury was the road traffic accident constituting 85.72% of the total cases.

The right side was predominated in our series in comparison to the left side. Out of 14 cases, 7 cases had comminuted fracture and 4 cases had segmental fracture.

Among the non-union group, the infected group had 2 cases and the non-infected group had 1 case.

Associated injury was seen in 6 patients. All the patients with associated injury were the result of a road traffic accident. Out of 14 cases, 8 cases belong to the middle 3rd and 6 cases belong to the lower 3rd part of femur.

Time lapse between injury and operation varied from 1 to 28 weeks.

LRS was applied in operation theatre under epidural and/or spinal anesthesia after complete pre-operative planning.

Corticotomy was performed in 8 cases out of 14. All were bifocal and none had mono or trifocal corticotomy. Out of 8 cases, proximal corticotomy was performed in 3 cases and distal in 5 cases.

The duration of follow-up varied from 4 to 24 months. Duration of fixator application varied from 4 months to 24 months with an average period of 8–9 months.

Table 2: Rate of union

Union period (in months)	Union	
	Number of cases	Percentage
3–4	2	14.29
5–8	10	71.42
9–12	2	14.29
Total	14	100

Table 3: Radiological results

Bone results	Number of cases	Percentage
Excellent	12	85.72
Good	1	7.14
Fair	-	-
Poor	1	7.14
Total	14	100

In the majority of patients, union was achieved in 5–8 months.

Fractures with bone gap and bone loss took longer time in union and union was further delayed because of associated infection and soft-tissue injury.

The results were based on bone (radiological) results and functional results (ASAMI classification) [6].



Table 4: Functional results		
Functional results	Number of cases	Percentage
Excellent	10	71.43
Good and fair	4	28.57
Total	14	100

1. Radiological results

A. Excellent

- Union
- No infection
- Limb length discrepancy < 2.5 cm
- Deformity < 7°.

B. Good: Union + any two of the above criteria.

C. Fair: Union + any one of the above criteria.

D. Poor: Non-union or refracture

2. Functional results – 5 criteria

A. Presence of limp

B. Stiffness of the knee or the ankle

C. Pain

D. Soft-tissue sympathetic dysfunction

E. Ability to perform previous activities of daily living

a. Excellent result – A fully active individual

(b) B-Good and fair result – Progressively lesser degree of activities/mobility

Follow-up

Follow-up of the patients done at 3 weeks, 6 weeks then monthly for 6 months then at 3 months interval. The patient was observed clinically and radiologically for the following:

1. Type of fracture
2. Duration of stay in hospital
3. Initiation of mobilization
4. Physiotherapy
5. Range of movement achieved postoperatively
6. Time of union
7. Development of surgical and post-operative complications

Observations and Results

A total of 14 cases were treated by rail external fixators in the Department of Orthopaedics, S.N. Medical College, Agra.

Post-operative knee movement started within 1 week in 12

(85.72%) cases. In 2 cases (14.29%), knee movement started in the 3rd week due to associated both bone leg fracture on that side.

Partial weight-bearing was allowed in 12 cases (85.72%) in 6 weeks and 2 cases in 8 weeks because of associated pelvic fracture. Quadriceps and hamstring exercises were started within 2–3 days of operation.

Full weight-bearing allowed in 8 cases (57.14%) cases in 12 weeks and 4 (28.57%) cases in 16 weeks and in 2 cases (14.29%) in 20 weeks (Table 1).

The union ranges from 3 to 12 months but maximum union was achieved in 5–8 months in 10 (71.42%) cases (Table 2).

Excellent radiological results were present in 12 (85.72%) cases, good result in 1 (7.14%) case, and poor result in 1 (7.14%) case (Table 3).

Excellent functional results were observed in 10 cases (71.43%) and 28.57% of cases showed good and fair results (Table 4).

Discussion

The biology of compression distraction osteogenesis of bone and soft tissue is the basis of treatment using rail fixator for fracture, deformities, non-union, etc.

The basic principle of distraction osteogenesis is that bone and soft tissue can be made to generate new bone and soft tissues under condition of rhythmic distraction.

Advantage of rail fixator include less invasive surgery, early weight-bearing, less infection, less blood loss, prevention of disuse osteoporosis and atrophy, preservation of limb function, and no need for bone grafting.

Complication with other fixators like ring fixator is as follows:

- Neurovascular injury at the site of pin insertion.
- Transfixation wires may lead to trans fixation of fascia, muscles, and tendons leading to limitation of active and passive joint motion.
- Pin-tract infection is another common problem with Ilizarov technique.

The present study comprised 14 cases. Our series had patients in age ranging from 20 to 70 years with a commoner age group ranging from 31 to 40 years. Minimum age was 20 years and the maximum was 70 years.

The most common mode of injury was the road traffic accident constituting 85.72% of the total cases.

Excellent bone results were obtained in 85.72% of cases while 7.14% showed good and 7.14% of cases were poor results. Excellent functional results were observed in 71.43% of cases and 28.57% of cases shows good and fair results.

According to Ebrahim et al. [7], in compound fracture femur



treated by hybrid fixator, the radiological (bone) result was excellent in 70.5% of cases and functional results were excellent in 29.40% of cases, good in 41.20% of cases, fair in 17.60% of cases, and poor in 11.80% of cases.

In our study, compound fracture and non-union were treated by limb reconstruction system and radiological result was 85.72% and functional results were excellent in 71.43% of cases, good and fair results in 28.57% of cases.

According to Mohr et al. [8], in the open femoral fracture treated by external fixator, the late deep infection developed in 11% of cases, slightly restriction of knee movement developed in 80% of cases, and shortening of femur occurs in 7% of cases.

In our study, the complications as deep infection occurs in 7.14%, slightly restriction of knee movement occurs in 14.28%, and no shortening in our series.

In our study, there were few cases showing pin-tract infection and no loosening of pin and no breakage of pin.

In our study, no shortening was present at final follow-up. According to Marsh et al. [9], supracondylar fracture of femur treated by external fixator shortening and malalignment was present in 30.76% of cases.

The overall goal in the reconstruction of an infected united long bone fracture involves more than control of infection and includes creation of a healed aligned and drainage free limb which is functionally better than that which could have been achieved by amputation and prosthetic fitting. Several factors must be considered in reconstruction of bone including the patient's age, metabolic status, mobility of the foot and ankle, integrity of neurovascular structures, and importantly the patient's motivation. The extent of bony debridement is defined by the presence of punctate bleeding points observed. The non-union site must be resected as it is better to substitute a poorly biological atrophic bone area with two bone surfaces of good quality modeled in such a way as to allow for easy stabilization under compression. Through wound debridement and removal of the doubtful bone and soft tissues to keep the area totally devoid of non-viable tissue are essential for achieving bony union. The patient must be cooperative and understand the length of time the frame has to be worn and complications requiring pin revision are a probability. In elective situations, the patients can be made to meet other patients who have gone through this process, have pre-operative teaching and elect this treatment protocol. Patients may accept these techniques better when they have chosen it as an elective reconstruction rather than when it is inflicted on them. Patients require adequate nutrition, exercise, and encouragement to stop smoking. Although distraction osteogenesis is associated with marked improvement of the blood supply, good vascularization is necessary to obtain bone healing, especially in patients with

infected nonunion. Before the surgery, it is necessary to plan the procedure adequately. As in other series, functional results were inferior to bony results. An excellent bone results do not guarantee a good functional result [10]. The functional result is affected by the condition of the nerves, muscles, vessels, joints, and to a lesser extent bone. The non-union site united in all cases, which is comparable to the study conducted by Eduardo Garcia et al. [11] in 2004, wherein the bony union result was 86.7%. Antonio Biasibetti in his study had a success rate of 93%. Pin-tract infection occurred in 2 out of 14 cases (14.29%), which is comparable to the study conducted by Gopal et al. [12], where the reported pin-tract infection was in 10 out of 19 cases (53%). In another study by Coll, the reported pin-tract infection was 30%. Hence, the rate of pin-tract infection remained low in our study. Bone transport resulted in a better restoration of limb length discrepancy in lower limbs. Larger bone defects can be tackled with two-level corticotomies. Bone grafts can be added, after infection settles at the non-union site. Graft can also be added to the regenerate site if progression toward consolidation is slow as quoted in the literature [13].

Even though the cost of the fixator is high, the patients because of the following reasons accept it: Lightweight, patient friendly, and day-to-day activities can be done easily. The frame being uniplanar allows early mobilization of joints and acceptable patient compliance. Being rigid [14], early weight-bearing can be allowed with the device. Patients themselves can lengthen very easily. Moreover, plastic surgery procedures such as cross-leg flap, fasciocutaneous flap, and skin grafting can be done comfortably. Once the patients have been taught about how to do distraction they are advised to come for review once in 15 days to assess the length gained and also to assess the quality of the regenerate. Moreover, the fixator (other than the tapered half pins) can be reused for another patient provided that there is no damage to the apparatus. The disadvantages include the high cost of the system, inability to use the apparatus for correction of infected non-union with gross deformity, in severe osteoporosis, and stabilization very close to articular surface of a joint for which Ilizarov ring fixator is a good option. The cost factor has been reasonably managed by the introduction of Indian version of Orthofix. Compared with the Ilizarov ring fixator [15], the unilateral external fixator is simpler to apply and better tolerated by the patients. The learning curve for implementation of the unilateral fixator is less steep than that encountered with the Ilizarov fixator.

Conclusion

1. The LRS method is quite versatile and not only treats fracture but also bone loss/gap, limb length discrepancy, and deformity simultaneously.

2. The factor such as the age of the patient's, condition of bone, and soft-tissue condition is not the contraindication for the use of LRS.
 3. It does not require plaster, traction, and Thomas splint as an external support.
 4. It allows early weight-bearing and joint movements and avoids the complications of prolonged immobilization.
 5. It reduces the length of hospital stay.
 6. It does not expose the patient to an undue risk of infection or non-union, rather treats them.
 7. Reduces the incidence of malunion and secondary displacement of fracture rather treats them.
 8. Earlier appearance and good quality of regenerate were seen in patients with distal corticotomy because of the cancellous nature of bone, larger contact area, and increased vascularity of that area.
 9. Poor result was seen in one case with a stiff knee due to improper physiotherapy.
- In this study we conducted, we could achieve a success rate of

86%, giving good encouraging results to most of our patients. Hence, we conclude that the Indian version of the monolateral external fixation system is an effective and convenient method for the treatment of infected non-union of long bones. This can also be used to correct the limb length discrepancies simultaneously, which can arise during the course of the treatment. Patients with poor cooperation are not good candidates for this technique, which requires wearing the frame for a long time, with probably additional secondary surgical procedures.

Clinical Message

For patients with infected non-union and massive bone loss, limb reconstruction system is an ideal treatment option because of simple method of application, its good stability, adjustable geometry, and lightweight and it can induce/enhance fracture healing by compression and distraction osteogenesis.

References

1. Wenger DR. Campbell's Operative Orthopaedics. 10th ed., Vol. 3. Philadelphia, PA: Lippincott Williams and Wilkins; 2003. p. 2706-14.
2. Mahaluxmivala J, Nadarajah R. Ilizarov external fixator: Acute shortening and lengthening versus bone transport in the management of tibial non-unions. *Injury* 2005;36:662-8.
3. Chapman MW. Chapman's Orthopaedic Surgery. 3rd ed., Ch. 26. Philadelphia, PA: Lippincott Williams and Wilkins; 2001.
4. Ruedi TP, Murphy WM. AO Principles of Fracture Management. New York: Thieme Publishing Group; 2000.
5. Jain AK, Sinha S. Infected nonunion of the long bones. *Clin Orthop Relat Res* 2005;431:57-65.
6. Association for the Study and Application of Ilizarov's Method. Operative Principles of Ilizarov: Fracture Treatment, Nonunion, Osteomyelitis, Lengthening, Deformity Correction. Baltimore, MD: Lippincott Williams and Wilkins Company; 1991. p. 42-52.
7. Hassankhani EG, Birjandinejad A, Kashani FO, Hassankhani GG. Hybrid external fixation for open severe comminuted fractures of the distal femur. *Surg Sci* 2013;4:176-83.
8. Mohr VD, Eickhoff U, Haaker R, Klammer HL. External fixation of open femoral shaft fractures. *J Trauma* 1995;38:648-52.
9. Marsh JL, Jansen H, Yoong HK, Found EM Jr. Supracondylar fracture of femur treated by external fixator. *J Orthop Trauma* 1997;11:405-10.
10. Dendrinis GK, Kontos S. Use of the Ilizarov technique for treatment of non-union of the tibia associated with infection. *J Bone Joint Surg Am* 1995;77:835-46.
11. García-Cimbrelo E, Martí-González JC. Circular external fixation in tibial nonunions. *Clin Orthop Relat Res* 2004;419:65-70.
12. Gopal S, Majumder S. Fix and flap: The radical orthopaedic and plastic treatment of severe open fractures of the tibia. *J Bone Joint Surg Br* 2000;82:959-66.
13. Biasibetti A, Aloj D. Mechanical and biological treatment of long bone non-unions. *Injury* 2005;36:S45-50.
14. Chao EY, Hein TJ. Mechanical performance of the standard Orthofix external fixator. *Orthopedics* 1988;11:1057-69.
15. Sangkaew C. Distraction osteogenesis for the treatment of post traumatic complications using a conventional external fixator. A novel technique. *Injury* 2005;36:185-93.

Conflict of Interest: Nil
Source of Support: Nil

Consent: The authors confirm that informed consent was obtained from the patient for publication of this case report

How to Cite this Article

Chahar HS, Gupta M, Kumar V, Yadav R, Patel J, Pal CP. Prospective Evaluation of Role of Limb Reconstruction System (Rail External Fixator) in Open Fractures and Infected Non-union of Femur. Journal of Orthopaedic Case Reports 2021 January;11(1):5-11.

