



Contents lists available at ScienceDirect

## International Journal of Surgery Case Reports

journal homepage: [www.casereports.com](http://www.casereports.com)

## An unusual case of left hepatectomy for Focal Nodular Hyperplasia (FNH) linked to the use of Anabolic Androgenic Steroids (AASs)



Angela Romano\*, Michele Grassia, Giuseppe Esposito, Marianna Petrillo, Modestino Pezzella, Francesco Maria Romano, Francesco Esposito, Francesco Torelli, Natale Di Martino

Department of general surgery, Second University of Naples, Italy

## ARTICLE INFO

## Article history:

Received 4 September 2016  
Received in revised form 29 October 2016  
Accepted 29 October 2016  
Available online 3 November 2016

## Keywords:

Focal nodular hyperplasia (FNH)  
Anabolic androgenic steroids (AASs)  
Left hepatectomy  
Case report

## ABSTRACT

**INTRODUCTION:** Focal Nodular Hyperplasia (FNH) is the second most common benign tumor of the liver. Clinically FNH is asymptomatic and discovered incidentally. The pathogenesis is unclear; FNH is usually asymptomatic. When the tumor is large, it may be painful. Surgery is recommended only in the case of complications such as compression of adjacent organs, lesion progression with tumor size >5 cm and presence of symptoms. Presentation of case: A 30 years old man, was evaluated during a routine visit, for diffuse abdominal pain and weight loss; Abdominal ultrasound showed no evidence of biliary obstruction but the US shows a hypoechoic, well defined focal lesion in the left liver. For a more accurate diagnosis a Magnetic Resonance detected a focal area about 14 × 9 cm in diameter, hypointense. Liver biopsy was not done. We could not diagnose it definitively as FNH from the results of imaging studies; so for the size of symptomatic lesion, the undefined diagnosis of FNH, and due to the great increase in the size of the mass located in the left lobe, during such a short period, the surgery was been recommended.

**DISCUSSION:** FNH is the second most common hepatic lesion, but clinically relevant cases of FNH are rare with a reported prevalence in US studies of 0,03%. In our case the young patient was taking dietary supplements including anabolic androgenic steroids (AASs), carnitine and L-arginine.

**CONCLUSION:** The particularity of our case is the increasing of the lesion in two years in which the patient made use of anabolic steroids. under use of. This could be the explanation for increasing of nodule.

© 2016 The Authors. Published by Elsevier Ltd on behalf of IJS Publishing Group Ltd. This is an open access article under the CC BY-NC-ND license (<http://creativecommons.org/licenses/by-nc-nd/4.0/>).

### 1. Introduction

Focal Nodular Hyperplasia (FNH) is the second most common benign tumor of the liver [1], with an incidence of approximately 3–5% in general population and higher prevalence in woman 12:1 [2,3]. FNH is more common in premenopausal women although up to 10% may occur in males [4,5]. Clinically FNH is asymptomatic and discovered incidentally in 80% of cases [6]; the development of focal nodular hyperplasia is caused by an injury to the portal tract resulting in the formation and enlargement of arterial to venous shunt [7]. This in turn causes hyperperfusion in local arteries resulting in oxidative stress that triggers a response from hepatic stellate cells to produce the central scar typically seen in cases of FNH [8,9].

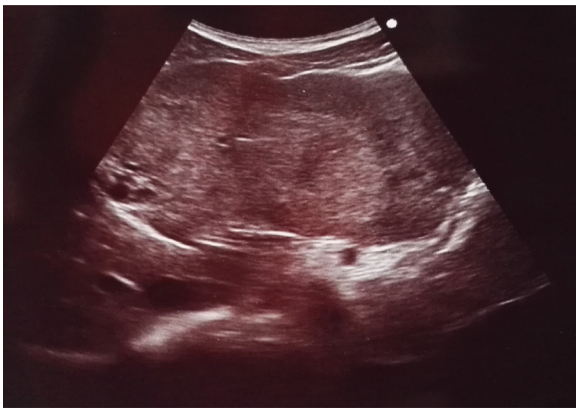
One confirmed, FNH is usually treated conservatively, indications for surgery include: progressive disease, increasing pain and a lesion for which malignancy cannot be ruled out [10]. We present the case of a young man with FNH in which the evolution of liver lesion it could be associated with the use of anabolic androgenic steroids (AASs).

### 2. Presentation of case

A 30 years old man, was evaluated during a routine visit, for diffuse abdominal pain and weight loss; He had no history of liver disease or risk factors for viral hepatitis and took no other medications. On examination he had an enlarged liver but no rash, fever or splenomegaly. Abdominal ultrasound showed no evidence of biliary obstruction but the US shows a hypoechoic, well defined 14 × 10 cm, focal lesion in the left liver. Completely blood tests have been done, all the results being in normal ranges. For a more accurate diagnosis a Magnetic Resonance detected a focal area about 14 × 9 cm in diameter, hypointense on diffusion weighted images. Liver biopsy was not done. We could not diagnose it definitively as FNH from the results of imaging studies; so for the size

\* Corresponding author.

E-mail addresses: [angelaromano\\_ar@libero.it](mailto:angelaromano_ar@libero.it) (A. Romano), [michelegrassia@live.it](mailto:michelegrassia@live.it) (M. Grassia), [g-expo@libero.it](mailto:g-expo@libero.it) (G. Esposito), [mariannapetrillo@virgilio.it](mailto:mariannapetrillo@virgilio.it) (M. Petrillo), [ninopezze@gmail.com](mailto:ninopezze@gmail.com) (M. Pezzella), [damonevic32@gmail.com](mailto:damonevic32@gmail.com) (F.M. Romano), [francescodottesposito@gmail.com](mailto:francescodottesposito@gmail.com) (F. Esposito), [francesco.torelli@unina2.it](mailto:francesco.torelli@unina2.it) (F. Torelli), [natale.dimartino@unina2.it](mailto:natale.dimartino@unina2.it) (N. Di Martino).

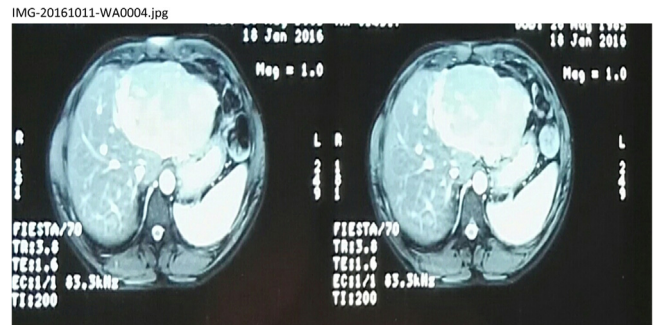


**Fig. 1.** US shows a hypoechoic, well defined 14 × 10 cm, focal lesion in the left liver.

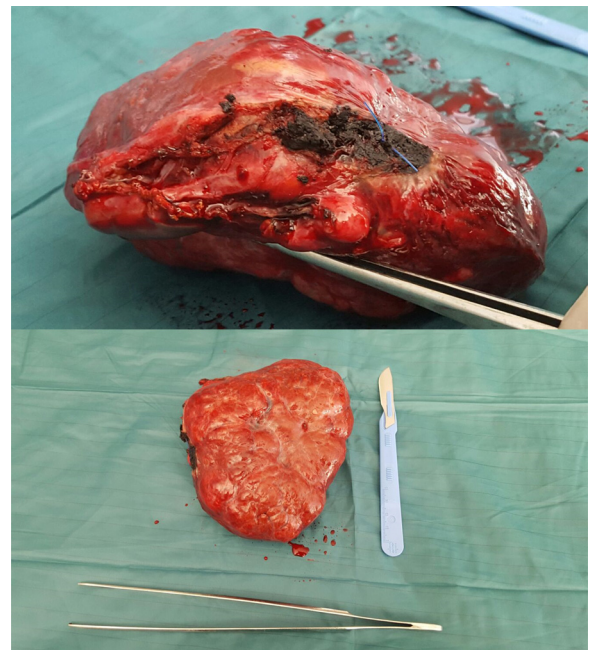
of symptomatic lesion, the undefined diagnosis of FNH, and due to the great increase in the size of the mass located in the left lobe, during such a short period (2 years), the surgery was recommended. The surgical procedure involved the resection of the II, III and IV liver segments. The surgical specimen measured 14.0 cm × 12.0 cm × 6.5 cm. Pathologic examination at that time revealed that it was composed of mature hepatocytes, ductal reaction and abnormal vessels, so it was FNH histologically, without a central scar. Surgical procedure and postoperative course were uneventful and the patient was discharged from the hospital on postoperative day 6 (Fig. 1).

### 3. Discussion

FNH is the second most common hepatic lesion, but clinically relevant cases of FNH are rare with a reported prevalence in US studies of 0.03% [11]. The pathogenesis is unclear, Kondo [12] has proposed that FNH are a result of regional abnormalities in either portal or hepatic arterial blood flow, so the development of focal nodular hyperplasia is caused by an injury to the portal tract. It is hypothesized that focal circulatory disturbance may cause arterial and portal venous thrombosis, and that vascular recanalization and reperfusion of hepatic tissue might lead to hepatocyte proliferation and the development of FNH. In our case the young patient was taking several herbal products and dietary supplements including anabolic androgenic steroids (AASs), carnitine and L-arginine, which is the precursor for the synthesis of nitric oxide (NO), an endogenous mediator of vasodilatation process. The liver is morphologically and functionally modulated by sex hormones so the long-term use of oral contraceptives (OCs) and anabolic androgenic steroids (AASs) may cause changes of the liver tissue. The NO synthesis is stimulated by several factors such as “shear stress”, a parameter which measures the force exerted by blood flow in the vessels when this increases the body defends itself by producing NO. Etiology is still not known but it seems that the trigger event is usually a vascular malformation. Due to an arterial hyperperfusion, an hyperoxic condition can activate hepatic stellate cells and VEGF, activated by increase oxygen tension, may influence the proliferation of abnormal vessels [9]. Generally, it is easier to observe the central scar and other characteristics as vascular abnormalities in lesions larger than 3 cm. In smaller lesions, these features are less obvious and may be absent in up to 70% of cases [13]. The particularity of our case resides in the increasing of the lesion in two years in which the patient made use of anabolic steroids. Hormonal conditioning of these lesions is known, under use of oral anabolic steroids being proved the increase in volume of FNH. This could be the explanation for increasing of nodule. In our case we could not diagnose it definitively as FNH from the results of imaging studies;



**Fig. 2.** Magnetic Resonance detected a focal area about 14 × 9 cm in diameter, hypointense on diffusion weighted images.



**Fig. 3.** Intraoperative findings. The surgical specimen measured 14.0 cm × 12.0 cm × 6.5 cm.

the use of biopsy in the diagnosis of hypervascular hepatic lesions is controversial. We believe that the role of biopsy is to confirm benign pathology in patients with radiologically benign appearing lesions [14,15]. Because of benign evolution, therapeutic abstention is currently recommended if the diagnosis of FNH is established with certainty. This attitude is justified by exceptional complications and no risk of cancer. FNH is usually asymptomatic. When the tumor is large, it may be painful Fig. 2. Surgery is recommended only in the case of complications such as compression of adjacent organs, lesion progression with tumor size >5 cm and presence of symptoms [16–18] Fig. 3.

### 4. Conclusion

Based on our experience, once diagnosed, FNH should be managed with regular follow up, especially if you use hormones, because although the correlation is not proven, the role of hormonal milieu is still strongly supported in influencing the development of FNH, confirmed by the fact that the diagnosis is extremely rare in postmenopausal women [19]. There are a few reports linking FNH to use of anabolic androgens [20] and this case underlines the importance of regular liver surveillance in patients with FNH that use anabolic androgenic steroids for a long time.

**Conflicts of interest**

None.

**Funding**

None.

**Ethical approval**

None.

**Consent**

Written informed consent was obtained from the patient for publication of this case report and accompanying images. A copy of the written consent is available for review by the Editor-in-Chief of this journal on request.

**Author contribution**

Angela Romano: participated substantially in conception, design, and execution of the study and in the analysis and interpretation of data; also participated substantially in the drafting and editing of the manuscript.

Michele Grassia: participated substantially in conception, design, and execution of the study and in the analysis and interpretation of data; also participated substantially in the drafting and editing of the manuscript.

Giuseppe Esposito: participated substantially in conception, design, and execution of the study and in the analysis and interpretation of data.

Marianna Petrillo: participated substantially in conception, design, and execution of the study and in the analysis and interpretation of data.

Modestino Pezzella: participated substantially in conception, design, and execution of the study and in the analysis and interpretation of data.

Francesco Maria Romano: participated substantially in conception, design, and execution of the study and in the analysis and interpretation of data.

Francesco Esposito: participated substantially in conception, design, and execution of the study and in the analysis and interpretation of data.

Francesco Torelli: participated substantially in conception, design, and execution of the study and in the analysis and interpretation of data.

Natale Di Martino: participated substantially in conception, design, and execution of the study and in the analysis and interpretation of data; also participated substantially in the drafting and editing of the manuscript.

**Guarantor**

Prof. Natale Di Martino.

**References**

- [1] P.J. Karhunen, Benign hepatic tumours and tumour like conditions in men, *J. Clin. Pathol.* 39 (1986) 183–188.
- [2] T.K. Kim, H.J. Jang, P.N. Burns, J. Murphy-Lavallee, S.R. Wilson, Focal nodular hyperplasia and hepatic adenoma: differentiation with low-mechanical-index contrast-enhanced sonography, *AJR Am. J. Roentgenol.* 190 (2008) 58–66.
- [3] P. Herman, V. Pugliese, M.A. Machado, A.L. Montagnini, M.Z. Salem, T. Bacchella, L.A. D'Albuquerque, W.A. Saad, M.C. Machado, H.W. Pinotti, Hepatic adenoma and focal nodular hyperplasia: differential diagnosis and treatment, *World J. Surg.* 24 (2000) 372–376.
- [4] D. Cherqui, A. Rahmouni, F. Charlotte, H. Boulahdour, J.-M. Metreau, M. Meignan, et al., Management of focal nodular hyperplasia and hepatocellular adenoma in young women: a series of 41 patients with clinical, radiological, and pathological correlations, *Hepatology* 22 (1995) 1674–1681.
- [5] I. Di Carlo, E. Pulvirenti, A. Toro, G.D. Priolo, Adenoma or atypical hepatic focal nodular hyperplasia: role of preoperative imaging and laparoscopic treatment, *Surg. Laparosc. Endosc. Percutan. Tech.* 20 (2010) e105–e109.
- [6] I.R. Wanless, H. Sapp, M. Guindy, et al., Pathogenesis of focal nodular hyperplasia: an hypothesis based on histologic review of 20 lesions including 3 occurring in early biliary cirrhosis, *Hepatology* 44 (2006) 491a.
- [7] O. Shaked, E.S. Siegelman, K. Oltho, et al., Biologic and clinical features of benign solid and cystic lesions of the liver, *Clin. Gastroenterol. Hepatol.* 62 (2011) e1–e4.
- [8] Y. Sato, K. Harada, H. Ikeda, et al., Hepatic stellate cells are activated around central scars of focal nodular hyperplasia of the liver—a potential mechanism of central scar formation, *Hum. Pathol.* 40 (2009) 181–188.
- [9] G.K. Bonney, D. Gomez, A. Al-Mukhtar, G.J. Toogood, J.P. Lodge, R. Prasad, Indication for treatment and long-term outcome of focal nodular hyperplasia, *HPB (Oxford)* 9 (2007) 368–372.
- [10] L. Buscarini, F. Fornari, G. Civardi, et al., Laparoscopy integrates ultrasound and ultrasound guided biopsy for diagnosis of benign liver tumors, *Acta Endoscopica* 23 (1993) 27–36.
- [11] F. Kondo, Benign nodular hepatocellular lesions caused by abnormal hepatic circulation: etiologic analysis and introduction of a new concept, *J. Gastroenterol. Hepatol.* 16 (2001) 1319–1328.
- [12] A. Blachar, M.P. Federle, J.V. Ferris, J.M. Lacomis, J.S. Waltz, D.R. Armfield, G. Chu, O. Almusa, L. Grazioli, E. Balzano, W. Li, Radiologists' performance in the diagnosis of liver tumors with central scars by using specific CT criteria, *Radiology* 223 (2) (2016) 532–539 (PMID: 11997564).
- [13] D.L. Shawcross, N. Naoumov, I. Pachiadakis, C. Mamais, R. Williams, R. Jalan, et al., Should a biopsy precede liver resection or transplantation for presumed hepatocellular carcinoma when the alpha fetoprotein is normal, *Transplantation* 77 (2004) 637–638.
- [14] F. Durand, J.M. Regimbeau, J. Belghiti, A. Sauvanet, V. Vilgrain, B. Terris, et al., Assessment of the benefits and risks of percutaneous biopsy before surgical resection of hepatocellular carcinoma, *J. Hepatol.* 35 (2001) 254.
- [15] D. Dimitroulis, P. Charalampoudis, P. Lainas, I.G. Papanikolaou, S. Kykalos, G. Kouraklis, Focal nodular hyperplasia and hepatocellular adenoma: current Review, *Acta Chir. Belg.* 113 (3) (2016) 162–169 (2013 May-Jun).
- [16] A. Durczynski, P. Hogendorf, D. Szymaniski, S. Sporny, J. Strzelczyk, Synchronous occurrence of multiple focal nodular hyperplasia and huge hepatic perivascular epithelioid cells tumor (PEComa) in young woman after oral contraceptive use is there a common pathogenesis? *Pol. Przegl. Chir.* 84 (9) (2016) 457–460 (2012 Sep).
- [17] N. Kapp, K.M. Curtis, Hormonal contraceptive use among women with liver tumors: a systematic review, *Contraception* 80 (2009) 387–390.
- [18] H.A. Edmondson, T.B. Reynolds, B. Henderson, et al., Regression of liver cell adenomas associated with oral contraceptives, *Ann. Intern. Med.* 86 (1977) 180–182.
- [19] J.J. Alberti-Flor, M. Iskandarani, L. Jeffers, Zeppar, Schiff E: Focal nodular hyperplasia associated with the use of a synthetic anabolic androgen, *Am. J. Gastroenterol.* 79 (1984) 150–151.
- [20] J. Bartley, C. Lodenkemper, J. Lange, S. Mechsner, C. Radke, P. Neuhaus, et al., Hepatocellular adenoma and focal nodular hyperplasia after long-term use of danazol for endometriosis: a case report, *Arch Gynecol. Obstet.* 269 (2004) 290–293.

**Open Access**

This article is published Open Access at [sciencedirect.com](https://www.sciencedirect.com). It is distributed under the [IJSCR Supplemental terms and conditions](#), which permits unrestricted non commercial use, distribution, and reproduction in any medium, provided the original authors and source are credited.