

Received: 2021.02.26

Accepted: 2021.08.05

Available online: 2021.08.11

Published: 2021.11.02

Outcomes from the Use of Perioperative Extracorporeal Membrane Oxygenation in Patients Undergoing Thoracic Surgery: An 8-Year Single-Center Experience

Authors' Contribution:
Study Design A
Data Collection B
Statistical Analysis C
Data Interpretation D
Manuscript Preparation E
Literature Search F
Funds Collection G

ABDEF 1 **Weizhao Huang**
ACF 1 **Hongyu Ye**
AF 2 **Zhou Cheng**
BF 2 **Xiaozu Liao**
BCD 2 **Liqiang Wang**
CDF 2 **Binfei Li**
DFG 1 **Yi Liang**
DEFG 1 **Haiming Jiang**

1 Department of Cardiothoracic Surgery, Zhongshan Hospital of Sun Yat-Sen University (Zhongshan People's Hospital), Zhongshan, Guangdong, PR China
2 Department of Anesthesiology, Zhongshan Hospital of Sun Yat-Sen University (Zhongshan City People's Hospital), Zhongshan, Guangdong, PR China

Corresponding Author: Yi Liang, e-mail: zsliangyi@yeah.net
Financial support: Project approved by Zhongshan Science and Technology Bureau (NO. 2020B1041)
Conflict of interest: None declared

Background: Extracorporeal membrane oxygenation (ECMO) plays an important role in thoracic surgery. This retrospective study from a single center aimed to evaluate patient outcomes from the use of perioperative ECMO in 22 patients undergoing thoracic surgery during an 8-year period.


Material/Methods: Data were collected retrospectively from 22 patients who received ECMO (veno-arterial and veno-venous ECMO) as perioperative treatment during general thoracic surgery from January 2012 to October 2020. Patients required ECMO due to perioperative cardiopulmonary resuscitation (CPR) (2 cases), perioperative pulmonary embolism (PE) (2 cases), lung transplant (4 cases), undergoing complicated thoracic surgery (5 cases), postoperative acute respiratory distress syndrome (ARDS) (6 cases), and thoracic trauma (3 cases).

Results: Veno-arterial ECMO was used for circulatory support in 13 cases and veno-venous ECMO was used for respiratory support in 9 cases. The average ECMO support time was 71.6 ± 42.4 h. Twenty patients (90.9%) were successfully decannulated and 17 (77.2%) survived to discharge. Complications included severe hemorrhage (3/22 patients, 13.6%), sepsis (3/22, 13.6%), and destruction of blood cells (1/22, 4.5%). There were no significant differences in survival rates between patients receiving pre- or postoperative ECMO ($P=0.135$) or between veno-venous ECMO (V-V ECMO) and veno-arterial ECMO (V-A ECMO) ($P=0.550$).

Conclusions: The findings from this small retrospective study from a single center showed that perioperative ECMO improved cardiac and respiratory function in patients undergoing thoracic surgery. Optimal results require surgeons to have an understanding of the indications and ability to control the complications of ECMO.

Keywords: **Cardiopulmonary Resuscitation • Extracorporeal Membrane Oxygenation • Thoracic Surgery**

Full-text PDF: <https://www.medscimonit.com/abstract/index/idArt/931842>

 2387

 2

 4

 24



Background

Extracorporeal membrane oxygenation (ECMO) is primarily used as temporary cardiopulmonary support to maintain oxygenation and organ perfusion. It is the most common method of sustaining life support in China [1]. Although ECMO was implemented late in China compared with the rest of the world, there has been great progress in recent years and the technique has become an important aspect of treatment for severe diseases [1]. ECMO plays an important role in thoracic surgery; either patients with thoracic surgery need to use ECMO as a support and rescue measures [2,3], or patients with ECMO need to accept thoracic surgical services to manage the challenging life-threatening complications [4]. V-V ECMO is the most frequently used extracorporeal life support (ECLS) technique in thoracic surgery [3]. In fact, V-V ECMO is the criterion standard for severe and refractory adult respiratory failure and V-A ECMO is the technique that is used to support cardiorespiratory failure [5]. At present, the indications and methods of ECMO in management guidelines for thoracic surgery are still controversial [5,6]. Therefore, this retrospective study from a single center aimed to evaluate patient outcomes from the use of perioperative ECMO in 22 patients undergoing thoracic surgery at a single center between January 2012 to October 2020.

Material and Methods

Ethics Statement

We obtained informed consent from all the subjects' guardians to take part in the study. The study followed the rules of and was approved by the Medical Ethics Committee of Zhongshan Hospital affiliated to Sun Yat-sen University.

Patient Characteristics

We retrospectively analyzed the clinical data of patients who underwent general thoracic surgery with ECMO from January 2012 to October 2020 in our center. All procedures were performed and cases managed by the same ECMO team (involving the same surgeons and anesthesiologists).

Indications for Extracorporeal Membrane Oxygenation

At our center, indications for ECMO are as follows: routine cardiopulmonary resuscitation carried out for 10 min with no return to spontaneous circulation (ROSC) requiring ECMO-assisted cardiopulmonary resuscitation (E-CPR) to be started immediately, hemodynamic instability in a patient with diagnosed PE, poor pulmonary function and inability to tolerate single-lung ventilation in a patient who has received a lung transplant,

difficulty and high-risk intubation, and inability to tolerate single-lung ventilation following complicated thoracic surgery.

Indications for ECMO among patients with acute respiratory distress syndrome (ARDS) were: pure oxygen condition with an oxygenation index (PaO₂/FiO₂) of <100 or alveolar arterial oxygen pressure difference of >600 mmHg (1 mmHg=0.133 kPa), Murray lung injury score of ≥3 points, pH of <7.2, age <65 years, and traditional mechanical ventilation time of <7 days [5,7].

Indications for ECMO among patients with chest trauma and severe lung or airway damage were: inability of conventional mechanical ventilation to maintain ventilation and effective oxygenation.

Establishment Method

According to the routine method of the center [8], cannulation was performed by an experienced ECMO team and was often carried out at the bedside. All patients underwent peripheral cannulation. In those who required cardiopulmonary support, V-A ECMO was chosen and was initiated using cannulas (Medtronic, Inc., USA) placed in the right femoral artery and vein via a 4-cm incision. After arterial cannulation, the distal branch was inserted to enable lower-limb perfusion. Pulmonary support was provided via V-V ECMO through percutaneous cannulation placed in the right internal jugular and right femoral veins guide by ultrasound. The ECMO perfusion system consisted of a centrifugal pump (Medtronic, Inc., USA) and a temperature controller (Stocker, Inc., Germany). The ECMO pre-filled liquid was subjected to ECMO pre-filling and exhausting through the administration of a multiple-electrolyte injection (1000 ml) (ICU Medical Sales, Inc., USA). The system was heparinized (1 mg/kg/h) simultaneously and the activated clotting time (ACT) was monitored at 180-200 s.

Process Management

Early patients were moderately sedated, blood volume was supplemented, and hemoglobin maintained at 100-120 g/L, and excessive infusion of crystalloid avoided to prevent tissue edema. Cardiac function was monitored by echocardiography every day. The insulated temperature controller was used to maintain body temperature at 36-37°C and the oxygenator (Medtronic, Inc., USA) inhaled oxygen concentration was 60%. Heparin anticoagulation was used and the ACT maintained at 180-200 s. The ECMO flow rate was set at 50-60 mL/kg/min. During ECMO, the amount of positive inotropic drugs administered was reduced according to blood pressure and heart rate. The mechanical-assisted ventilation mode used was volume control (VC) or synchronous intermittent mandatory ventilation (SIMV) with pressure support and the following settings: respiratory rate, 6-10 breaths per min; tidal volume, 6-10 ml/kg;

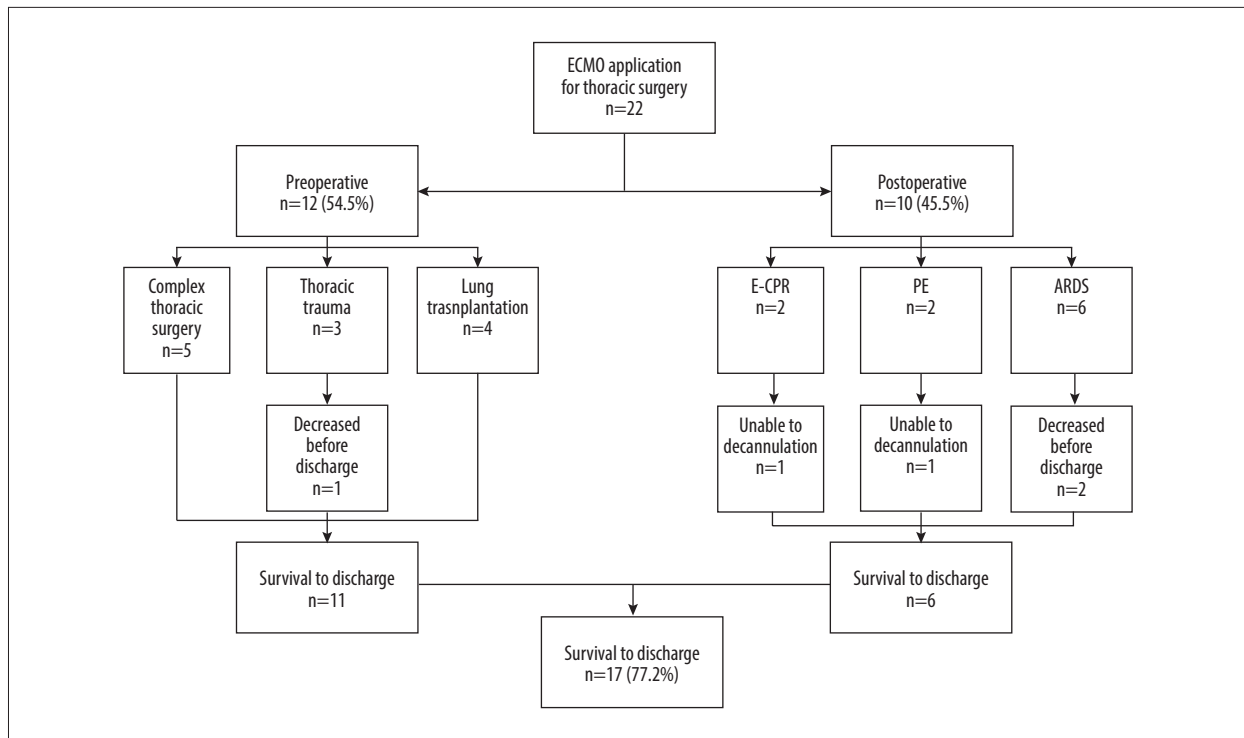


Figure 1. Flow diagram of study recruitment and survival to hospital discharge.

inhaled gas oxygen concentration, 40-50%; peak pressure, 20 cm H₂O (1 cm H₂O=0.098 kPa), avoiding positive end-expiratory pressure (PEEP) and excessive end-expiratory positive pressure (≤ 8 mmHg) [9]. For patients with ARDS, the mechanical ventilation setting parameters were as follows: tidal volume, 4-8 mL/kg; expiratory pressure, 10 mmHg; respiratory rate, 10 per min; FIO₂, and 30% in order to achieve pulmonary protection [10]. The Extracorporeal Life Support Organization (ELSO) recommends mechanical ventilation peak airway pressure be maintained at below 25 cm H₂O, PEEP at 5-15 cm H₂O, and fraction of inspired (FIO₂) at 0.3 [11].

After the patient could breathe independently and was determined to be mentally stable, the tracheal tube was removed and enteral nutrition was initiated. Routine daily echocardiography and chest X-ray examinations were performed to evaluate cardiopulmonary function. Biochemical indicators were evaluated and platelet count was maintained at $>50 \times 10^9/L$. Respiratory management was maintained and limb temperature and skin tone were monitored. To prevent lower-limb ischemia, a 14-G central venous catheter was inserted into the distal femoral artery as a bypass connecting the distal artery to the femoral cannula. The respiratory and circulatory functions of patients were evaluated during ECMO by analyzing echocardiograms, vasoactive drug dosage, ECMO parameters, hemodynamic parameters, blood gas results, and blood biochemical indicators. To cease ECMO, the flow rate was gradually reduced until it reached 0.5 L/min, and the patient was

observed for 30 min. Decannulation was considered feasible if the patient's circulation was stable.

Statistical Analysis

Statistical analyses were performed using SPSS 16.0 (Chicago, Illinois, USA). The comparison of the quantitative data between the 2 groups was performed via t-test or t'test, depending on its distribution. The differences in constituent ratio among various groups were compared via Fisher's exact test, and univariate correlation analysis was conducted according to the Spearman method. Multiple longitudinal comparisons of parameters between survivors and nonsurvivors were made by 2-way repeated-measures analysis of variance to test the influence of time on the variables. When a difference was detected, LSD method was used to adjust for multiple comparisons. All *P* values were 2-sided and considered statistically significant at *P*<0.05.

Results

Outcomes and Complications

In total, we retrospectively recruited 22 patients for the study, including 13 receiving V-V ECMO and 9 receiving V-A ECMO. The mean time of ECMO support was 71.7 ± 42.4 (range: 3-201) h. Of the total study population, 20 patients (90.9%) were

Table 1. Characteristics and outcomes of patients receiving extracorporeal membrane oxygenation.

Case	Gender	Age	Indication for ECMO	SOFA score	Mode of ECMO	Support duration (hours)	Successful removal	Survived to discharge	Main complication
1	Male	32	E-CPR	12	V-A	35	Yes	Yes	
2	Female	45	E-CPR	13	V-A	82	No	No	Destruction of blood cells
3	Male	49	PE	9	V-A	53	No	No	Severe cerebral and gastrointestinal hemorrhage
4	Female	56	PE	8	V-A	46	Yes	Yes	
5	Male	65	Lung transplantation	6	V-V	70	Yes	Yes	
6	Male	63	Lung transplantation	4	V-A	4	Yes	Yes	
7	Female	26	Lung transplantation	4	V-A	45	Yes	Yes	Severe hemorrhage (second operation)
8	Male	47	Lung transplantation	4	V-A	25	Yes	Yes	
9	Male	36	Complicated thoracic surgery	3	V-V	4	Yes	Yes	
10	Male	58	Complicated thoracic surgery	2	V-A	3	Yes	Yes	
11	Male	43	Complicated thoracic surgery	6	V-V	3	Yes	Yes	
12	Female	62	Complicated thoracic surgery	3	V-V	4	Yes	Yes	
13	Female	28	Complicated thoracic surgery	4	V-V	71	Yes	Yes	
14	Male	44	Postoperative ARDS	4	V-V	126	Yes	Yes	
15	Male	54	Postoperative ARDS	13	V-V	133	Yes	No	Severe infection
16	Male	48	Postoperative ARDS	1	V-V	154	Yes	No	Severe infection
17	Male	41	Postoperative ARDS	6	V-V	201	Yes	Yes	
18	Male	46	Postoperative ARDS	4	V-V	105	Yes	Yes	
19	Male	57	Postoperative ARDS	5	V-V	91	Yes	Yes	
20	Male	50	Severe chest trauma	7	V-A	106	Yes	Yes	Severe thoracic hemorrhage relieved by reducing ACT
21	Female	43	Severe chest trauma	5	V-V	132	Yes	No	Severe infection
22	Male	49	Severe chest trauma	8	V-V	83	Yes	Yes	

ECMO – extracorporeal membrane oxygenation; PE – pulmonary embolism; V-A – veno-arterial; V-V – veno-venous; E-CPR – extracorporeal-membrane-oxygenation-assisted cardiopulmonary resuscitation; ARDS – acute respiratory distress syndrome.

Table 2. Survival rate according to timing and mode of extracorporeal membrane oxygenation.

Factors	Case	Survived		P-value
		Yes	No	
Timing				0.135
Preoperative	12	11	1	
Postoperative	10	6	4	
Mode				0.550
V-V ECMO	13	11	2	
V-A ECMO	9	7	2	

V-V ECMO – veno-venous extracorporeal membrane oxygenation; V-A ECMO – veno-arterial extracorporeal membrane oxygenation.

successfully decannulated. The 2 cases in which ECMO could not be removed successfully were a patient who had undergone extracorporeal cardiopulmonary resuscitation (severe destruction of the blood cells and poor function of the central nervous system due to hypoxic ischemic encephalopathy prevented removal of ECMO), and the other patient had PE and died of circulatory failure due to serious cerebral and gastrointestinal hemorrhage.

There were 5 in-hospital deaths (22.7% of the study population), including the 2 cases described above, 2 cases of postoperative ARDS, and 1 case of chest trauma. The survival rate was 77.2% (Figure 1).

The most prevalent complications were severe hemorrhage (3 cases, 13.6%), severe infection (3 cases, 13.6%), and severe destruction of the blood cells (1 case, 4.5%). One patient (4.5%) who had undergone lung transplantation required secondary surgery for hemorrhage of the pulmonary artery anastomosis. See Table 1 for details.

Twelve patients (54.5%) received preoperative ECMO and 10 (45.5%) received postoperative ECMO. The preoperative group included cases of lung transplantation, chest trauma, and other complex chest operations. The perioperative period included 1 case who had undergone lung transplantation and experienced serious hemorrhage requiring secondary surgery to achieve hemostasis, 1 case of chest trauma who experienced serious bleeding relieved by decreasing heparin dosage and maintaining ACT at 150-160 s, and 1 case of chest trauma who died of sepsis. There were no significant differences in survival rate between patients receiving pre- or postoperative ECMO or between V-V ECMO and V-A ECMO (Table 2).

Typical Cases

Case 4, a 56-year-old woman with a mediastinal tumor, suffered sudden cardiac arrest on postoperative day 3. After continuous bedside cardiopulmonary resuscitation for 15 min, the

patient failed to return to spontaneous circulation. Immediately, E-CPR was started and ECMO was established 35 min after cardiac arrest, which resulted in the recovery of independent heartbeat and stabilization of circulation. Computed tomography angiography (CTA) revealed acute pulmonary embolism, and emergency pulmonary embolectomy was performed. The ECMO was removed the day after surgery, and the patient recovered well and was discharged (Figure 2).

Case 13 was a 28-year-old woman who was admitted for repeated hemoptysis occurring over 2 years. After admission, she suffered massive hemoptysis with gradual decrease of the oxygenation index. The patient was intubated, but respirator ventilation was unsuccessful due to blockage by blood clots. Immediately, V-V ECMO support was given, resulting in the recovery of oxygenation and stabilization of circulation. Bronchoscopy and right upper lung sleeve resection and thrombectomy were successfully performed under the support of ECMO (Figures 3, 4).

Discussion

Extracorporeal membrane oxygenation is a method of short-term life support, which has rapidly become important in the fields of emergency medicine, heart surgery, respiratory medicine, intensive care, organ transplantation, and other cardiopulmonary-related fields [12]. In recent years, the use of ECMO has increased in perioperative care of general thoracic surgery. The main indications for ECMO are clinical conditions requiring short-term respiratory and/or circulatory support including clinical status when the patient cannot tolerate surgery or conventional methods fail to maintain life until effective treatment can be carried out. Although ECMO does not directly treat the disease, it can provide short-term cardiopulmonary support in the field of general thoracic medicine, achieving sufficient life support to enable diagnosis and treatment. In this study, we divided the patients into 2 groups: 'preoperative' and 'postoperative' ECMO. Preoperative ECMO mainly referred to the use

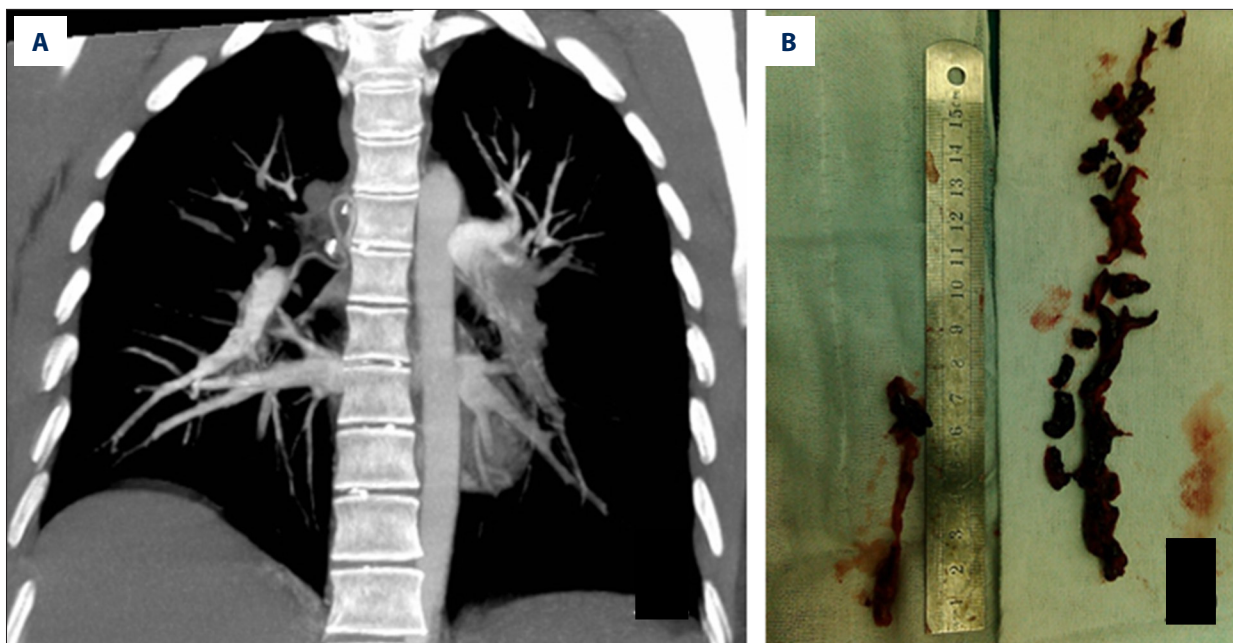


Figure 2. Pre- and postoperative images relating to case 4, who suffered sudden cardiac arrest. **(A)** Computed tomography angiogram showing the left pulmonary artery trunk to be completely blocked by the embolism. **(B)** Photograph of the surgically removed embolism.

of ECMO as intraoperative life support to ensure the completion of surgery, including lung transplantation, airway surgery, and other complex operations. Postoperative ECMO referred to the use of ECMO as an emergency rescue measure for severe complications of thoracic surgery, including PE, ARDS, and postoperative cardiac arrest requiring CPR.

In the present cohort, the rate of successful removal of ECMO was 90.9% (20/22), demonstrating the clinical utility of the technique. The rates of successful removal and survival were higher than previously reported for cardiovascular surgery [13]. In terms of application, ECMO can be used for preoperative stabilization or as emergency support for postoperative complications. Pulmonary hemorrhage and chest trauma involve considerable bleeding, which is often considered a contraindication for ECMO. However, we suggest that this bleeding should not necessarily contraindicate ECMO, particularly when the source of the bleeding is likely to be amenable to intervention; this suggestion is supported by other studies in which the authors have presented successful case reports [14,15]. Our study demonstrates that the use of preoperative ECMO as cardiopulmonary support prior to a complex operation has a dramatic effect on survival; however, although the survival rate was higher among patients who received preoperative ECMO, this was not statistically significant due to the limited sample size.

Among the 6 cases in the present study who received respiratory support for postoperative ARDS, all mortalities (2 patients)

were due to serious infection. Other studies have shown that ECMO offers improved stabilization of cardiopulmonary function and increased survival compared to conventional treatment when used for cardiopulmonary resuscitation and acute pulmonary embolism. It has been reported in the literature that hemodynamics is unstable in patients with high-risk acute pulmonary embolism [3]. The mortality rates for shock or cardiac arrest have been reported to be as high as 52.4%, and 10% of patients who suffer acute pulmonary embolism die within 1 h of onset of symptoms [16]. In the present study, 2 patients with pulmonary embolism and 2 patients who required cardiopulmonary resuscitation were stabilized by ECMO, and 50% survived. Thus, ECMO is clearly an effective support method for acute and severe patients undergoing thoracic surgery.

Due to the invasiveness and complexity of treatment, ECMO will inevitably be accompanied by many complications [17], which may be fatal, affecting the overall survival rate [19]. Complications that occur during implementation of ECMO can be categorized into mechanical-related and patient-related complications [19]. Mechanical complications include failure of the oxygenator, rupture of the circulation pipeline, failure of the pump or pressure sensor, and displacement of catheter position. Patient-related complications include bleeding, hemolysis, nervous system complications, organ failure (eg, heart, liver, or kidney), infection, and metabolic disorders. An experienced ECMO team can minimize the risk of mechanical complications, but patient-related complications are influenced by the specific condition of the individual.

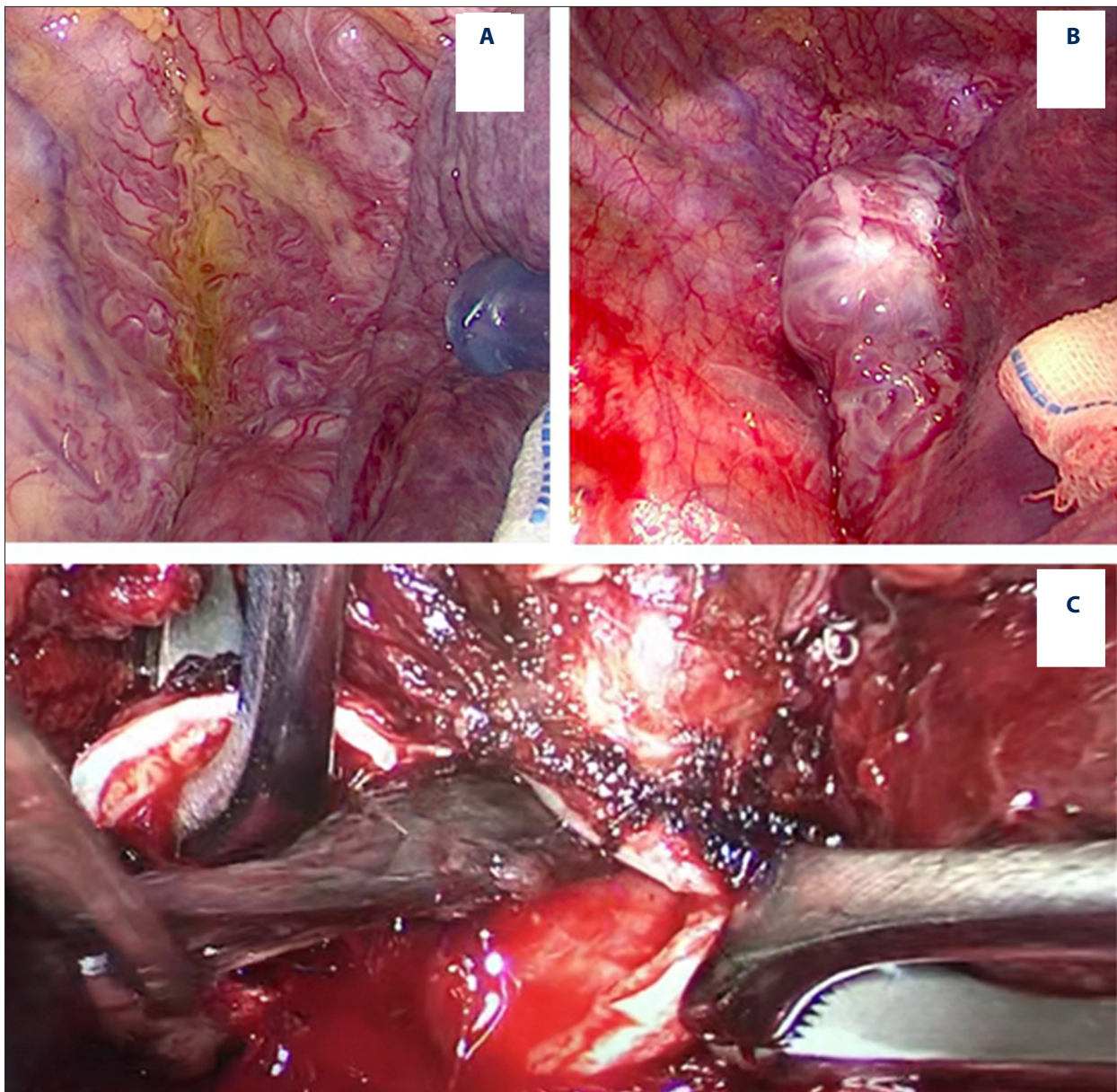


Figure 3. Supported by VV-ECMO, the surgery was performed independent of intubation and ventilation. (A) Massive abnormal vascular hyperplasia in the right upper mediastinum. The normal mediastinum pleura was not visualized. (B) The hemangioma was composed of a large number of crisscrossed arteriovenous masses. (C) Intraoperatively, the right intermediate bronchus was opened. Several blood clots can be seen blocking the bronchus. The blood clots in the main airway were completely removed.

In the present study, the main complications were serious bleeding and sepsis. The incidence that we noted for these complications (13.6%) is in line with a previous report stating that about 20% of patients experience some degree of bleeding (eg, bleeding at catheterization, cerebral hemorrhage, gastrointestinal bleeding) [20,21]. Administration of anticoagulants or coagulation factors and thrombocytopenia are common causes of bleeding. When these factors occur in combination with surgery, the risk of bleeding is higher; thus, hemostasis

should be meticulously managed in surgical patients, with temporary cessation of heparin anticoagulation if necessary. Infection, mainly blood-borne infections and severe pneumonia, is another common and serious complication [22,23]. Other patient-related complications include thrombosis, hemolysis, and air embolism [24], which can lead to poor prognosis if they are not managed appropriately.

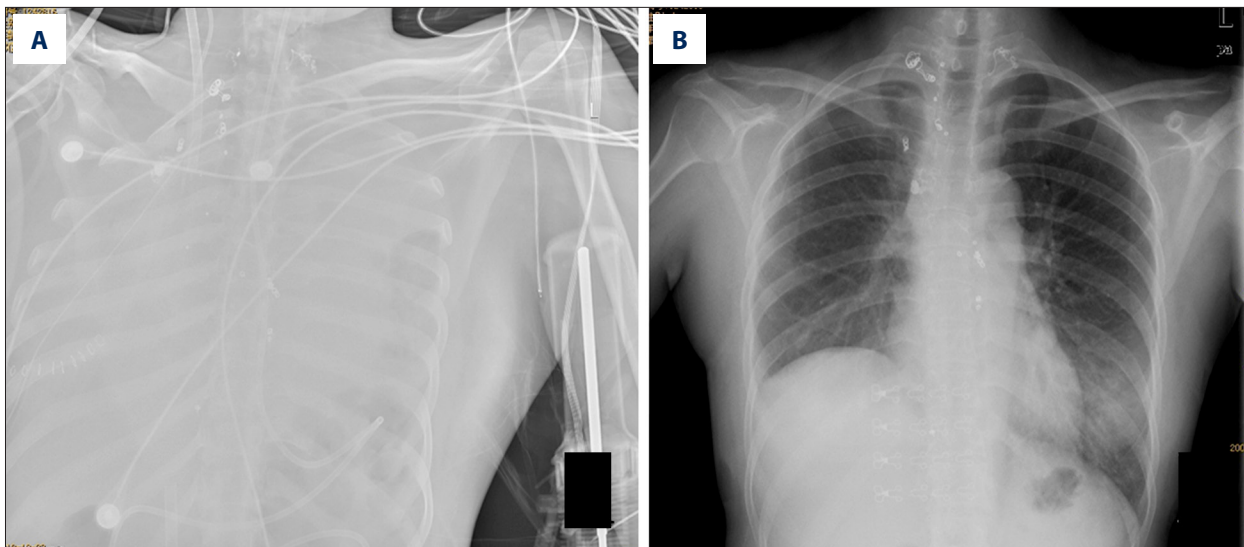


Figure 4. Pre- and postoperative X-ray images from case 13 admitted for repeated hemoptysis. (A) Preoperative X-ray revealed complete whiteout of the lungs due to bleeding from a branch of the right bronchus. (B) Postoperative X-ray prior to discharge shows resolution of whiteout.

The limitations of this study are that it was a single-center retrospective study with small sample size and large sample heterogeneity. It is necessary to accumulate a larger sample size and focus on a specific disease or situation from it for in-depth analysis.

Conclusions

In summary, ECMO can provide effective respiratory and circulatory support in perioperative treatment of critical patients undergoing thoracic surgery. Strict evaluation of indications and assessment of risks of complications will contribute to improving the overall outcome. Further development of the technology and accumulation of clinical experience will likely result in ECMO becoming an effective means for treating severe diseases in general thoracic surgery.

References:

- Cheng W, Ma XD, Su LX, et al. Cross-sectional study for the clinical application of extracorporeal membrane oxygenation in Mainland China, 2018. *Crit Care*. 2020;24(1):554
- Rehers S, Beiderlinden M, Ziegeler S. [Extracorporeal membrane oxygenation in thoracic surgery: The anesthesiologists perspective.] *Zentralbl Chir*. 2019;144(01):86-92 [in German]
- Harris DD, Saha SP. Extracorporeal membrane oxygenation as a rescue measure after thoracic surgery. *Asian Cardiovasc Thorac Ann*. 2018;26(3):203-6
- Heward E, Hashmi SF, Malagon I, et al. The role of thoracic surgery in extracorporeal membrane oxygenation services. *Asian Cardiovasc Thorac Ann*. 2018;26(3):183-87
- Reeb J, Olland A, Massard G, et al. Extracorporeal life support in thoracic surgery. *Eur J Cardiothorac Surg*. 2018;53(3):489-94
- McRae K, de Perrot M. Principles and indications of extracorporeal life support in general thoracic surgery. *J Thorac Dis*. 2018;10(Suppl.8):S931-46
- Rosenberg AA, Haft JW, Bartlett R, et al. Prolonged duration ECMO for ARDS: Futility, native lung recovery, or transplantation. *ASAIO J*. 2013;59:642-50
- Li BF, Liao XZ, Cheng Z, et al. [Application of extracorporeal membrane oxygenation combined with intra-aortic balloon pump in patients with heart failure after coronary artery bypass surgery.] *Chin J ECC*. 2011;9:13-15+12 [in Chinese]
- Wu YM, Ye HY, Li BF, et al. [Clinical application of extracorporeal membrane oxygenation support for acute heart failure after heart surgery.] *South China Journal of Cardiovascular Diseases*. 2013;19: 475-77 [in Chinese]
- Peek GJ, Clemens F, Elbourne D, et al. CESAR: conventional ventilatory support vs extracorporeal membrane oxygenation for severe adult respiratory failure. *BMC Health Serv Res*. 2006;6:63
- Paden ML, Conrad SA, Rycus PT, et al. ELSO Registry. Extracorporeal Life Support Organization Registry Report 2012. *ASAIO J*. 2013;59:202-10
- Hou XT. [Standardized development of external membrane oxygenation for the circulation support.] *Chin J ECC*. 2018;16:193-95 [in Chinese]
- Wei SB, Piao HL, Wang Y, et al. [The clinical application of extracorporeal membrane oxygenation in the preoperative period of cardiovascular surgery.] *Chin J Thorac Cardiovasc Surg*. 2018;34: 534-36 [in Chinese]
- Amos T, Yeung M, Gooi J, et al. Survival following traumatic thoracic compartment syndrome managed with VV-ECMO. *Trauma Case Rep*. 2019;24:100249
- Kleine-Brueggemy M, Nyman A, James P. Use of tracheal packing and perflurocarbon in life-threatening pulmonary hemorrhage on ECMO. *Pediatr Pulmonol*. 2020;55:568-70
- Bělohávek J, Dytrych V, Linhart A. Pulmonary embolism, part I: Epidemiology, risk factors and risk stratification, pathophysiology, clinical presentation, diagnosis and nonthrombotic pulmonary embolism. *Exp Clin Cardiol*. 2013;18:129-38
- Haines NM, Rycus PT, Zwischenberger JB, et al. Extracorporeal Life Support Registry Report 2008: Neonatal and pediatric cardiac cases. *ASAIO J* 2009;55:111-16
- Park PK, Napolitano LM, Bartlett RH. Extracorporeal membrane oxygenation in adult acute respiratory distress syndrome. *Crit Care Clin*. 2011;27:627-46

19. Jin Y-J, Liu C, Li F. Advances in the application of extracorporeal membrane oxygenation in acute respiratory distress syndrome. *Chin J Lung Dis (Electronic Edition)* 2015;8:478-81
20. Ried M, Bein T, Philipp A, et al. Extracorporeal lung support in trauma patients with severe chest injury and acute lung failure: A 10-year institutional experience. *Crit Care*. 2013;17:R110
21. Munshi L, Telesnicki T, Walkey A, et al. Extracorporeal life support for acute respiratory failure. A systematic review and metaanalysis. *Ann Am Thorac Soc*. 2014;11:802-10
22. Schmidt M, Bréchet N, Hariri S, et al. Nosocomial infections in adult cardiogenic shock patients supported by venoarterial extracorporeal membrane oxygenation. *Clin Infect Dis*. 2012;55:1633-41
23. Bizzarro MJ, Conrad SA, Kaufman DA, et al. Extracorporeal Life Support Organization Task Force on Infections, Extracorporeal Membrane Oxygenation. Infections acquired during extracorporeal membrane oxygenation in neonates, children, and adults. *Pediatr Crit Care Med*. 2011;12:277-81
24. Gray BW, Haft JW, Hirsch JC, et al. Extracorporeal life support: Experience with 2,000 patients. *ASAIO J*. 2015;61:2-7