

# Primary extraskeletal mesenchymal chondrosarcoma arising from the iliac vein

Hua Zhang, MD, Shuai Wang, MD, Zhibua Cheng, MD, Han Liu, MD.

### ABSTRACT

الوريد الحرقفي هو موقع نادر للغاية لحدوث الساركومة الغضروفية المتوسطة، والمرضى الذين يعانون من سرطان غضروفي الوسيط العضلي الوريد الناجم عن الوريد دائما يعانون من سوء التشخيص للغاية. نستعرض هنا حالة أنثى تبلغ من العمر 45 عاماً مع 5 أشهر تاريخ وذمة الساق اليسرى في عام 2015م. أظهر التصوير المقطعي كتلة كبيرة في الوريد الحرقفي الأيسر مع تكتلات متناثرة. تم إجراء استئصال واسع الهامش، وأكدت التحليلات النسيجية و المناعية وجود الساركومة الغضروفية المتوسطة داخل اللمعة مع الغزو المحلي خارج جدار الوريد. بسبب سوء الامتثال المريض، لم نبدأ بالعلاج الكيميائي نيوادجوفانت والعلاج الإشعاعي، وقد أجرى فحص العظام 16 أسبوعاً وأظهر الانبثاث العظام متعددة بعد العمل الجراحي. توفي المريض في الأسبوع 24 بعد العملية الجراحية.

The iliac vein is an extremely rare site for mesenchymal chondrosarcoma, and patients with primary extraskeletal mesenchymal chondrosarcoma arising from a vein always suffer a very poor prognosis. We report a case of a 45-year-old female who presented with a 5-month history of left leg edema in 2015. Contrast-enhanced computed tomography showed a large mass in the left iliac vein with scattered calcifications. Wide-margin resection was performed, and histopathologic and immunohistochemical analyses confirmed the presence of intraluminal mesenchymal chondrosarcoma with local invasion out of the vein wall. Due to poor patient compliance, postoperative neoadjuvant chemotherapy and radiotherapy were not started, and a bone scan performed 16 weeks postoperatively showed multiple bone metastases. The patient died on the twenty-fourth postoperative week.

*Saudi Med J* 2017; Vol. 38 (10): 1058-1061  
doi: 10.15537/smj.2017.10.20498

From the Department of Vascular Surgery (Zhang, Wang, Cheng) The First Hospital of Jilin University, Changchun, and the Department of Respiration (Liu), The First Hospital of Jilin University, Changchun, Jilin, China.

Received 11th June 2017. Accepted 16th August 2017.

Address correspondence and reprint request to: Dr. Han Liu, Department of Respiration, The First Hospital of Jilin University, Changchun, Jilin, China. E-mail: hebeking@126.com  
ORCID ID: 0000-0003-4163-5419

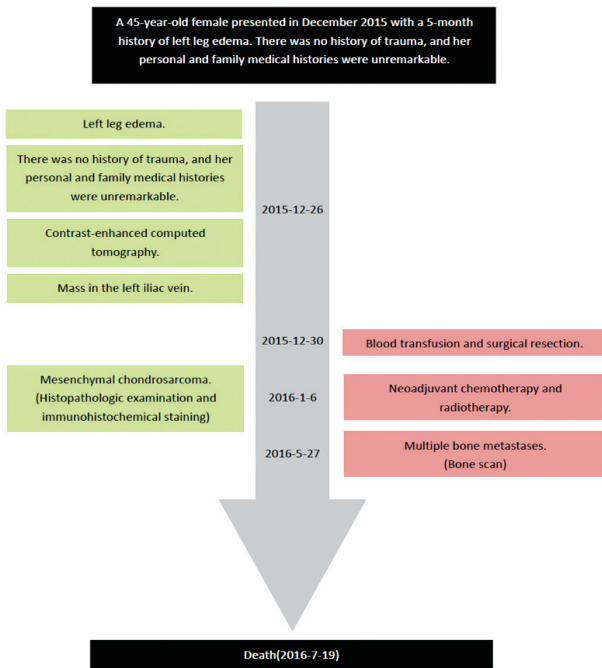
Mesenchymal chondrosarcoma is a rare and highly malignant tumor with a poor prognosis corresponding to a 5-year survival rate of 54.6% and a 10-year survival rate of 27.3%.<sup>1</sup> It can occur at extraskeletal locations and is mainly found in the soft tissues of the orbital, cranial, and spinal meningeal coverings and lower limbs.<sup>2,3</sup> Primary venous mesenchymal chondrosarcoma is extremely rare.<sup>4,5</sup> We report here a case of primary mesenchymal chondrosarcoma arising from the iliac vein.

**Case Report. Patient information.** A 45-year-old female presented in December 2015 with a 5-month history of left leg edema (Figure 1).

**Clinical findings.** On physical examination, no ulceration or pigmentation was observed. No lymphadenopathy was present in the inguinal region. There was no history of trauma, and her personal and family medical histories were unremarkable.

**Diagnostic assessment.** Contrast-enhanced computed tomography showed a large lobulated mass in the left iliac vein with scattered calcifications, and the intraluminal mass extended to the confluence of the left external and internal iliac veins (Figure 2). Routine chest x-ray, abdominal ultrasound, and bone scanning were performed, and no evidence of distant metastasis was found. In additional laboratory tests, the patient's red blood cell count (RBC) was  $1.72 \times 10^{12}/L$  and hemoglobin (Hb) was 49 g/L. After a blood transfusion, the anemia was rectified with the RBC increasing to  $2.63 \times 10^{12}/L$  and Hb to 83 g/L.

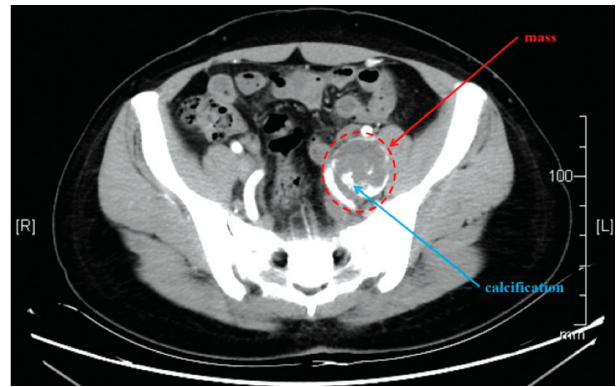
**Therapeutic intervention.** Surgical resection was performed while the patient was under general anesthesia. A skin incision was made in the left lower



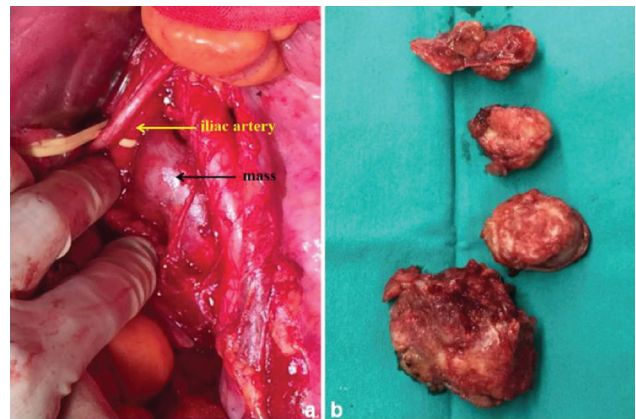
**Figure 1** - Timeline of a 45-year-old female presented with a 5-month history of left leg edema.

abdominal region. The iliac artery was dissected, and the iliac vein mass was found to be a tumor measuring 82×36×33 mm with rich blood supply and adherence to the surrounding muscle. The tumor encompassed the confluence of the external and internal iliac veins, and the intraluminal mass was unmovable. After intravenous injection of 4000 U of heparin, the tumor was resected and sent for preparation of frozen sections for histopathologic analysis, which indicated the mass was an intraluminal malignant tumor. To avoid recurrence and metastasis, we performed a wide-margin resection (expanded the resection margins to 50 mm) from the proximal and distal ends of the normal veins. Considering the rich pelvic collateral circulation, the proximal and distal ends were severed. The intraluminal portion of the mass was mostly pinkish-gray and solid (Figure 3). Histopathologic examination showed that most of the mass was confined within the venous intima, and local invasion out of vein wall was present (Figure 4). There was no invasion into the margin of

**Disclosure.** Authors have no conflict of interests, and the work was not supported or funded by any drug company.



**Figure 2** - Contrast-enhanced computed tomography revealed a large mass (red arrow) in the left iliac vein and scattered calcification (blue arrow).

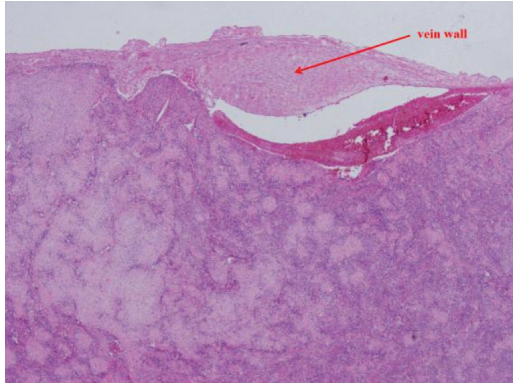


**Figure 3** - Images showing that: A) the mass (black arrow) was next to the iliac artery (yellow arrow); and B) the excised mass was mostly pinkish-gray and solid.

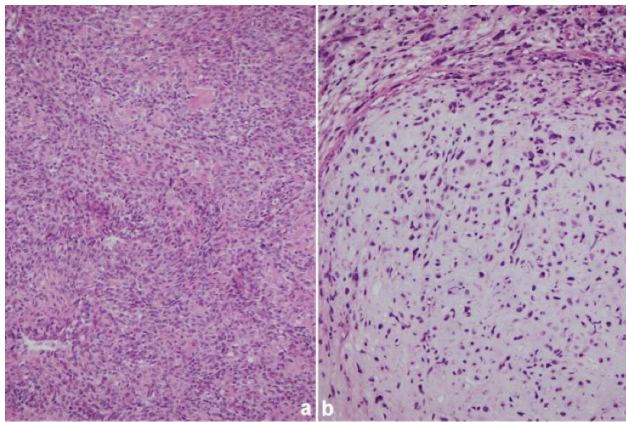
the surgical specimen. Moreover, the mass showed a bimorphic pattern, with areas of poorly differentiated small cells and well-differentiated chondral islands. Calcification and chondrosteosis were present in some areas. The poorly differentiated small cells had ovoid or elongated hyperchromatic nuclei and scant cytoplasm (Figure 5A). The chondral regions were relatively well-defined islands of benign-appearing chondroid tissue (Figure 5B). Immunohistochemical staining showed that the poorly differentiated small cells were positive for CD99 but those in the chondral regions were negative for CD99 (Figure 6A). However, the cells in the chondral regions were positive for S100 (Figure 6B).

**Follow-up and outcomes.** The patient was discharged 6 days after surgery, and we advised her to start neoadjuvant chemotherapy and radiotherapy in the third week postoperatively. However, the chemotherapy and radiotherapy were never started due to poor

compliance. Finally, a bone scan performed 16 weeks postoperatively showed multiple bone metastases, and the patient died on the twenty-fourth postoperative week.



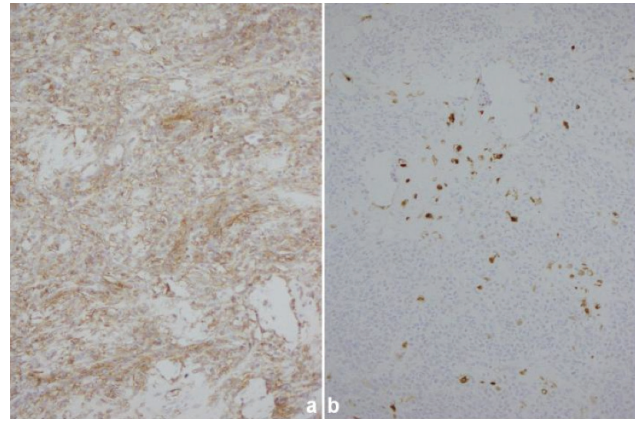
**Figure 4** - Histopathologic examination (magnification, 40x) showed that most of the mass was confined within the vein wall (red arrow).



**Figure 5** - Histopathologic examination (magnification, 200x) revealed: A) ovoid or elongated hyperchromatic nuclei and scant cytoplasm in the poorly differentiated small cells; and B) chondroid tissue in the chondral regions.

**Discussion.** Mesenchymal chondrosarcoma is a rare tumor characterized by chondrogenesis. In literature, there has not been case suffered the tumor arising from the iliac vein yet. It was first reported by Lichtenstein and Bernstein in 1959.<sup>6</sup> As a rare tumor in bone and soft tissue, it accounts for 3% to 10% of all chondrosarcoma and 0.2% to 0.7% of all bone tumors.<sup>1</sup> Most patients are 10-50 years old with no significant gender difference.<sup>7</sup> With high rates of recurrence as well as local and distant metastasis, patients usually suffer a poor prognosis<sup>8</sup> (Table 1).

Primary venous tumors, including leiomyosarcoma, hemangioendothelioma, and mesenchymal chondrosarcoma, are clinically uncommon. They share features of high malignancy, rapid growth, rich blood supply, and local venous thrombosis. In general, primary venous leiomyosarcoma usually is found in the inferior vena cava and lower extremity veins. In 1992, Dzsinič et al<sup>9</sup> conducted a retrospective study



**Figure 6** - Histopathologic examination (magnification, 200x) revealed: A) ovoid or elongated hyperchromatic nuclei and scant cytoplasm in the poorly differentiated small cells; and B) chondroid tissue in the chondral regions.

**Table 1** - Published studies reporting on the prognosis of mesenchymal chondrosarcoma.

Author	Publication year	Number of cases	Follow-up time	Survival rates %		
				3-years	5-years	10-years
Huvos et al <sup>7</sup>	1983	35	6.7 years (6-276 months)	-	54.6	27.3
Nakashima et al <sup>11</sup>	1986	111	3.17 years (1-528 months)	50	42.0	28.0
Vencio et al <sup>12</sup>	1998	19	7.6 years (11-372 months)	-	82.0	56.0
Dantonello et al <sup>13</sup>	2008	15	9.6 years (12-264 months)	-	76.3	66.8
Tang et al <sup>8</sup>	2012	27	3.55 years (6-104 months)	65	49.5	-

of 210 cases of primary venous leiomyosarcoma and reported that approximately 33% of cases occurred in lower extremity veins, with most tumors found in the great saphenous veins, femoral veins, external iliac veins, and popliteal veins. Leiomyosarcoma mainly originates from vascular smooth muscle cells, and the typical microscopic manifestations include disordered arrangement of muscle fibers and small spindle cells, with positive staining for eosinophilic cytoplasm, desmine, and actine, of which the latter 2 are immunohistochemical staining markers of smooth muscle cells. It is difficult to distinguish leiomyosarcoma from mesenchymal chondrosarcoma based on clinical signs, radiological images, and ultrasonic examination. Hemangioendothelioma mainly originates from vascular endothelial cells with less potential for metastasis. In addition, primary venous non-Hodgkin's lymphoma was reported, and proliferation and invasion of lymphocytes in vascular tissue were reported.<sup>10</sup>

Chondral calcification can be found through radiological examination in mesenchymal chondrosarcoma, but it is not specific.<sup>3</sup> Notably, histopathologic and immunohistochemical examinations are the main methods for identifying mesenchymal chondrosarcoma. Moreover, the latter is very important for distinguishing mesenchymal chondrosarcoma from Ewings sarcoma, lymphoma, hemangiopericytoma, and embryonal rhabdomyosarcoma. The typical histopathologic manifestation of mesenchymal chondrosarcoma is disordered arrangement of well-differentiated chondral lesions and poorly differentiated mesenchymal lesions, which is called dimorphism.<sup>1,6</sup> Calcification and chondrosteosis in chondral lesions and transitional zones between chondral lesions and mesenchymal lesions can be found in histopathologic examination.<sup>1</sup> Furthermore, the mesenchymal lesions are always CD99(+), Leu7(+), and S-100(-), the chondral lesions are S-100(+).<sup>1,2</sup> In the present case, calcification and positive staining for S-100 were found in chondral lesions, and the mesenchymal lesions were CD99(+) and S-100(-).

In conclusion, primary extraskeletal mesenchymal chondrosarcoma in any location is very rare, and patients always suffer a poor prognosis. The patient in the present case died on the twenty-fourth week postoperatively. Further, case series studies are needed to provide systematic diagnostic criteria and treatment recommendations for primary extraskeletal mesenchymal chondrosarcoma.

**Acknowledgment.** Authors gratefully acknowledge Dr. Sean Luo, Wake Forest Baptist Health, Winston-Salem, NC, USA, for medical editing and writing assistance.

## References

1. Mangham DC, Athanasou NA. Guidelines for histopathological specimen examination and diagnostic reporting of primary bone tumours. *Clin Sarcoma Res* 2011; 1: 6.
2. Xu J, Li DS, Xie L, Tang S, Guo W. Mesenchymal chondrosarcoma of bone and soft tissue: A systematic review of 107 patients in the past 20 years. *PLoS One* 2015; 10: e0122216.
3. Chen YY, Wang XM, Guo LC, Li YG, Deng SM, Liu YH, et al. Radiological features and pathology of extraskeletal mesenchymal chondrosarcoma. *Clin Imaging* 2012; 36: 365-370.
4. Kim GE, Kim DK, Park IJ, Ro JY. Mesenchymal chondrosarcoma originating from the femoral vein. *J Vasc Surg* 2003; 37: 202-205.
5. Guo JM, Gu YQ, Guo LR, Tong Z, Wu X, Zhang J, et al. A case of mesenchymal chondrosarcoma arising from the femoral vein with 8 years of follow-up. *Ann Vasc Surg* 2015; 29: 1455. e1-e5.
6. Lichtenstein L, Bernstein D. Unusual benign and malignant chondroid tumors of the bone: a survey of some mesenchymal cartilage tumors and malignant chondroblastic tumors, including a few multicentric ones, as well as many atypical benign chondroblastomas and chondromyxoid fibromas. *Cancer* 1959; 12: 1142-1157.
7. Huvos AG, Rosen G, Dabska M, Marcove RC. Mesenchymal chondrosarcoma. A clinicopathologic analysis of 35 patients with emphasis on treatment. *Cancer* 1983; 51: 1230-1237.
8. Tang S, Guo W, Tang XD, Li DS, Wang YF. Surgical treatment and prognosis of mesenchymal chondrosarcoma. *Chin J Clin Oncol* 2013; 40: 984-987.
9. Simon B, Chandramohan A, Eapen A, Nayak S, Jeyaraj V. Intravascular mesenchymal chondrosarcoma. *J Vasc Interv Radiol* 2014; 25: 1937.
10. Rulli F, Neri A, Bigotti G, Tartaglione R, Cefaro GA, Farinon AM. Primary malignant lymphoma of the saphenous vein. *J Vasc Surg* 2002; 35: 168-171.
11. Nakashima Y, Unni KK, Shives TC, Swee RG, Dahlin DC. Mesenchymal chondrosarcoma of bone and soft tissue. A review of 111 cases. *Cancer* 1986; 57: 2444-2453.
12. Vencio EF, Reeve CM, Unni KK, Nascimento AG. Mesenchymal chondrosarcoma of the jaw bones: clinicopathologic study of 19 cases. *Cancer* 1998; 82: 2350-2355.
13. Dantonello TM, Int-Veen C, Leuschner I, Schuck A, Furtwaengler R, Claviez A, et al. Mesenchymal chondrosarcoma of soft tissues and bone in children, adolescents, and young adults: experiences of the CWS and Coss study groups. *Cancer* 2008; 112: 2424-2431.