

Surgical Management of Pediatric Cervical Angular Kyphosis with 540° Approach and Metacarpal Plate: A Case Report and Introduction of a Novel Technique

Abstract

Surgical decompression, deformity correction, and instrumentation of the upper cervical spine are challenging problems in cervical kyphosis, especially in infants and pediatrics. According to patients' age, surgical exposure is difficult and selecting the appropriate instrument for rigid fixation is crucial. In this article, we present a case of 2 years old with cervical angular kyphosis, which was approached posteriorly at first. Through posterior approach, C3–C5 laminectomy with complete excision of spinous process was performed. Then, the patient's position was changed to supine and C3–C5 corpectomies were performed anteriorly with a longitudinal incision, and the thecal sac was decompressed. A titanium cage with appropriate size and graft was placed after possible deformity correction conducted with head traction and neck extension. Anterior fixation was performed with two, 2-mm T-shaped metacarpal plates with two screws in C2 and four screws in C6. The patient's position was changed to prone again, and posterior fixation was done with two metacarpal plates located on lateral masses. We showed that a novel technique in correction and fixation of cervical kyphosis in pediatric is using metacarpal plates while they are fixed to lateral masses.

Keywords: Cervical fusion, cervical kyphosis, pediatric spine

Introduction

Cervical kyphosis needing surgical stabilization is a rare procedure and also challenging in pediatrics. Typical conditions associated with cervical kyphosis are Larsen syndrome^[1,2] diastrophic dysplasia,^[3,4] chondrodysplasia punctata (Conradi syndrome),^[5] campomelic dysplasia,^[6] and neurofibromatosis. Trauma, neoplastic disease, infection, systemic arthritis, radiation, and iatrogenic processes are other causes of cervical kyphotic deformity.

Physical therapy and bracing are typically the first step in management of spinal deformity in the pediatric population. Surgical fusion is indicated if the deformity progressed and the patient did not respond to conservative management or if neurologic deficit occurred.^[7,8] Neural decompression, deformity correction, and spinal reconstruction are the goals of surgical management. Based on the patient's age, clinical and radiological evaluations, available instruments, and the morbidity and mortality risks of each

surgical strategy, individualized approaches should be selected. Anterior-only, posterior-only, and anterior-posterior approaches can be tailored to the individual patient. Although the combined approaches appear to result in a greater degree of deformity correction than the anterior or posterior alone approach, they carry a higher rate of postoperative morbidity and mortality.^[9,10]

Because of lack of appropriate and especially designed pediatric spine instrumentation and diminutive size of the vertebra, internal fixation of corrected deformity in the infantile cervical spine is challenging and surgical treatment may be complicated by inappropriate or nonrigid instrumentation that can lead to pseudarthrosis, loss of correction, deformity progression, and neurological deterioration. Here, we report a novel surgical strategy and fixation method for management of cervical kyphosis in pediatrics.

**Mohammad Zarei,
Mersad Moosavi¹,
Nima Ostad
Rahimi²,
Mohsen Rostami³**

Departments of Orthopedic Surgery and ²Neurosurgery, Tehran University of Medical Sciences, ³Sports Medicine Research Center, Neuroscience Institute, Tehran University of Medical Sciences, Tehran, Iran ¹Spine Center of Excellence, Yas Hospital, Tehran University of Medical Sciences, Tehran, Iran

Address for correspondence:

*Dr. Mohsen Rostami,
Sports Medicine Research
Center, Neuroscience Institute,
Tehran University of Medical
Sciences, Tehran, Iran.
E-mail: rostami.moh@gmail.
com*

This is an open access journal, and articles are distributed under the terms of the Creative Commons Attribution-NonCommercial-ShareAlike 4.0 License, which allows others to remix, tweak, and build upon the work non-commercially, as long as appropriate credit is given and the new creations are licensed under the identical terms.

For reprints contact: WKHLRPMedknow_reprints@wolterskluwer.com

How to cite this article: Zarei M, Moosavi M, Rahimi NO, Rostami M. Surgical management of pediatric cervical angular kyphosis with 540° approach and metacarpal plate: A case report and introduction of a novel technique. *Asian J Neurosurg* 2021;16:155-8.

Submitted: 03-May-2020

Revised: 23-May-2020

Accepted: 20-Oct-2020

Published: 23-Feb-2021

Access this article online

Website: www.asianjns.org

DOI: 10.4103/ajns.AJNS_195_20

Quick Response Code:



Case Report

A 2-year-old girl presented with a progressive quadriparesis since 6 months ago and cervical kyphosis. She was developmentally normal, but recently, she was unable to walk but able to sit and crawling with well truncal control. She underwent casting for club foot shortly after birth and mild bilateral flexion contracture of knees left untreated. She had a normal face, and neck movement was restricted on physical examination. All reflexes were exaggerated. Plantar responses were extensor bilaterally. Genetic work-up did not reveal chromosomal abnormality, and laboratory tests were normal. The lateral cervical X-rays revealed 75° kyphosis from the C2 to the C4 with apex at the C3. MRI illustrated cord signal change and ventral cord compression [Figures 1 and 2]. Magnetic resonance imaging scan of the whole spine did not reveal any other anomaly [Figure 2]. A CT scan was obtained to evaluate bony structure and surgical planning [Figure 3].

Surgical technique

Intraoperative neuromonitoring was used during the operation. After intubation using fiber optic, the patient was placed in prone position. Midline incision was accomplished with anatomic exposition of posterior bony structure. Subperiosteal dissection was performed to reduce curve stiffness and bleeding. Distorted lamina and spinous process with bony impingement that hampered any kyphotic deformity correction was evident. C3–C5 laminectomy with complete excision of spinous process was performed. Then, the patient's position was changed to supine. C3–C5 corpectomies were performed anteriorly with a longitudinal incision, and the thecal sac was decompressed. A titanium cage with appropriate size and graft was placed after possible deformity correction conducted with head traction and neck extension. Anterior fixation was performed with two, 2-mm T-shaped metacarpal plates with two screws in C2 and four screws in C6. Screw size was measured preoperatively by computed tomography. The patient's position was changed to prone again, and posterior fixation was done with two 6-hole 2-mm metacarpal plates located on lateral masses and fixed with two screws placed in C5 and C6 lateral masses in caudal side and two screws placed in C3 lateral mass and C2 isthmus. After decortication, harvested autograft was placed on facets and posterolateral sides. Posterior wound was closed, and after immobilization with cervical collar, the patient was placed in supine position. No change was observed in neuromonitoring parameters during the operation.

Postoperative cervical kyphosis was 11° and about 85% correction was achieved [Figure 4]. She was discharged with cervicothoracic orthosis [Figure 5], and after 6-month follow-up, radiographic studies obtained showed evidence of osseous fusion. At the 12-month follow-up, examination illustrated consecutive improvement in the patient's

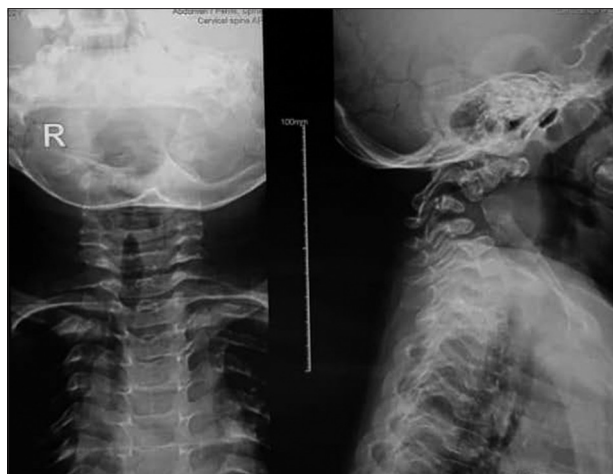

Figure 1: Radiographic study of the patient with cervical kyphosis at anteroposterior and lateral views

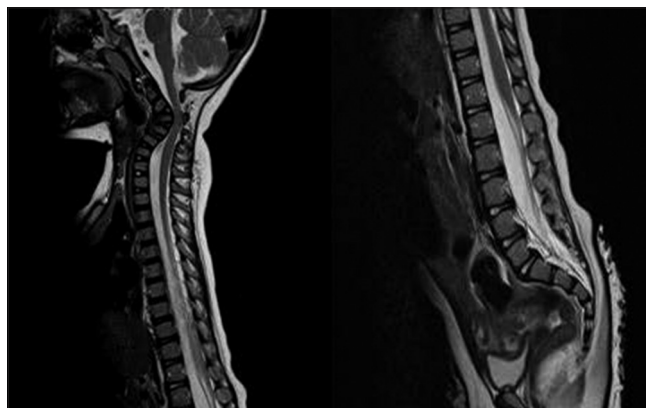


Figure 2: Whole-spine magnetic resonance imaging study of the patient with cervical kyphosis

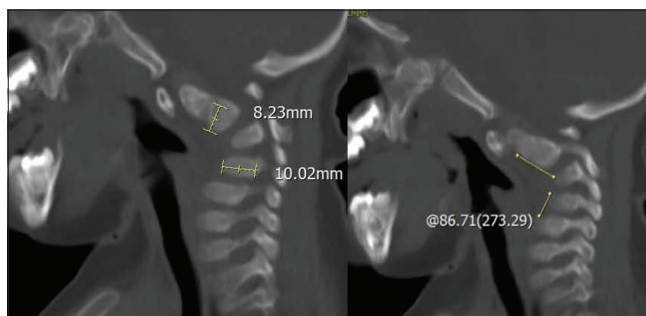


Figure 3: Computed tomography scan showed about 86° kyphosis. Furthermore, the size of bony elements was well defined by computed tomography scan

neurological status and she was able to walk. Cervical motion and alignment was acceptable.

Discussion

Progressive cervical kyphosis, if left untreated, can cause neurological compromise, dysphagia, and impaired gaze.^[11] Surgical treatment was performed to achieve the correction of deformity and neural decompression. Surgical treatment options include posterior cervical fusion, anterior cervical

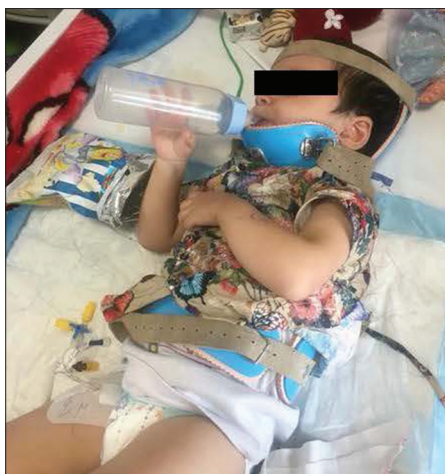

Figure 4: Postoperative imaging at anteroposterior and lateral views and sagittal computed tomography scan images

fusion, or both.^[11,12] Decompression requires anterior vertebratomy because the apex of the kyphosis is the source of the cord impingement.

In patients without neurological deficit, posterior-only approach and fusion can limit posterior growth while has not significant impact on anterior column. This might lead to gradual correction of deformity by continuous growth of anterior column. However, in anterior-only surgical approaches, The anterior fusion and posterior growth, might lead to kyphosis progression

Johnston *et al.*^[2] studied the effect of posterior-only cervical fusion on a series of four patients with cervical kyphosis due to Larsen syndrome. They reported that early posterior cervical fusion in infancy leads to stability, prevented progression of deformity and even gradual correction of deformity by continuous anterior column growth. One patient in their series developed hyperlordotic deformity and decompression performed due to neurologic deficit. Martus *et al.*^[13] series of five Larsen patients supports a previous study that posterior arthrodesis alone in pediatric cervical kyphosis by allowing further anterior column growth can correct the deformity. Furthermore, they advocated that hyperlordosis may be developed after posterior fusion and required close monitoring.

In patients with established neurologic deficit, anterior decompression and stabilization combined with posterior cervical fusion and fixation were recommended to prevent increasing deformity from posterior element growth and to enhance the stability of fixation. The absence of anterior column growth and therefore gradual correction of kyphotic deformity is a disadvantage of combined anterior and posterior fusion. The risk of spinal cord injury during anterior decompression in cervical kyphosis is relatively high and hypoplastic vertebrae, and also, severe kyphotic deformities made the anterior instrumented fusion technically demanding and quite dangerous in

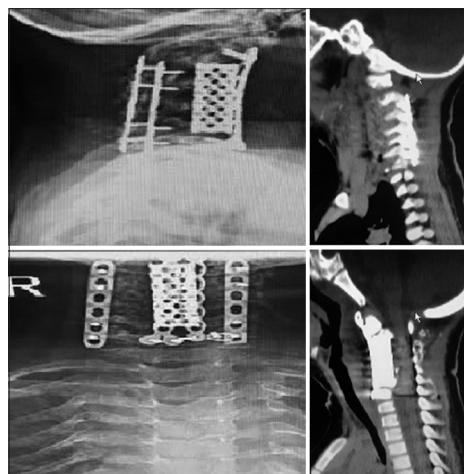


Figure 5: The patient experienced no deficit at postoperative course and orthosis was fixed for her

pediatrics. Sakaura *et al.*^[14] recommended posterior-only fusion for mild and flexible cervical kyphosis and anterior decompression with combined anterior and posterior fusion in patients with severe kyphotic deformity and Larsen syndrome.

Our patient underwent combined anterior and posterior decompression and instrumented fusion. Surgery goals were to improve the neurological deficit and cervical alignment, rigid fixation, and successful fusion. In preoperative evaluation of the patient, no correction was observed in lateral dynamic X-ray study. This showed that the curve is rigid. Furthermore, during surgery, the rigidity of curve was evident. To eliminate the bony impingement between the spinous processes, first, we performed spinous process resection because we believed that elongated and deformed spinous process and lamina may prevent deformity correction after anterior decompression and instrumentation. Then, to reduce curve stiffness and the risk of neurologic compromise and also the deformed lamina observed in surgery, we performed laminectomy. Even after laminectomy, during anterior approach, the curve was rigid and it was impossible to correct the deformity without corpectomy, and therefore, we were forced to do corpectomy and use mesh cage instead of discectomy and grafting. Due to unavailability of pediatric-specific spinal instruments in our country, it was not easy to choose an appropriate instrument for cervical rigid fixation in a 2 year-old patient with such small vertebral size. We performed both anterior plating and posterior-lateral mass fixation with a 2-mm metacarpal plate and achieved rigid fixation and fusion. Since the major cervical kyphosis was from C2 to C4 with apex at C3, to preserve neck motion and especially head flexion, we planned to limit the fusion to C2 and did not include occiput in the fusion construct. The operation time in our three-stage procedure was 340 min. According to operation time, hemostasis during the operation is so important. The patient's position was

changed two times during procedure, and care was taken to avoid additional neurological injury. Intraoperative neuromonitoring was used during procedure to prevent neurological complication. We believe that cervicothoracic orthosis in the patient with cervical kyphosis is an appropriate way to achieve solid fusion.

Declaration of patient consent

The authors certify that they have obtained all appropriate patient consent forms. In the form the patient(s) has/have given his/her/their consent for his/her/their images and other clinical information to be reported in the journal. The patients understand that their names and initials will not be published and due efforts will be made to conceal their identity, but anonymity cannot be guaranteed.

Financial support and sponsorship

Nil.

Conflicts of interest

There are no conflicts of interest.

References

- Forese LL, Berdon WE, Harcke HT, Wagner ML, Lachman R, Chorney GS, *et al.* Severe mid-cervical kyphosis with cord compression in Larsen's syndrome and diastrophic dysplasia: Unrelated syndromes with similar radiologic findings and neurosurgical implications. *Pediatr Radiol* 1995;25:136-9.
- Johnston CE 2nd, Birch JG, Daniels JL. Cervical kyphosis in patients who have Larsen syndrome. *J Bone Joint Surg Am* 1996;78:538-45.
- Poussa M, Merikanto J, Ryöppy S, Marttinen E, Kaitila I. The spine in diastrophic dysplasia. *Spine (Phila Pa 1976)* 1991;16:881-7.
- Remes V, Marttinen E, Poussa M, Kaitila I, Peltonen J. Cervical kyphosis in diastrophic dysplasia. *Spine (Phila Pa 1976)* 1999;24:1990-5.
- Svensson O, Aaro S. Cervical instability in skeletal dysplasia. Report of 6 surgically fused cases. *Acta Orthop Scand* 1988;59:66-70.
- Coscia MF, Bassett GS, Bowen JR, Ogilvie JW, Winter RB, Simonton SC. Spinal abnormalities in camptomelic dysplasia. *J Pediatr Orthop* 1989;9:6-14.
- Jasiewicz B, Potaczek T, Tesiorowski M, Lokas K. Spine deformities in patients with Ehlers-Danlos syndrome, type IV-late results of surgical treatment. *Scoliosis* 2010;5:26.
- McMaster MJ. Spinal deformity in Ehlers-Danlos syndrome. Five patients treated by spinal fusion. *J Bone Joint Surg Br* 1994;76:773-7.
- Mummaneni PV, Dhall SS, Rodts GE, Haid RW. Circumferential fusion for cervical kyphotic deformity. *J Neurosurg Spine* 2008;9:515-21.
- Nottmeier EW, Deen HG, Patel N, Birch B. Cervical kyphotic deformity correction using 360-degree reconstruction. *J Spinal Disord Tech* 2009;22:385-91.
- Kokubun S, Ozawa H, Sakurai M, Ishii Y. One-stage anterior and posterior correction of severe kyphosis of the cervical spine in neurofibromatosis. A case report. *Spine (Phila Pa 1976)* 1993;18:2332-5.
- Francis WR Jr., Noble DP. Treatment of cervical kyphosis in children. *Spine (Phila Pa 1976)* 1988;13:883-7.
- Martus JE, Griffith TE, Dear JC, Rathjen KE. Pediatric cervical kyphosis: A comparison of arthrodesis techniques. *Spine (Phila Pa 1976)* 2011;36:E1145-53.
- Sakaura H, Matsuoka T, Iwasaki M, Yonenobu K, Yoshikawa H. Surgical treatment of cervical kyphosis in Larsen syndrome: Report of 3 cases and review of the literature. *Spine (Phila Pa 1976)* 2007;32:E39-44.