











Thorax computed tomography findings and anti-SARS-CoV-2 immunoglobulin G levels in polymerase chain reaction-negative probable COVID-19 cases

Ismail Yurtsever^{1*} , Cumali Karatoprak² , Bilge Sumbul³ , Muharrem Kiskac² , Muhammed Tunc² , Mehmet Zorlu² , Hamza Ogun⁴ , Bulent Durdu⁵ , Ozlem Toluk⁶ , Mustafa Cakirca² 

SUMMARY

OBJECTIVE: This study aimed to evaluate the SARS-CoV-2 immunoglobulin G (IgG) levels after 6 months of polymerase chain reaction (PCR) negative but assumed to be COVID-19 positive cases to investigate the relationship between IgG levels and thoracic computed tomography (CT) findings.

METHODS: This was a single-center study that included patients whose PCR test results were negative at least three times using nasopharyngeal swabs but had clinical findings of COVID-19 and thoracic CT findings compatible with viral pneumonia. Six months after discharge, the IgG antibodies were analyzed. The cutoff value for negative and positive serology was defined as <1.4 (index S/C) and ≥1.4 (index S/C), respectively. In addition, the patients were categorized according to their thoracic CT findings as high (typical) and low (atypical). Also, the patients were grouped into classes as <5% lung involvement versus ≥5% lung involvement.

RESULTS: The patients' mean age was 49.78±12.96 years. PCR was negative, but patients with COVID-19 symptoms who had SARS-CoV-2 IgG positive were 81.9% (n=95). The antibody titer and lung involvement ≥5% were statistically significantly higher in SARS-CoV-2 IgG positive cases (p<0.001 and p=0.021). Age and chest CT findings were the risk factors for lung involvement (OR=1.08, p<0.001 and OR=2.19, p=0.010, respectively).

CONCLUSION: This study is valuable because increasing severity (≥5%) of lung involvement appears to be associated with high and persistent IgG antibody titers. In probable cases of COVID-19, even if the PCR test is negative, high IgG titers 6 months after discharge can predict the rate of lung parenchymal involvement.

KEYWORDS: COVID-19. SARS-CoV-2. Reverse transcriptase-polymerase chain reaction. Computed tomography. Chest. Immunoglobulin G, Antibody.

INTRODUCTION

Severe acute respiratory syndrome-coronavirus 2 (SARS-CoV-2) is a respiratory disease caused by a novel coronavirus-2019 (COVID-19) that has rapidly spread worldwide and affected every aspect of life. The definitive diagnosis is made based on viral testing (nucleic acid amplification or antigen tests) in patients having clinical signs and symptoms or close contacts¹. Determining viral genome targets by reverse-transcription polymerase chain reaction (RT-PCR) is the gold standard in COVID-19 diagnosis. However, the sensitivity (i.e., the ability of a test to correctly identify those with the disease) and specificity (i.e., the ability of a test to correctly identify those without the disease) of RT-PCR testing through nasopharyngeal swabs are relatively low with a varying degree of false negativity^{2,3}. As in

all laboratory tests, inadequate sampling, improper transport, improper ribonucleic acid extraction process, and the presence of amplification inhibitors may yield false-positive or false-negative results^{4,5}. A negative test result does not rule out the possibility of COVID-19, while a positive test often indicates the presence of the infection⁶.

Previous studies have shown a specificity of >95% for enzyme-linked immunosorbent assay-based immunoglobulin (Ig) M and G antibody testing in the diagnosis of COVID-19⁷. Although antibody response to SARS-CoV-2 infection usually occurs in the first 7–11 days after infection, delayed antibody production may be seen in some cases. Therefore, antibody testing is not helpful and not recommended in diagnosing current infection⁶. Serological tests also have limited utility in

¹Bezmalem Vakif University, Faculty of Medicine, Department of Radiology – Fatih (Istanbul), Turkey.

²Bezmalem Vakif University, Faculty of Medicine, Internal Medicine Clinic – Fatih (Istanbul), Turkey.

³Bezmalem Vakif University, Faculty of Medicine, Department of Medical Microbiology – Fatih (Istanbul), Turkey.

⁴Bezmalem Vakif University, Faculty of Medicine, Department of Chest Diseases – Fatih (Istanbul), Turkey.

⁵Bezmalem Vakif University, Faculty of Medicine, Department of Infectious Diseases and Clinical Microbiology – Fatih (Istanbul), Turkey.

⁶Bezmalem Vakif University, Faculty of Medicine, Department of Biostatistics – Fatih (Istanbul), Turkey.

*Corresponding author: dryurtsever@hotmail.com

Conflicts of interest: the authors declare there is no conflict of interest. Funding: none.

Received on August 29, 2022. Accepted on September 03, 2022.

diagnosing acute infections, as they depend on the duration of symptom onset⁸. Therefore, antibody testing is not feasible in diagnosing acute infections⁶.

Due to the limited utility of RT-PCR and antibody testing in COVID-19, imaging studies have become an integral part of the diagnostic work-up of these patients. Although thoracic computed tomography (CT) findings showing ground-glass opacities in the bilateral, multifocal, and peripheral ground or interlobular septal consolidation suggest COVID-19 pneumonia in patients with lower respiratory tract involvement, these findings may be seen in non-COVID-19 viral pneumonia. The definitive diagnosis can be more challenging in the absence of typical lung involvement and the presence of RT-PCR negativity⁹.

The antibody status and titers are unknown 6 months after the initial diagnosis in probable COVID-19 cases, and the protective role of IgG antibodies is uncertain. Therefore, in this study, we aimed to evaluate the SARS-CoV-2 immunoglobulin G (IgG) levels at 6 months in probable COVID-19 cases and investigate the relationship between anti-SARS-CoV-2 IgG levels and thoracic CT findings.

METHODS

Study design and study population

In this single-center, retrospective, cross-sectional study, a total of 380 hospitalized patients with probable COVID-19 infection who had persistent fever ($>38^{\circ}\text{C}$), hypotension ($<90/60$ mmHg), tachycardia (>100 bpm), tachypnea (>30 breaths per min), an oxygen saturation (SpO_2) of $<92\%$, and elevated acute phase response (C-reactive protein >40 mg/L, ferritin >500 ng/mL, and D-dimer $>1,000$ ng/mL) were screened. Those having antigen positivity for influenza, heart failure, bacterial pneumonia, and restrictive lung disease were excluded from the study. Medical data of the patients who were hospitalized with the diagnosis of PCR-negative probable COVID-19 infection between March 2020 and May 2020 were reviewed.

Inclusion criteria were as follows: >18 years of age at the time of admission, at least three consecutive negative results of RT-PCR assay using nasopharyngeal swabs, having at least one thoracic CT scan during the hospital stay, having no need for intensive care, and discharge with full recovery. Those unwilling to participate in the study, deceased patients, pregnant and breastfeeding women, and those lost to follow-up were excluded. Finally, 116 patients whose RT-PCR test results were negative using oropharyngeal and nasopharyngeal swabs but had clinical findings of COVID-19 and thoracic CT findings

compatible with viral pneumonia were included. Six months after discharge, all patients' SARS-CoV-2 IgG antibodies and thoracic CT findings were analyzed.

According to this scheme, the patients were classified into two categories of thoracic CT findings: a high (typical) and a low (atypical) level of suspicion of consistency with COVID-19. We also evaluated the possible relationship between anti-SARS-CoV-2 IgG levels and the thoracic CT findings. The patients were categorized into two groups: $<5\%$ lung involvement and $\geq 5\%$ lung involvement. Similarly, we compared the chest CT findings of the patients with $<5\%$ lung involvement versus $\geq 5\%$ lung involvement to elucidate the effect of lung involvement on anti-SARS-CoV-2 IgG antibodies.

Data collection

The patients who were included in the study were reached by phone calls and scheduled for a visit at 6 months in the outpatient setting. Clinical data, COVID-19 reinfection, and comorbidities of the patients were recorded. Venous blood samples were collected from each patient for antibody testing. Baseline thoracic CT scans were assessed by a single radiologist who was blinded to the clinical findings and antibody test results of the patients, and the severity of lung involvement was examined. Demographic, clinical, laboratory, and imaging characteristics of the patients were recorded.

Antibody testing

The chemiluminescence microparticle immunoassay was used for the qualitative detection of anti-SARS-CoV-2-specific IgG antibodies in human serum and plasma. In clinical practice, the SARS-CoV-2 IgG antibody testing is used to detect IgG antibodies against the nucleocapsid protein of the SARS-CoV-2 in human serum and plasma in suspected COVID-19 cases having signs and symptoms or confirmed cases. In this study, the antibody testing was performed using the ARCHITECT autoanalyzer (Abbott Laboratories, IL, USA). The cutoff value for negative and positive serology was defined as <1.4 (index S/C) and ≥ 1.4 (index S/C), respectively. The sensitivity and specificity of the assay were calculated as 99.63% (Abbott ARCHITECT™ SARS-CoV-2 IgG Instructions for Use. H14806R01. April 2020).

Imaging studies

Baseline thoracic CT scans of all patients during the hospital stay were retrospectively evaluated. Chest computed tomography score, in which each lobe could be awarded a CT score from 0 to 5, depending on the percentage of the involved lobe, can be presented as follows:

- Score 0: 0% involvement;
- Score 1: less than 5% involvement;
- Score 2: 5–25% involvement;
- Score 3: 26–49% involvement;
- Score 4: 50–75% involvement;
- Score 5: greater than 75% involvement¹⁰.

Exemplary thorax CT findings demonstrating COVID-19 infiltration in the axial view of our patients are shown in Figure 1. Thoracic CT findings of patients with <5% lung involvement versus ≥5% lung involvement were compared.

Ethical consideration

Prior to the study, all patients were informed about the nature of the study and a written informed consent was obtained. The study protocol was approved by the institutional Ethics Committee with Approval No. 71306642-050.05.04. The study was conducted in accordance with the principles of the Declaration of Helsinki.

Statistical analysis

Descriptive statistics were given median (minimum-maximum), frequencies with percentages, and mean±standard deviation. Fisher’s exact test, chi-square test, Mann-Whitney U test, and independent samples t-tests were performed for comparisons. The risk factors of lung involvement were analyzed with binary logistic regression analysis using the enter method. The SPSS (IBM Corp., Released 2021, IBM SPSS Statistics for Windows, Version 28.0, Armonk, NY) software was used for analyses. The level of significance was taken as $\alpha=0.05$.

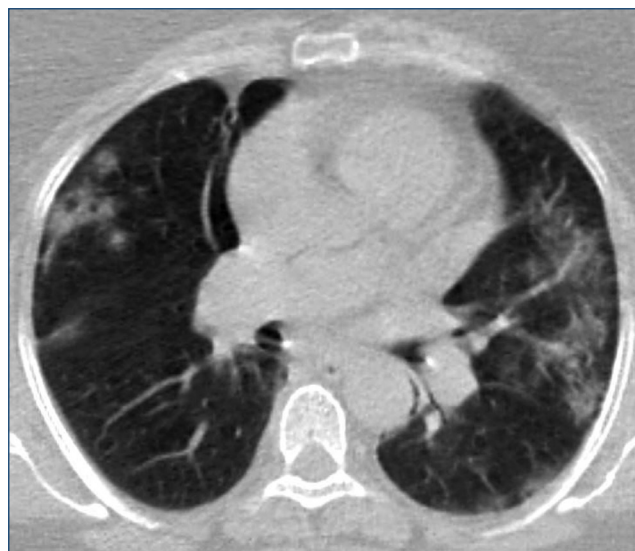


Figure 1. Thorax CT findings showing COVID-19 infiltration in the axial view.

RESULTS

In this study, we included only 116 PCR-negative patients, i.e., 64 (55.2%) men and 52 (44.8%) women, who had COVID-19 symptoms with a mean age of 49.78±12.96 years. COVID-19 symptoms were compared with the patients’ investigation results that were presented in Table 1 and the risk factors of lung involvement that were presented in Table 2. Chest CT

Table 1. COVID-19 symptoms comparisons with patients’ investigation results.

	SARS-CoV-2 IgG	
	Positive (n=95)	Negative (n=21)
Antibody titer (S/C)	6.59 (1.40–49.71)	0.16 (0.01–0.85)
p-value	<0.001	
Age (year)	50.08±12.35	48.43±15.72
p-value	0.654	
Gender		
Male	51 (53.7%)	13 (61.9%)
Female	44 (46.3%)	8 (38.1%)
p-value	0.493	
Lung involvement of chest CT findings		
<5%	29 (30.5%)	12 (57.1%)
≥5%	66 (69.5%)	9 (42.9%)
p-value	0.021	
Chest CT findings		
Typical COVID-19	80 (84.2%)	14 (66.7%)
Atypical COVID-19	15 (15.8%)	7 (33.3%)
p-value	0.073	

Data were presented as median (minimum-maximum), mean±standard deviation, and frequencies with percentages. IgG: immunoglobulin G; CT: computed tomography.

Table 2. Risk factors of lung involvement.

	OR (95%CI)	p-value
Age	1.08 (1.03–1.12)	<0.001
SARS-CoV-2 IgG		
Positive (reference category)		0.357
Negative	0.75 (0.40–1.39)	
Chest CT findings		
Inconsistent with COVID-19 (reference category)		0.010
Consistent with COVID-19	2.19 (1.21–3.96)	
Constant	0.022	<0.001
Hosmer-Lemeshow test		0.834
Omnibus test		<0.001

Nagelkerke R-square=0.310. CI: confidence interval; IgG: immunoglobulin G; CT: computed tomography.

findings did not have a statistically significant difference between SARS-CoV-2 IgG groups ($p=0.073$). Patients who had $\geq 5\%$ lung involvement were statistically significantly high in SARS-CoV-2 IgG positive group ($p=0.021$). Age, gender, and chest CT findings did not have a statistically significant difference between SARS-CoV-2 IgG groups ($p=0.654$, $p=0.493$, and $p=0.073$, respectively). Conversely, age and chest CT findings consistent with COVID-19 were the risk factors for lung involvement. As the age increased, the risk of $\geq 5\%$ lung involvement increased 1.08 times; while the chest CT findings were consistent with COVID-19, the risk of $\geq 5\%$ lung involvement increased 2.19 times compared to inconsistent with COVID-19 (OR (95%CI)=1.08 (1.03–1.12) $p<0.001$ and OR (95%CI)=2.19 (1.21–3.96) $p=0.010$, respectively).

In most of the patients with negative RT-PCR, there were typical chest CT findings consistent with COVID-19. However, atypical findings were also observed in some cases. In addition, we found no significant difference in anti-SARS-CoV-2 IgG antibody titers between the typical and atypical cases.

All patients were evaluated in terms of COVID-19 reinfection at 6 months. RT-PCR positivity was detected in three patients. Of these, anti-SARS-CoV-2 IgG negativity was detected in two patients, despite RT-PCR positivity. In the other patient, anti-SARS-CoV-2 IgG antibody titers were significantly higher (6.18 S/C) at the time of diagnosis as confirmed by RT-PCR positivity. However, as the antibody testing was performed after the diagnosis of COVID-19, it remained unclear whether antibody production occurred after the initial infection.

DISCUSSION

Several reports in the literature have shown viral pneumonia based on clinical and/or chest CT findings, despite having RT-PCR negativity using oropharyngeal and nasopharyngeal swabs. In parallel with the practices of the world, these patients were considered probable COVID-19 cases and treated with current treatment protocols in the in-hospital setting. This study evaluated the possible relationship between anti-SARS-CoV-2 IgG levels and thoracic CT findings⁹⁻¹¹. Our study results showed that 81.9% of the probable COVID-19 cases had significantly higher anti-SARS-CoV-2 IgG titers 6 months after the diagnosis. These results indicate that a negative RT-PCR test result does not exclude the possibility of COVID-19 and that a high number of probable COVID-19 cases are, indeed, COVID-19-positive cases. In addition, we observed antibody production in the probable COVID-19 cases at 6 months, despite negative RT-PCR results, and anti-SARS-CoV-2 IgG titers remained high in 81.9% of the cases.

Dimeglio et al.¹² reported that 30 patients had positive chest findings with a negative RT-PCR test result. Two months after the symptom onset, 14.3% of these patients had positive anti-SARS-CoV-2 antibodies. The authors suggested that non-COVID-19 pneumonia should be investigated in these patients. However, this finding can be attributed to this study's low number of RT-PCR-negative patients. In addition, non-COVID-19 pneumonia cases were not excluded from the study, and clinical evaluation was performed later. Unlike this study, we observed anti-SARS-CoV-2 IgG antibody positivity in most probable COVID-19 cases, indicating that these patients recovered from COVID-19.

In April 2020, a group of radiologists from the University of Southern California proposed a 5-point scale of suspicion (low, moderate, and high) for pulmonary involvement of COVID-19 on thoracic CT, namely, the COVID-19 imaging reporting and data system (COVID-RADS)¹¹⁻¹². According to this scheme, probable COVID-19 patients may present with typical and atypical chest CT findings¹³. Our study's relatively high number of patients may have provided sufficient power to achieve reliable statistical results. Of note, our findings are consistent with the report of De Smet et al.¹⁴.

In this study, we compared the chest CT findings of patients with $< 5\%$ lung involvement versus $\geq 5\%$ lung involvement to elucidate the effect of lung involvement on anti-SARS-CoV-2 IgG antibodies and titers. A significantly higher number of patients with anti-SARS-CoV-2 IgG positivity with high antibody titers had $\geq 5\%$ lung involvement. Based on these findings, we can speculate that antibody production and titers may be high in patients with severe COVID-19 infection. Also, anti-SARS-CoV-2 antibodies may persist after infection even in the long term, although it is an issue to be elucidated due to the scarcity of data in the literature.

Furthermore, our study evaluated all patients in terms of COVID-19 reinfection at 6 months. RT-PCR positivity was detected in three patients. In these cases, the RT-PCR test results were positive using nasopharyngeal swabs. Despite RT-PCR negativity at the time of the initial admission, reinfection was confirmed by RT-PCR positivity. Similarly, previous studies have shown varying amounts of RT-PCR positivity using nasopharyngeal swabs³⁻⁶. In two of three patients, anti-SARS-CoV-2 IgG negativity was detected. In the other patient, anti-SARS-CoV-2 IgG antibody titers were significantly higher at the time of diagnosis, as confirmed by RT-PCR positivity. Consistent with our findings, the COVID-19 reinfection rate was reported as 1.09/10,000 in antibody-negative cases and 0.13/10,000 in antibody-positive cases in the literature¹⁵. Ozturk et al. did a retrospective study on 320 patients

who had COVID-19 symptoms and were admitted to the hospital. The importance of this study was to show the accurate and equivalent performance of serological antibody assays and chest CT in diagnosing COVID-19 within 0–7 days from the onset of COVID-19 symptoms¹⁶.

CONCLUSION

This study is valuable as it highlights the evidence that increasing severity ($\geq 5\%$) of chest CT findings of lung involvement appears to be associated with high and persistent anti-SARS-CoV-2 IgG antibody titers 6 months after patients' discharge. In conclusion, even if the RT-PCR test is negative, anti-SARS-CoV-2 specific

IgG positivity may indicate previous evidence of COVID-19. After 6 months, high SARS-CoV-2 IgG titers can predict the rate of lung parenchymal involvement in probable cases of COVID-19 with negative PCR testing.

AUTHORS' CONTRIBUTIONS

IY: Data curation, Formal analysis, Writing – review & editing. **CK:** Data curation, Writing. **BS:** Data curation, Formal analysis, Software. **MK:** Data curation, Writing – original draft. **MT, BD:** Data curation, Supervision. **MZ, HO:** Data curation, Writing – review & editing. **OT:** Formal analysis. **MC:** Conceptualization, Data curation, Methodology, Writing – review & editing.

REFERENCES

- Lau CS, Oh HML, Hoo SP, Liang YL, Phua SK, Aw TC. Performance of an automated chemiluminescence SARS-CoV-2 IG-G assay. *Clin Chim Acta*. 2020;510:760-6. <https://doi.org/10.1016/j.cca.2020.09.005>
- Böger B, Fachi MM, Vilhena RO, Cobre AF, Tonin FS, Pontarolo R. Systematic review with meta-analysis of the accuracy of diagnostic tests for COVID-19. *Am J Infect Control*. 2021;49(1):21-9. <https://doi.org/10.1016/j.ajic.2020.07.011>
- Arevalo-Rodriguez I, Buitrago-Garcia D, Simancas-Racines D, Zambrano-Achig P, Del Campo R, Ciapponi A, et al. False-negative results of initial RT-PCR assays for COVID-19: a systematic review. *PLoS One*. 2020;15(12):e0242958. <https://doi.org/10.1371/journal.pone.0242958>
- Yang Y, Yang M, Shen C, Wang F, Yuan J, Li J, et al. Evaluating the accuracy of different respiratory specimens in the laboratory diagnosis and monitoring the viral shedding of 2019-nCoV infections. *medRxiv* 2020.02.11.20021493. <https://doi.org/10.1101/2020.02.11.20021493>
- Wang W, Xu Y, Gao R, Lu R, Han K, Wu G, et al. Detection of SARS-CoV-2 in different types of clinical specimens. *JAMA*. 2020;323(18):1843-4. <https://doi.org/10.1001/jama.2020.3786>
- Patel R, Babady E, Theel ES, Storch GA, Pinsky BA, St George K, et al. Report from the American Society for Microbiology COVID-19 International Summit, 23 March 2020: Value of Diagnostic Testing for SARS-CoV-2/COVID-19. *mBio*. 2020;11(2):e00722-20. <https://doi.org/10.1128/mBio.00722-20>
- Lou B, Li TD, Zheng SF, Su YY, Li ZY, Liu W, et al. Serology characteristics of SARS-CoV-2 infection after exposure and post-symptom onset. *Eur Respir J*. 2020;56(2):2000763. <https://doi.org/10.1183/13993003.00763-2020>
- Zhong L, Chuan J, Gong B, Shuai P, Zhou Y, Zhang Y, et al. Detection of serum IgM and IgG for COVID-19 diagnosis. *Sci China Life Sci*. 2020;63(5):777-80. <https://doi.org/10.1007/s11427-020-1688-9>
- Ai T, Yang Z, Hou H, Zhan C, Chen C, Lv W, et al. Correlation of chest CT and RT-PCR testing for coronavirus disease 2019 (COVID-19) in China: a report of 1014 cases. *Radiology*. 2020;296(2):E32-E40. <https://doi.org/10.1148/radiol.2020200642>
- Lin L, Fu G, Chen S, Tao J, Qian A, Yang Y, et al. CT manifestations of coronavirus disease (COVID-19) pneumonia and influenza virus pneumonia: a comparative study. *AJR Am J Roentgenol*. 2021;216(1):71-9. <https://doi.org/10.2214/AJR.20.23304>
- Salehi S, Abedi A, Balakrishnan S, Gholamrezanezhad A. Coronavirus disease 2019 (COVID-19) imaging reporting and data system (COVID-RADS) and common lexicon: a proposal based on the imaging data of 37 studies. *Eur Radiol*. 2020;30(9):4930-42. <https://doi.org/10.1007/s00330-020-06863-0>
- Dimeglio C, Collot S, Abravanel F, Sauné K, Lhomme S, Faruch M, et al. Diagnosis options in patients suffering from COVID-19-like symptoms. *J Med Virol*. 2021;93(7):4076-7. <https://doi.org/10.1002/jmv.26724>
- Li K, Wu J, Wu F, Guo D, Chen L, Fang Z, et al. The clinical and chest CT features associated with severe and critical COVID-19 pneumonia. *Invest Radiol*. 2020;55(6):327-31. <https://doi.org/10.1097/RLI.0000000000000672>
- De Smet K, De Smet D, Ryckaert T, Laridon E, Heremans B, Vandenbulcke R, et al. Diagnostic performance of chest CT for SARS-CoV-2 infection in individuals with or without COVID-19 symptoms. *Radiology*. 2021;298(1):E30-E37. <https://doi.org/10.1148/radiol.2020202708>
- Lumley SF, O'Donnell D, Stoesser NE, Matthews PC, Howarth A, Hatch SB, et al. Antibody status and incidence of SARS-CoV-2 infection in health care workers. *N Engl J Med*. 2021;384(6):533-40. <https://doi.org/10.1056/NEJMoa2034545>
- Ozturk A, Bozok T, Bozok TS. Evaluation of rapid antibody test and chest computed tomography results of COVID-19 patients: a retrospective study. *J Med Virol*. 2021;93(12):6582-7. <https://doi.org/10.1002/jmv.27209>

