

From the outset we maintained a broad differential. Given the presenting features, stroke, encephal meningitis and Covid-19 infection were at the forefront of our differential. She was empirically treated with IV acyclovir, ceftriaxone and dexamethasone while awaiting results of lumbar puncture. Following diagnosis she continued on acyclovir alone. This patient gradually recovered with no residual symptoms although she reported retrograde amnesia of her initial presentation. Follow up MRI showed a resolving process.

### Discussion

Herpes Simplex virus (HSV) is responsible for 19% of cases of infectious encephalitis.[1] It represents significant morbidity and mortality to patients with a one year mortality rate of 14%. [2] Typically, patients present with symptoms of fever, headache and confusion although speech disturbance can be seen in 57% and focal neurological deficit in 26% of cases.[3] Encephalitis is a known mimic of stroke and atypical presentations can often be misdiagnosed. In some cases this has led to inappropriate treatment with alteplase and in others misdiagnosis can lead to delay in initiating appropriate treatment.[4]

The emergence of Covid-19 has further confounded this area. Neurological manifestations of Covid-19 can be seen in up to 25% of patients.[5] On MRI, unilateral medial temporal lobe oedema, a recognised finding in HSV encephalitis, has been demonstrated in patients with Covid-19 in the absence of HSV.[6] This overlap in features risk delay in initiation of correct treatment for patients.

We feel this case is of particular interest as it highlights the importance of maintaining an open mind when managing a patient who has an atypical combination of symptoms particularly in the context of the current pandemic.

Traynor R<sup>1</sup>, Shanahan B<sup>1</sup>, Walsh J1, Ryan A<sup>1,2</sup>, Pope G<sup>1,3</sup>

1. University Hospital Waterford

2. Department of Radiology

3. Department of Medicine for the Elderly

**Corresponding author:** Dr Robyn Traynor

**Email:** robyn.traynor@ucdconnect.ie

### REFERENCES

1. Granerod J, Ambrose HE, Davies NW, Clewley JP, Walsh AL, Morgan D, UK Health Protection Agency (HPA) Aetiology of Encephalitis Study Group, *et al.* Causes of encephalitis and differences in their clinical presentations in England: a multicentre, population-based prospective study. *Lancet Infect Dis.* 2010;10(12):835-44.
2. Hjalmarsson A, Blomqvist P, Sköldenberg B. Herpes simplex encephalitis in Sweden, 1990-2001: incidence, morbidity, and mortality. *Clin Infect Dis.* 2007;45(7):875-80.
3. Sili U, Kaya A, Mert A, Group HSVES. Herpes simplex virus encephalitis: clinical manifestations, diagnosis and outcome in 106 adult patients. *J Clin Virol* 2014;60:112-118.
4. Shalchi Z, Bennett A, Hargroves D, Nash J. Diagnostic delay in a case of herpes simplex encephalitis. *BMJ Case Rep.* 2009;2009:bcr12.2008.1350. doi: 10.1136/bcr.12.2008.1350. Asadi-Pooya AA, Simani L. Central nervous system manifestations of COVID-19: A systematic review. *J*

*Neurol Sci.* 2020;413:116832. doi: 10.1016/j.jns.2020.116832. Kremer S, Lersy F, de Sèze J, Ferré JC, Maamar A, Carsin-Nicol B, *et al.* Brain MRI findings in severe COVID-19: a retrospective observational study. *Radiol.* 2020; 297(2): E242-E251. doi: 10.1148/radiol.2020202222.

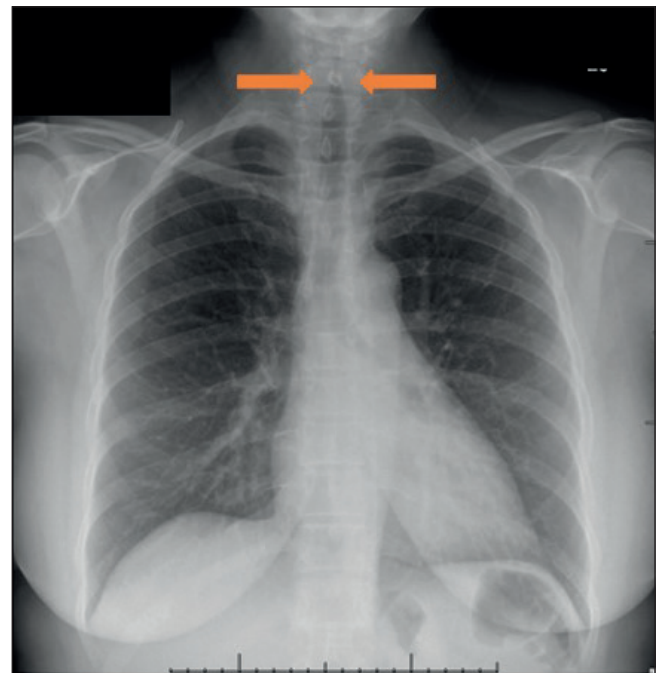
## LARYNGOTRACHEBRONCHITIS, CROUP, AN UNUSUAL PRESENTATION OF SARS-COV-2

### Editor

Laryngotracheobronchitis or croup, whilst common in childhood, is rare in adults. We present an unusual clinical presentation of infection with Sars-COV-2, COVID-19 Laryngotracheobronchitis.

A 52-year-old female presented to the Emergency Department with a three day history of progressive fatigue, hoarseness and dysphagia. On examination she was sitting forward, breathing quietly, aphonic and drooling. She had mild bilateral cervical lymphadenopathy. Flexible nasendoscopy showed mild supraglottic oedema and erythema, but no airway compromise. Chest xray demonstrated “steeple sign” (Figure 1) indicative of laryngotracheobronchitis or “croup.”

She had a mild inflammatory response demonstrated by a



**Figure 1.**

Erect Chest X-ray of the patient demonstrating the typical “steeple sign associated with laryngotracheobronchitis

C-Reactive Protein of 15mg/L. There were no symptoms to necessitate a COVID-19 test had she not attended hospital, however her polymerase chain reaction (PCR) for SARS-CoV-2 resulted positive, with viral PCR for Influenza A & B, and Respiratory Syncytial Virus (RSV) all negative. The presumed diagnosis was of COVID-19 Laryngotracheobronchitis. Treatment was supportive, in the form of intravenous fluids, humidified oxygen and intravenous

corticosteroids to reduce airway oedema. Following 24 hours the patient improved clinically, and flexible nasoendoscopy revealed resolution of supraglottic oedema. The patient was discharged with a five day course of oral dexamethasone.

Laryngotracheobronchitis, commonly referred to as croup, is an upper respiratory tract infection, almost exclusively seen in the paediatric population. It commonly presents with fever, “barking” cough, stridor, dyspnoea, and hoarseness. Adult croup is more severe than in the paediatric cohort, and often requires aggressive treatment and longer hospital stays<sup>1</sup>. Direct evidence of oedema, and the typical “steeple sign” feature on x-ray, which represents subglottic narrowing, is more commonly found in adults<sup>1</sup>. The most common pathogen amongst children is Parainfluenza virus type-1, however RSV and adenovirus are also commonly isolated<sup>2</sup>. In adults culprit organisms leading to croup include Parainfluenza, Haemophilus influenzae, Influenza, Streptococcus, and RSV<sup>1</sup>. Mainstay therapy is guided by severity of symptoms. Humidified oxygen, corticosteroids and nebulised adrenaline are all recommended in moderate to severe croup in children. In adults there are no formal recommended treatments, however all reported cases have used a combination of treatments recommended in paediatric croup.

COVID-19 infection, caused by SARS-CoV-2 virus has infected over 200 million people, resulting in over 4 million deaths worldwide to date. The majority of healthy individuals are thought to remain asymptomatic, however those presenting with symptoms related to COVID-19 typically experience fever, cough, and loss of taste and smell. In more severe cases respiratory compromise may occur, requiring invasive respiratory support. There is very little evidence in the literature of upper airway oedema related to infection with COVID-19, with only 4 reports of croup in COVID-19 positive children<sup>3</sup>.<sup>4</sup>. To date there are only two documented cases of COVID-19 related laryngotracheobronchitis in adults<sup>5</sup>. Despite the relatively indolent clinical course of the patient herein described, timely diagnosis and early intervention could prove to be critical in preventing airway compromise in patients presenting with COVID-19 infection of the upper respiratory tract.

Zuccarelli AM, Leonard CG, Hampton SM

Corresponding author: Dr Andrea Zuccarelli  
Royal Victoria Hospital  
Belfast

**Email:** andrea.zuccarelli@gmail.com

## REFERENCES

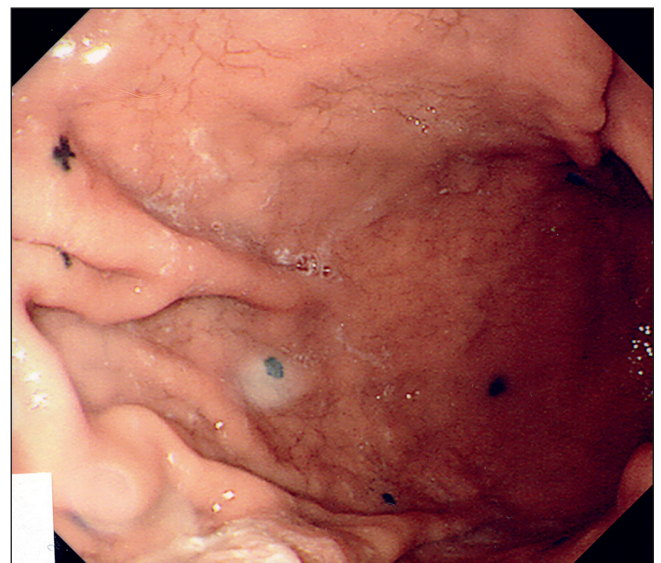
1. Patel JJ, Kitchin E, Pfeifer K. A narrowing diagnosis: a rare cause of adult croup and literature review. *Case Rep Crit Care*. 2017;2017:9870762. doi: 10.1155/2017/9870762.
2. Zoorob R, Sidani M, Murray J. Croup: an overview. *Am Fam Physician*. 2011;83(9):1067-73.
3. Venn AM, Schmidt JM, Mullan PC. Pediatric croup with COVID-19. *Am J Emerg Med*. 2021;43(1):287.e1-287.e3. doi: 10.1016/j.ajem.2020.09.034.
4. Pitstick CE, Rodriguez KM, Smith AC, Herman HK, Hays JF, Nash CB. A curious case of croup: laryngotracheitis caused by COVID-19. *Pediatric*. 2021;147(1):e2020012179. doi: 10.1542/peds.2020-012179.
5. Oliver CM, Campbell M, Dulan O, Hamilton N, Birchall M. Appearance and management of COVID-19 laryngo-tracheitis: two case reports [Version 2; Peer reviewed: 2 approved]. *F1000Res*. 2020;9:310

## MELANOMA: MORE THAN SKIN DEEP

### Editor,

Melanoma is the 5<sup>th</sup> most common cancer in the UK, with approximately 40 people receiving a new diagnosis daily. It is deemed the most serious of skin cancers due to its propensity to metastasise widely, which can affect all organ systems including the gastrointestinal tract (GIT). We present three cases of metastatic melanoma who presented with gastrointestinal (GI) symptoms within a three month period to a tertiary centre.

A 72 year old man had a previous history of cutaneous melanoma, treated with wide local excision, three years prior to the current presentation. He presented with melaena, symptomatic anaemia and abnormalities of his small bowel were noted on CT abdomen. Upper GI endoscopy identified multiple small black tumour deposits (Figure 1A). Follow up MR enterography confirmed several small bowel



**Figure 1A** Multiple small black deposits of metastatic melanoma in the gastric mucosa at endoscopy (Patient 1)

lesions which were suspicious for metastatic disease. He subsequently developed small bowel obstruction secondary to intussusception and proceeded to have a small bowel resection. Three separate tumours were removed and histology confirmed metastatic melanoma.

A 66 year old man was referred to the GI outpatient service with symptomatic anaemia, intermittent change in bowel habit and weight loss. CT imaging identified an abnormal gallbladder mass. Subsequent MRI confirmed a 5.6cm mass arising from the gallbladder. Following laparotomy this was identified as a malignant melanoma. Whereas primary gallbladder mucosal melanomas have been reported they are extremely rare, and a metastasis was considered more likely.

A 75 year old man gave a history of melanoma removed by wide local excision from his anterior abdominal wall 15 years previously. He presented to the Emergency Department with melaena and iron deficiency anaemia was noted. Upper GI endoscopy was normal. CT imaging revealed thickening at the duodeno-jejunal junction. At enteroscopy an ulcerated tumour



UMJ is an open access publication of the Ulster Medical Society (<http://www.ums.ac.uk>).

The Ulster Medical Society grants to all users on the basis of a Creative Commons Attribution-NonCommercial-ShareAlike 4.0 International Licence the right to alter or build upon the work non-commercially, as long as the author is credited and the new creation is licensed under identical terms.