

## One-stage Laparoscopic Repair of Morgagni and Inguinal Hernias in a Two-month Old Male

Mi Ju Bae, M.D.<sup>1,2</sup>, Hoseok I, M.D., Ph.D.<sup>1,2</sup>, Dae Hwan Kim, M.D.<sup>3</sup>, Yeon Joo Jeong, M.D.<sup>4</sup>,  
Yeong Dae Kim, M.D., Ph.D.<sup>1,2</sup>, Jeong Su Cho, M.D.<sup>1,2</sup>

The development of Morgagni hernias is related to malformations of the embryologic septum transversum after failure of the sternal and costal fibrotendinous elements of the diaphragm to fuse. The overall incidence of Morgagni hernias among all congenital diaphragmatic defects is 3% to 4%. Inguinal hernias are the most common hernias in males and females (25% and 2%, respectively). An inguinal hernia is defined as a protrusion of the abdominal cavity contents through the inguinal canal. The combination of Morgagni and inguinal hernias is rare, and treatment using laparoscopic surgery has not been previously reported. This case presents a one-stage laparoscopic repair of Morgagni and inguinal hernias in a 2-month-old male.

Key words: 1. Minimally invasive surgery  
2. Diaphragm  
3. Hernia  
4. Infant

### CASE REPORT

A 45-day-old male weighing 4,030 g with a length of 54.8 cm presented to the hospital with unexplained persistent irritability and decreased feeding. A plain chest X-ray showed an abnormal air shadow below the sternum (Fig. 1). The patient was the second born of twins at 36 weeks and five days of gestation. His birth weight was 2,070 g. The right inguinal hernia was treated with surgery 33 days after birth at another hospital. The Morgagni diaphragmatic hernia and left inguinal hernia were diagnosed using computed tomography of the chest and abdomen (Fig. 1).

An operation was performed 66 days after birth, at that

time the patient's weight was 4,100 g. A one-stage laparoscopic repair was planned to repair the Morgagni and left inguinal hernias. Under general anesthesia, the patient was placed in the supine position. Three trocars were inserted (Fig. 2). A 3.5 cm diaphragmatic defect was found behind the sternum. The transverse colon was herniated through the diaphragmatic defect, which did not have an anterior rim. The hernial sac was well formed. The small bowel was herniated through the left internal inguinal ring. The transverse colon with the hernia sac was pushed back into the abdominal cavity, and then the hernia sac was removed. The diaphragmatic defect was repaired primarily with 2-0 black silk interrupted sutures. The small bowel was reduced, and the internal in-

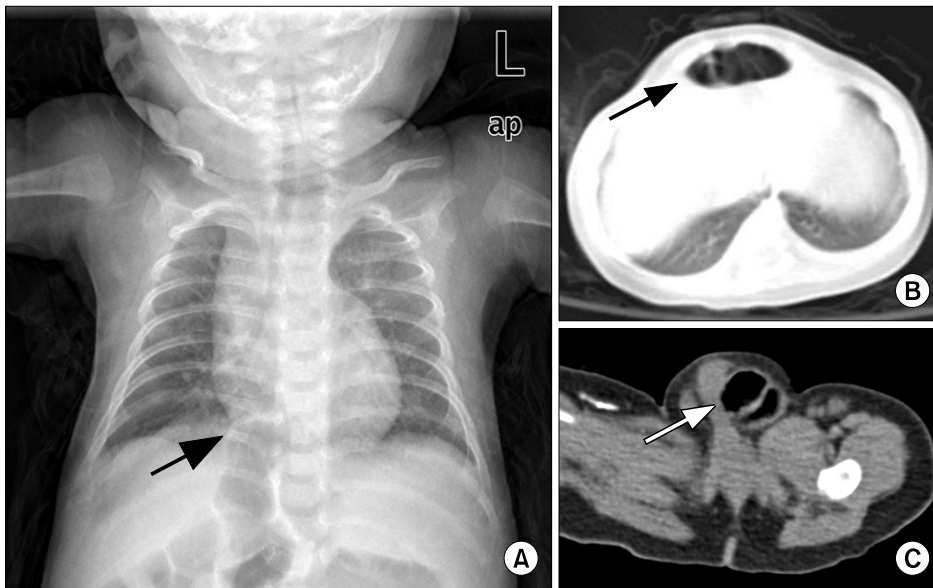
<sup>1</sup>Department of Thoracic and Cardiovascular Surgery, Pusan National University Hospital, Pusan National University School of Medicine, <sup>2</sup>Pusan National University Medical Research Institute, Departments of <sup>3</sup>Surgery and <sup>4</sup>Radiology, Pusan National University Hospital, Pusan National University School of Medicine

Received: June 12, 2012, Revised: July 24, 2012, Accepted: August 16, 2012

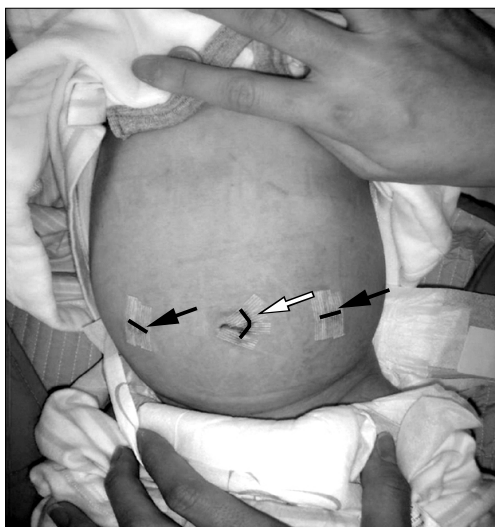Corresponding author: Hoseok I, Department of Thoracic and Cardiovascular Surgery, Pusan National University Hospital, Pusan National University School of Medicine, 179 Gudeok-ro, Seo-gu, Busan 602-739, Korea  
(Tel) 82-51-240-7267 (Fax) 82-51-243-9389 (E-mail) ihoseok@hotmail.com

© The Korean Society for Thoracic and Cardiovascular Surgery. 2012. All right reserved.

© This is an open access article distributed under the terms of the Creative Commons Attribution Non-Commercial License (<http://creativecommons.org/licenses/by-nc/3.0>) which permits unrestricted non-commercial use, distribution, and reproduction in any medium, provided the original work is properly cited.



**Fig. 1.** (A) An infantogram shows abnormally located bowel shadows (black arrow) near the right cardiophrenic angle. (B) The lung window of the transverse chest computed tomography (CT) scan shows a herniated transverse colon (black arrow) through the foramina of the Morgagni hernia, which are located adjacent to the xiphoid process of the sternum. (C) A transverse abdomen CT scan shows that the small bowels (white arrow) protruded through the left inguinal canal.



**Fig. 2.** This picture shows surgical incisions. A camera port (white arrow) was made at the umbilicus, and another two ports (black arrows) were placed at the same level. White arrow: skin incision for 5 mm trocars. black arrow: skin incision for 10 mm trocar.

guinal ring was repaired with a 3-0 black silk purse-string suture. There were no complications during the operation. The patient was discharged uneventfully on postoperative day 7. At the 1 year follow-up, there was no recurrence of the hernias.

## DISCUSSION

The standard treatment for symptomatic Morgagni hernias is surgical repair using laparotomy or thoracotomy. Laparoscopic congenital diaphragmatic hernia repair in an infant was first reported by van der Zee [1]. Currently, using a laparoscopic approach to treat Morgagni or inguinal hernias has gained increasing popularity. There are a number of advantages of laparoscopic surgery including minimal pain due to smaller incisions and a short recovery time.

Laparoscopic surgeries for infants were first reported in the 1970s. However, the use of these procedures has been primarily for diagnostic purposes. The development of minimally invasive surgery (MIS) for infants and young children was first reported in the 1990s. However, the advancement of this technique has been significantly restricted due to the lack of pediatric-sized laparoscopic instruments. As the development and increased supply of laparoscopic instruments for small infants and children have become available, MIS has been more widely used in pediatric surgery [2]. Laparoscopy in infants and small children requires special care. There are potential problems with anesthesia such as decreased oxygen saturation, transient hypotension, hypercarbia, and respiratory acidosis due to insufflation with carbon dioxide gas. Because carbon dioxide insufflation can rapidly worsen the respiratory and hemodynamic conditions of small newborns, it is neces-

sary to select healthier newborns that can tolerate carbon dioxide insufflation [3].

There are specific surgical problems associated with laparoscopic surgery in infants such as difficulty of placement and stabilization of the trocar, difficulty of movement in the small abdominal cavity, and the fact that the abdominal wall is very flexible. For these reasons, Iwanaka et al. [4] reported a high rate of visceral injuries in small infants. Even though special attention is needed for such patient groups, good result have been published previously [3].

In the current case, the patient was only in the third percentile of standard growth in Korea. Despite his small size, he was hemodynamically stable and had stable respiratory function. If he had undergone open surgery, he would have required separate or longer incisions for both hernias. For this reason, one-stage laparoscopic repair of the Morgagni and inguinal hernias was used.

Typically, the location of the ports, in thoracoscopic or laparoscopic surgery, is made according to the baseball diamond concept of triangulation of the instruments and scope. In the current case, two trocars for the instruments were inserted at the same level of the camera port (paraumbilical) (Fig. 2). These port locations allowed for the correction of both hernias on the cephalad and caudad position of the camera port. In this small infant with a Morgagni and inguinal hernia, one-stage laparoscopic surgery can be performed without

making an additional incision line depending on the location of the ports.

#### CONFLICT OF INTEREST

No potential conflict of interest relevant to this article was reported.

#### ACKNOWLEDGMENTS

This work was supported by a 2-year research grant of Pusan National University.

#### REFERENCES

1. van der Zee DC, Bax NM. *Laparoscopic repair of congenital diaphragmatic hernia in a 6-month-old child.* Surg Endosc 1995;9:1001-3.
2. Lee KH, Yeung CK. *Laparoscopic surgery in newborns and infants: an update.* HK J Paediatr 2003;8:327-35.
3. Gomes Ferreira C, Reinberg O, Becmeur F, et al. *Neonatal minimally invasive surgery for congenital diaphragmatic hernias: a multicenter study using thoracoscopy or laparoscopy.* Surg Endosc 2009;23:1650-9.
4. Iwanaka T, Uchida H, Kawashima H, Nishi A, Kudou S, Satake R. *Complications of laparoscopic surgery in neonates and small infants.* J Pediatr Surg 2004;39:1838-41.