

Case report

Meng Qi*, Ming Ye, Meng Li, Peng Zhang

Pituitary dysfunction from an unruptured ophthalmic internal carotid artery aneurysm with improved 2-year follow-up results: A case report

<https://doi.org/10.1515/med-2018-0021>

received December 11, 2017; accepted March 12, 2018

Abstract: Internal carotid artery (ICA) supraclinoid segment aneurysms extending into the sellar region and leading to pituitary dysfunction are a rare occurrence. To date, long-term follow up of pituitary function 2 years post-treatment has never been reported. Herein, we present a case of pituitary dysfunction due to an unruptured ophthalmic segment internal carotid artery aneurysm and report improved 2-year follow-up results. A 76-year-old male presented with disturbed consciousness due to hyponatremia, which was caused by hypoadrenocorticism resulting from pituitary dysfunction complicated by hypogonadism and hypothyroidism. Computed tomography angiography revealed an intracranial aneurysm of the ophthalmic segment of the right ICA with an intrasellar extension. Thus, digital subtraction angiography and coil embolization were performed, followed by hormone replacement therapy. A 2-year follow-up revealed a partial improvement in the pituitary function, including complete restoration of thyroid-stimulating hormone level and other thyroid hormones levels, and partial restoration of testosterone levels, followed by discontinuation of thyroid hormone replacement therapy. However, the mechanisms of such pituitary dysfunction and the effects of various treatments, including clipping and coiling, on different hormones of pituitary function recovery remain unclear. A long-term follow-up of >2 years may elucidate the pituitary function recovery post-treatment and provide a medication adjustment for hormone replacement therapy.

Keywords: Coil embolization; Large intracranial aneurysm; Pituitary dysfunction; Supraclinoid segment of internal carotid artery; Sellar mass

1 Introduction

The occurrence of intracranial aneurysms extending into the sellar region and resulting in pituitary dysfunction is relatively rare. A large cohort study of more than 4000 patients with hypopituitarism at the Mayo Clinic reported that a prevalence of <0.2% pituitary dysfunction attributed to a sellar aneurysm [1]. To the best of our knowledge, only two cases of an unruptured internal carotid artery (ICA) supraclinoid segment aneurysm leading to pituitary dysfunction have been reported to date [2,3]. Herein, we present a case, which would be an addition to the previously reported cases of pituitary dysfunction due to an intracranial supraclinoid aneurysm, and report improved results with an extended 2-year follow-up.

2 Case report

A 76-year-old male was admitted to our hospital because of disturbed consciousness due to hyponatremia two months before admission. His medical history comprised hypertension with good control under medication without diabetes and other complicated diseases. Magnetic resonance imaging (MRI) revealed a sellar mass that was considered to be a large intracranial aneurysm (Fig. 1a). Computed tomography angiography (CTA) as well as digital subtraction angiography (DSA) revealed a right ICA supraclinoid segment aneurysm (Figs. 1b and 2a). The patient's endocrine profile suggested a severe decline of testosterone, and decrease of AM cortisol, luteinizing hormone, estradiol, thyroid-stimulating hormone (TSH),

*Corresponding author: Meng Qi, Department of Neurosurgery, Xuanwu Hospital, Capital Medical University, China, E-mail: qimeng83@aliyun.com

Ming Ye, Meng Li, Peng Zhang, Department of Neurosurgery, Department of Interventional Radiology, Xuanwu Hospital, Capital Medical University, China

free T3 (FT3) and free T4 (FT4; free thyroxine) levels and elevation in prolactin levels (Table 1). Before admission to our department, the patient received sodium supplement and hormone replacement therapy with hydrocortisone and testosterone at a local hospital, leading to recovery from the disturbed consciousness. In addition, levothyroxine was prescribed for thyroid hormone replacement, and bromocriptine was not prescribed because of marginal elevation of prolactin.

At our hospital, we performed placement of coils into the aneurysm for treatment (Fig. 2b) 7 days after admission followed by a continued hydrocortisone, levothyroxine, and testosterone replacement therapy. The post-treatment recovery of the patient was unremarkable without any neurological deficit. Furthermore, we performed a 2-year follow-up to check the patient's hormone levels (Table 1) and observed an improvement in the levels of testosterone (partial), TSH (complete), FT3 (complete), and FT4 (complete), but not in those of other examined hormones. Eventually, levothyroxine was discontinued for complete restoration of thyroid hormone levels.

Informed consent: Informed consent has been obtained from the participant included in the study.

Ethical approval: The research related to human use has complied with all the relevant national regulations, institutional policies, and is in accordance to the tenets of the Helsinki Declaration, and has been approved by the authors' institutional review board or equivalent committee.

3 Discussion

Previous literature reported that aneurysms projecting into the sellar region account for <2% of all intracranial aneurysms [1]. Hanak *et al.* [4] classified intrasellar aneurysms into two types: (a) infradiaphragmatic, arising from the cavernous/clinoid segment ICA with medial extension into the sella; and (b) supradiaphragmatic, arising from the ophthalmic segment of ICA or anterior communicating artery with inferomedial extension into the sella. Our presented case belonged to the latter group, arising from the ophthalmic segment of ICA close to the origin of the anterior choroidal artery. In addition, pituitary dysfunction caused by a sellar aneurysm is relatively rare with a reported prevalence of 0.17% in a large cohort of over 4000 patients with hypopituitarism [1]. The aneurysm extended into the carotid cave and suprasellar region resulting in the mechanical compression of the pituitary stalk and gland or vascular compression of the artery supplying the pituitary gland, leading to pituitary ischemia [5,6], and causing pituitary dysfunction that manifested in the serum hormone levels of patients. It is reported that the leading endocrine insufficiencies are hyperprolactinemia and hypogonadism [4], and our patient apparently had hypogonadism and slight hyperprolactinemia, in addition to obvious hypoadrenocorticism and hypothyroidism.

Typically, the treatment of intracranial aneurysms of significant size is challenging, and includes microsurgical operation and endovascular obliteration. Recovery of endocrine function is rare even postoperatively [6]. For the treatment of such aneurysms, clinicians have established clipping of the aneurysm, proximal occlusion or trapping

Table 1: Endocrine tests of hormones before treatment and 2 years after coiling of the aneurysm

Hormone type	Before treatment	2-year follow up	Normal reference
Morning cortisol	0.88↓	0.6↓	3.7-19.4ug/dL
Afternoon cortisol	1.13	2.0	<4ug/dL
FSH	1.69	4.36	1.27-19.26IU/L
LH	1.05↓	0.32↓	3.1-34.6IU/L
PRL	17.75↑	19.10↑	2.1-17.7ng/ml
TSH#	0.32↓	1.91	0.34-5.6 mIU/ml
Testosterone*	0.00↓↓↓	7.82↓↓	241-827ng/dL
Estradiol	16.00	3.19	0-39.8pg/ml
FT3#	1.89↓	3.19	2.77-6.31pmol/L
FT4#	9.28↓	11.21	10.53-24.57pmol/L

FSH, follicle-stimulating hormone; LH, luteinizing hormone; PRL, prolactin; TSH, thyroid-stimulating hormone; FT3, free T3; FT4, free thyroxine; ↓ decreased, ↑ elevated, more arrows mean severity, * partial or #full recovery of hormone after coiling compared to the same hormone before coiling

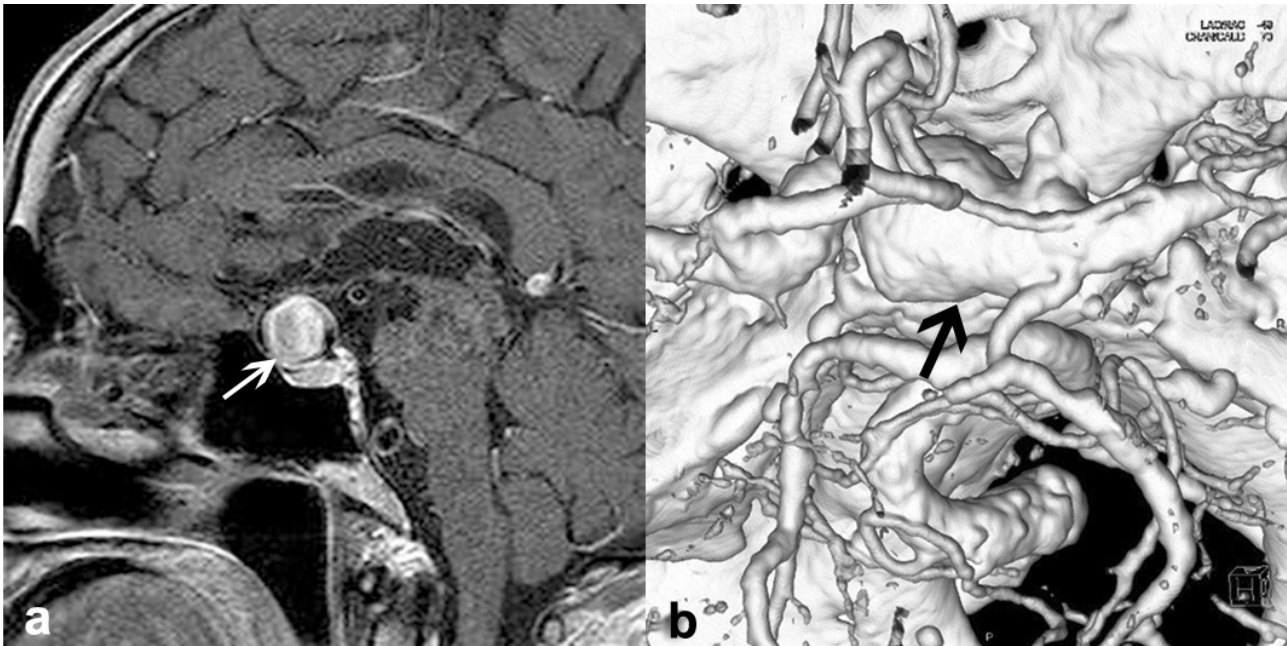


Figure 1: Pre-treatment magnetic resonance imaging (MRI) and computed tomography (CT) angiography of the aneurysm. MRI T1-weighted sequences mid-sagittal section with contrast (a) shows a large intrasellar lesion (white arrow) with an unusual pattern of enhancement, which is different from a pituitary adenoma and necessary for further investigation for an aneurysm. CT angiography 3D reconstruction (b) demonstrates a large right supraclinoid ICA aneurysm (black arrow) extending into the sellar region.

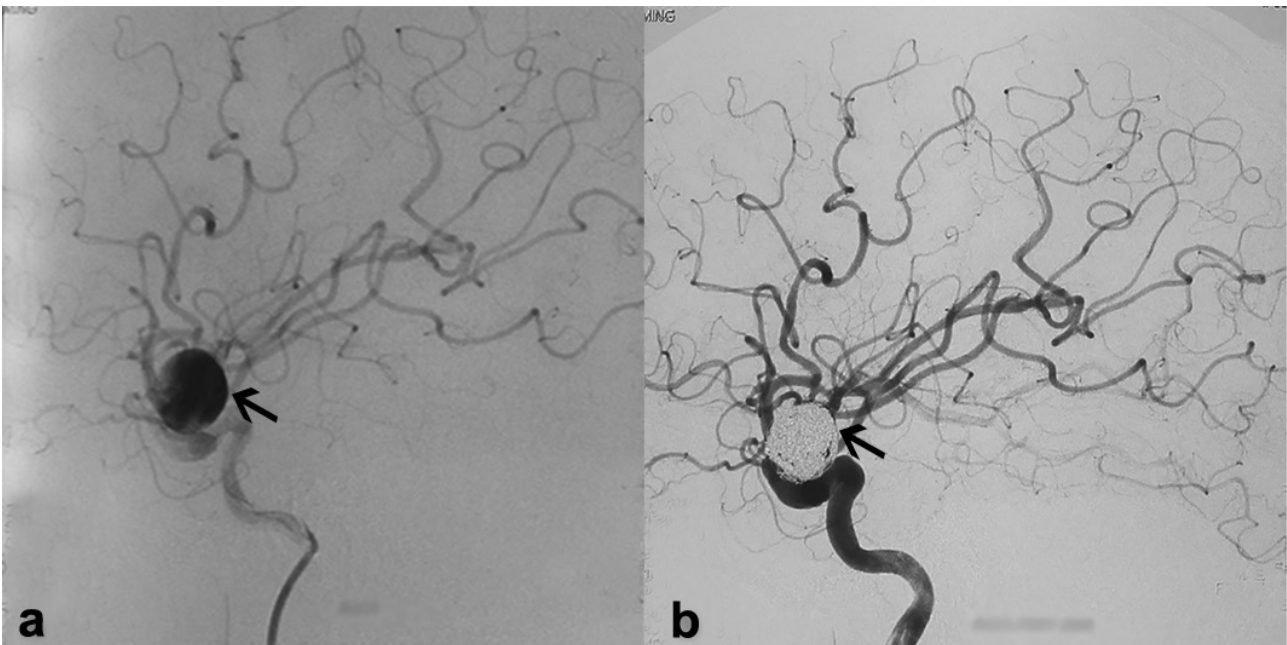


Figure 2: Digital subtraction angiography (DSA) of the aneurysm before and after coiling. DSA lateral projection of the aneurysm (left black arrow) pre-treatment (a) and after coiling (right black arrow) (b) shows the right ophthalmic segment internal carotid artery aneurysm.

with/without distal bypass, and coiling embolization with or without the assistance of balloon or stent. However, the compression to the pituitary gland persists because of the coils in the aneurysm, thus, necessitating the hormone replacement therapy [7, 8]. A flow diversion device with pipeline stent placement has also been reported for treat-

ment, with a certain rate of major complications such as major ipsilateral thrombosis, intraparenchymal hemorrhage, and neurologic death as well as delayed panhypopituitarism partly caused by a compromised blood supply to the pituitary gland because of the flow diversion to ICA [9-11].

To date, only two cases of supradiaphragmatic intrasellar aneurysms with pituitary insufficiency have been reported, which were treated by microsurgical clipping followed by resection or pipeline placement respectively [2,3]. In our case, the aneurysm had a narrow neck, which was suitable for embolization, and the patient was in his advanced age (76 years) at admission; thus, embolization with coils was selected as a prior treatment rather than surgery. In addition, we used coiling alone for treatment without stent placement in our patient.

Heshmati *et al.* reported that pituitary dysfunction secondary to an intrasellar aneurysm is usually permanent and unlikely to improve despite successful treatment of the aneurysm [1]. A 1-year follow-up of a supradiaphragmatic intrasellar aneurysm did not demonstrate recovery of the pituitary function [2]. Conversely, a 1-month follow-up of another patient with a supradiaphragmatic aneurysm and pituitary insufficiency exhibited excellent recovery with hormone supplementation; however, serum hormone levels were not specified in the follow-up [3]. In addition, an 8-year follow-up of a patient with pituitary dysfunction caused by a giant cavernous carotid aneurysm treated with high-flow bypass demonstrated pituitary function recovery and shrinkage of the aneurysm [12]. In our case, a 2-year follow-up of serum hormone levels performed without an intermediate-stage examination revealed complete or partial improvement of levels of certain hormones such as TSH, FT3, FT4, and testosterone. Notably, the complete restoration of TSH, FT3, and FT4 levels resulted in the discontinuation of levothyroxine administration. However, the mechanism of long-term pituitary dysfunction or the effects of microsurgical and endovascular treatment on the pituitary function recovery remain unclear. In addition, it remains unclear why levels of TSH and thyroid hormones restored to normal compared with those of other hormones. Nonetheless, pituitary hormone replacement could be prescribed with its synthetic equivalents, and reevaluation of hormone levels may suggest the medication adjustment for hormone replacement therapy. Therefore, a longer-term follow-up of >2 years may elucidate the condition of the pituitary function for this patient. In our patient, imaging tests such as CTA or DSA were not performed at follow-up, because of the denial of the family members considering the age of the patient (78 years at 2-year follow-up); thus, the post-treatment variation in the size of the aneurysm remains unknown.

Furthermore, the duration of pituitary insufficiency and the extent of pituitary compression may also play a role in the endocrine recovery after treatment [5]. While it cannot be precisely ascertained when hypopituitarism

started in our patient, his symptoms appeared approximately 2 months before endovascular treatment of the aneurysm, suggesting that this relatively short period may have been a favorable factor for the partial recovery of the pituitary function.

To date, pituitary dysfunction secondary to supraclinoid ICA aneurysms remains partially specified. While microsurgical or endovascular techniques can help treat aneurysms, pituitary dysfunction warrants the administration of synthetic equivalents for replacement of insufficient hormones. In addition, as the mechanisms of such type of pituitary dysfunction and the effect of various treatments on different hormones of pituitary function recovery remain unclear, a long-term follow-up of >2 years may yield more information about the post-treatment pituitary function recovery and suggest the medication adjustment for hormone replacement therapy.

Acknowledgement: This work was supported by a grant from Intramural Research Program of Basic and Clinical Study, Xuanwu Hospital, Capital Medical University and Beijing Municipal Human Resources and Social Security Bureau. The sponsors had no role in the design or conduct of this research.

Conflict of interest: Authors state no conflict of interest.

References

- [1] Heshmati HM, Fatourehchi V, Dagam SA, Piepgras DG. Hypopituitarism caused by intrasellar aneurysms. *Mayo Clin Proc*, 2001, 76(8): 789-793
- [2] Klose S, Kopf D, Lehnert H. Giant intrasellar carotid aneurysm - an unusual cause of panhypopituitarism. *Exp Clin Endocrinol Diabetes*, 2005, 113(9): 551-553
- [3] Ding D, Mehta GU, Liu KC. Pituitary insufficiency from large unruptured supraclinoid internal carotid artery aneurysm. *Br J Neurosurg*, 2014, 28(2): 290-292
- [4] Hanak BW, Zada G, Nayar VV, Thiex R, Du R, Day AL, *et al.* Cerebral aneurysms with intrasellar extension: a systematic review of clinical, anatomical, and treatment characteristics. *J Neurosurg*, 2012, 116(1): 164-178
- [5] Tan LA, Sandler V, Todorova-Koteva K, Levine L, Lopes DK, Moftakhar R. Recovery of pituitary function following treatment of an unruptured giant cavernous carotid aneurysm using Surpass flow-diverting stents. *J Neurointerv Surg*, 2015, 7(6): e20
- [6] Tungaria A, Kumar V, Garg P, Jaiswal AK, Behari S. Giant, thrombosed, sellar-suprasellar internal carotid artery aneurysm with persistent, primitive trigeminal artery causing hypopituitarism. *Acta Neurochir (Wien)*, 2011, 153(5): 1129-1133

- [7] Fernandez-Real JM, Fernandez-Castaner M, Villabona C, Sagarra E, Gomez-Saez JM, Soler J. Giant intrasellar aneurysm presenting with panhypopituitarism and subarachnoid hemorrhage: case report and literature review. *Clin Investig*, 1994, 72(4): 302-306
- [8] Gungor A, Gokkaya N, Bilen A, Bilen H, Akbas EM, Karadeniz Y, et al. Pituitary Insufficiency and Hyperprolactinemia Associated with Giant Intra- and Suprasellar Carotid Artery Aneurysm. *Case Rep Med*, 2015, Article ID 536191
- [9] Becske T, Kallmes DF, Saatci I, McDougall CG, Szikora I, Lanzino G, et al. Pipeline for uncoilable or failed aneurysms: results from a multicenter clinical trial. *Radiology*, 2013, 267(3): 858-868
- [10] Becske T, Potts MB, Shapiro M, Kallmes DF, Brinjikji W, Saatci I, et al. Pipeline for uncoilable or failed aneurysms: 3-year follow-up results. *J Neurosurg*, 2017, 127(1): 81-88
- [11] Hall J, Caputo C, Chung C, Holt M, Wang YY. Delayed pan-hypopituitarism as a complication following endovascular treatment of bilateral internal carotid artery aneurysms. A case report and review. *Br J Neurosurg*, 2015, 29(2): 303-305
- [12] Ono H, Inoue T, Kunii N, Tanishima T, Tamura A, Saito I, et al. Giant cavernous carotid aneurysm causing pituitary dysfunction: Pituitary function recovery with high-flow bypass. *Surg Neurol Int*, 2017, 8: 180