

The Mid-Term Efficacy and Safety of a Permanent Nitinol IVC Filter (TrapEase)

Wei Chiang Liu, MD¹
Young Soo Do, MD²
Sung Wook Choo, MD²
Dong-Ik Kim, MD³
Young Wook Kim, MD³
Duk-Kyung Kim, MD⁴
Sung Wook Shin, MD²
Kwang Bo Park, MD²
Yong Hwan Jeon, MD²
In-Wook Choo, MD²

Index terms:

Pulmonary thromboembolism
IVC Filter
IVC thrombosis

Korean J Radiol 2005; 6: 110-116

Received January 20, 2005; accepted
after revision April 2, 2005.

¹Department of Radiology, Sung-Ae General Hospital; ²Department of Radiology and Center for Imaging Science, Samsung Medical Center, Sungkyunkwan University School of Medicine; ³Department of Surgery, Cardiovascular Center, Samsung Medical Center, Sungkyunkwan University School of Medicine; ⁴Department of Internal Medicine, Cardiovascular Center, Samsung Medical Center, Sungkyunkwan University School of Medicine

Address reprint requests to:

Young Soo Do, MD, Department of Radiology and Center for Imaging Science, Samsung Medical Center Sungkyunkwan University School of Medicine, 50 Ilwon-dong, Kangnam-gu, Seoul 135-710, Korea.
Tel. (822) 3410-2518
Fax. (822) 3410-2559
e-mail: ysd0@smc.samsung.co.kr

Objective: 1) To evaluate the mid-term efficacy and safety of a permanent nitinol inferior vena cava (IVC) filter; 2) to evaluate filter effectiveness, filter stability and caval occlusion.

Materials and Methods: A prospective evaluation of the TrapEase IVC filter was performed on 42 patients (eight men, 34 women) ranging in age from 22 to 78 years (mean age 66 years). All patients were ill with a high risk of pulmonary embolism (PE). Indications for filter placement were: 1) deep vein thrombosis with recurrent thromboembolism; 2) and/or free-floating thrombus with contraindication to anticoagulation; and 3) complications in achieving adequate anticoagulation. Follow-up evaluations (mean: 15.4 months, range: 2 to 28 months) were performed at 6- and 12-month intervals after the procedure and included clinical histories, chart reviews, plain film, Doppler ultrasounds, and contrasted abdominal CT scans.

Results: In follow-up evaluations, the data analysis revealed no cases of symptomatic PE. There were no cases of filter migration, insertion site thrombosis, filter fracture, or vessel wall perforation. During the study, there was one case of filter thrombosis; early symptomatic thrombosis that was successfully treated in the hospital. Of the 42 subjects, eight died. These deaths were not related to the filter device or the implantation procedure, but to the underlying disease.

Conclusion: This study demonstrates that the TrapEase permanent IVC filter is a safe and an effective device with low complication rates and is best used in patients with thromboembolic disease with a high risk of PE.

Percutaneous filter placement to achieve a partial mechanical interruption of the inferior vena cava (IVC) is well established as a method of preventing life threatening pulmonary embolism (PE) caused by lower extremity deep vein thrombosis (DVT). The implantation of a permanent vena cava filter in the IVC is viewed largely as an alternative therapy when anticoagulation therapy in patients with thromboembolic disease fails or is contraindicated. Since its inception in 1967, the first IVC filter (1) has spawned various configurations that have been developed and subsequently improved in line with increased clinical applications and knowledge. However, an ideal filter device has yet to be developed. The long-term performance and small incidence of filter complications are particularly important in patients being considered for prophylactic IVC filter insertion. The nitinol permanent IVC filter (TrapEase; Cordis Europa, Roden, Netherlands) was designed with low profile (6-F) characteristics intended to ensure the protection of PE with a theoretically low risk of filter-associated complications. A multi-institutional study of the TrapEase filter reported a six month follow-up (2). Our experiences with the TrapEase filter

placement with a one year follow-up at a single institution are reported herein.

MATERIALS AND METHODS

Study Group

From April 2001 to August 2002, a TrapEase filter was placed into the inferior vena cava (IVC) of 48 consecutive patients. Of the 48 patients, four were lost to follow-up and two refused to complete study 42 patients (8 men, 34 women; mean age: 66, age range: 22–78 years) were prospectively enrolled into the study protocol. Clinical histories were evaluated for indication of filter placement. Pertinent coexisting medical and surgical conditions were recorded. This prospective study was approved by our Institutional Review Board. Written informed consent was obtained from all patients after the nature of the procedures was fully explained.

Study Endpoints

The primary study objective was to evaluate the effectiveness of the filter in preventing major complications in patients who have venous thromboembolic disease and were clinically judged to be at high risk of pulmonary embolism. The secondary objectives were to assess: 1) the stability of the filter in the IVC during the 12-month follow-up period; and 2) the rate of caval (and/or filter) occlusion.

Indications

The indications for filter placement were: 1) pulmonary embolism (PE) with a contraindication to anticoagulation in 14 patients; 2) recurrent PE in spite of anticoagulation in

14 patients; 3) iliofemoral deep venous thrombosis (DVT) with a contraindication to anticoagulation in nine patients; and 4) patients with free-floating thrombus in five patients. Either PE or DVT was diagnosed in all patients by means of an objective test prior to filter placement: PE with either ventilation/perfusion scanning (n=13, 31%) or pulmonary CT angiography (n=29, 69%) and DVT with either contrasted CT (n=25, 60%) or duplex sonography (n=17, 40%).

Exclusion criteria were pregnancy, uncontrolled infectious diseases, caval diameters larger than 30 mm, life expectancies of less than three months, and current enrollment in other medical investigations.

Filter Design and Deployment

The filter used was a double-basket, symmetric nitinol vena cava filter (TrapEase) laser cut from nickel-titanium (nitinol) tubing. The filter has a non-expanded maximum length of 65 mm. When expanded to its maximum diameter (35 mm in vitro), the length reduced to 50 mm. The cephalic and caudal baskets of the filter consist of struts in a six diamond or trapezoidal configuration. The baskets are then connected by six straight struts, which contain proximal and distal hooks for fixation within the IVC. The filter is implanted through a 6-F straight introducer sheath (55 cm long) with a radiopaque marker at the distal tip. A pusher advances the filter through the sheath to the implantation site (Figs. 1A, B). This introducer system increases the speed and efficiency of the procedure.

Before implantation, the diameter of the IVC was assessed by cavography by means of contour marking of the angiographic catheter to determine eligibility for study

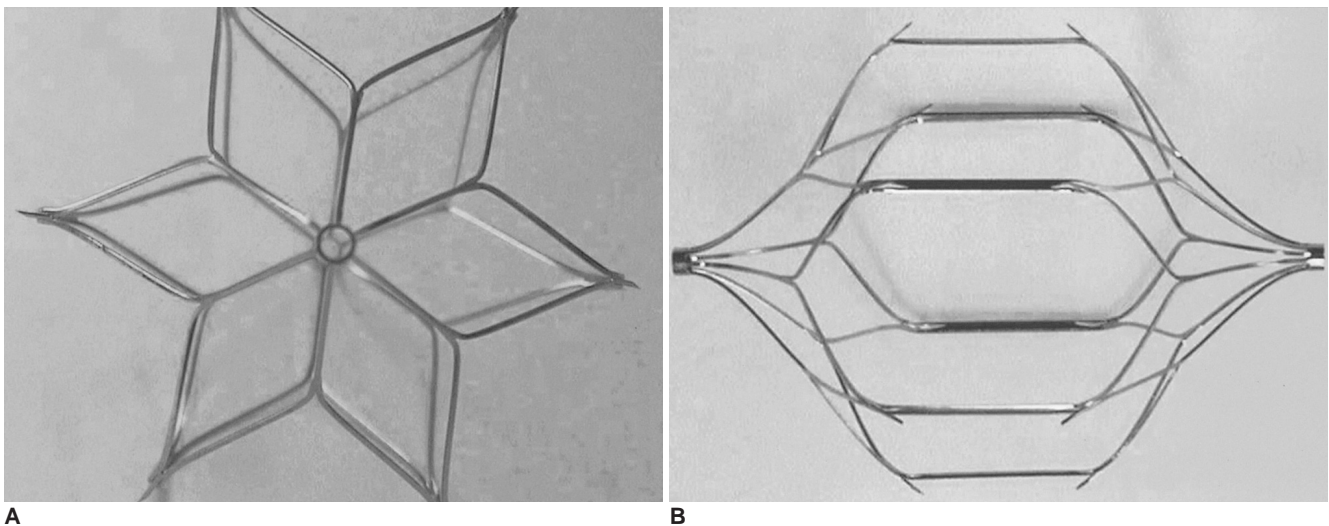


Fig. 1. A, B. Frontal (A) and lateral (B) views of the TrapEase inferior vena cava filter.

inclusion (16–30 mm). By using a standard percutaneous procedure, the long 6-F (filter delivery) sheath was introduced under fluoroscopy via either the jugular vein or the femoral vein over a standard 0.035-inch guide wire to the intended implantation site in the IVC. After removing the guide wire, the filter was introduced into the sheath and advanced to the tip of the sheath by means of the pusher. Once it was determined that the filter was in the correct position in the IVC, the sheath was retracted. By this means, the filter was deployed immediately below the renal veins. An anteroposterior and lateral projection plain radiography was performed to determine the final position of the filter in the IVC. Nineteen patients were maintained on anticoagulation following filter placement.

Follow-up

Patients underwent duplex Doppler US of their lower limbs and an abdominal CT scan to identify any underlying diseases. Baseline ventilation-perfusion scanning and chest radiographies were performed before filter implantation.

Subsequent lung scintigraphy and chest radiography were indicated only when symptoms indicating clinically symptomatic PE arose (dyspnea, with thoracic pain and positive blood gas measurements, hypotension, cardiac anomalies, failing consciousness, or lack of consciousness).

A 24-hour follow-up examination before hospital discharge included abdominal radiography, Duplex Doppler US (ATL HDI-3000, Advanced Technology Laboratories, Bothell, WA) and a clinical examination. Follow-up at six (n=37) and 12 months (n=34) included chest radiography, abdominal radiography, and contrast enhanced abdominal CT (Lightspeed Ultra 16, GE Medical System, Milwaukee, WI) of the filter to evaluate filter effectiveness, stability and caval obstruction. Filter migration (either caudal or cranial of more than one vertebra) as seen in abdominal radiography, or filter tilt of more than 150 from the axis of the IVC, was considered positive.

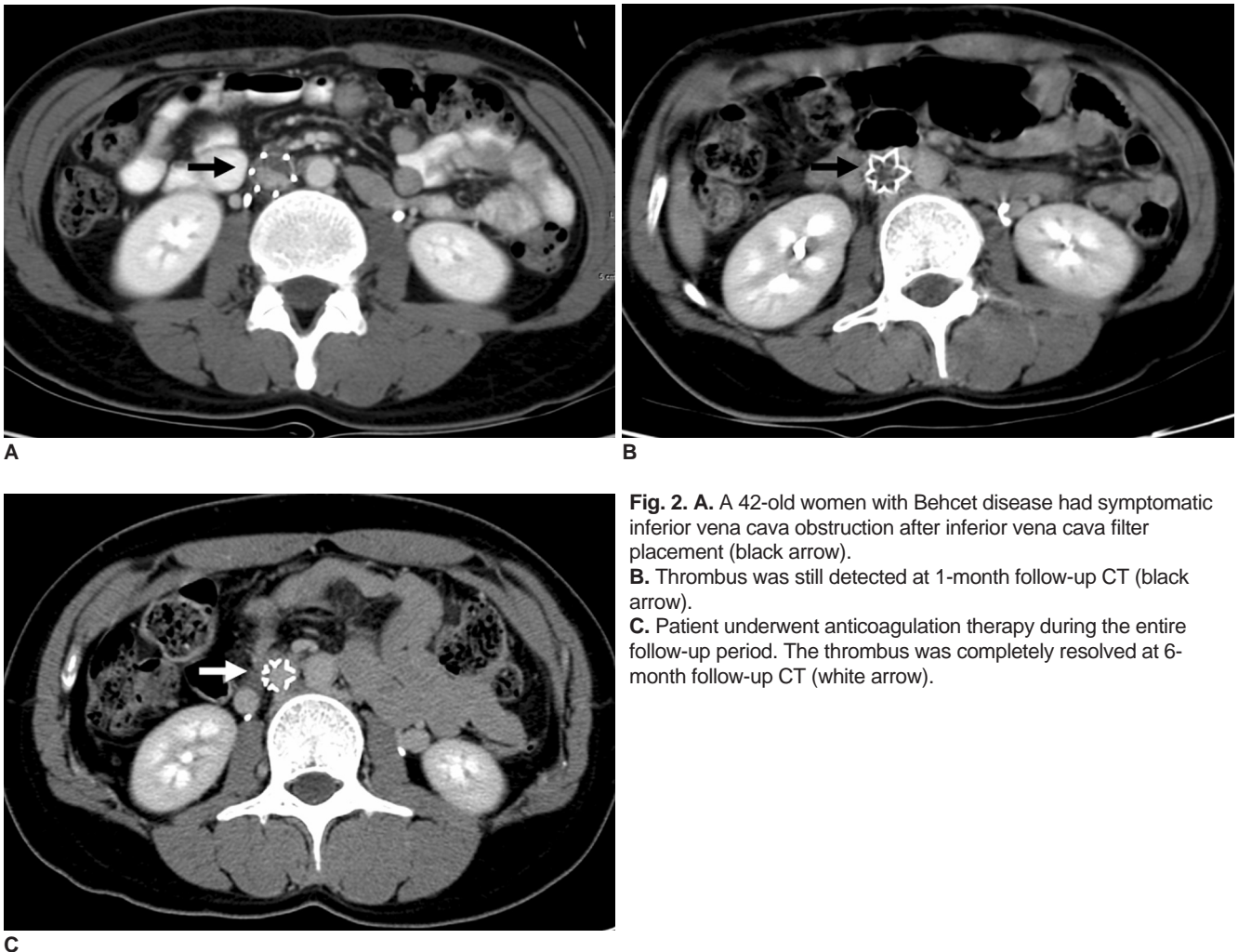


Fig. 2. A. A 42-old women with Behcet disease had symptomatic inferior vena cava obstruction after inferior vena cava filter placement (black arrow). B. Thrombus was still detected at 1-month follow-up CT (black arrow). C. Patient underwent anticoagulation therapy during the entire follow-up period. The thrombus was completely resolved at 6-month follow-up CT (white arrow).

RESULTS

Before commencing filter implantation, the mean diameter of the IVC was assessed to be 20.8 mm (range: 16–30 mm). The filter was placed in 34 patients via the right jugular vein and in eight patients via the right femoral vein. The level of implantation in the IVC, using the thoracic and lumbar vertebrae as a reference, was T11-12 in five patients, L1-2 in one patient, L2-3 in 20 patients, L3-4 in 15 patients and L4-5 in one patient. Thirty-seven filters (88%) were placed in the infrarenal location. Five filters (12%) were placed in a suprarenal location because of an extension of the thrombus into the infrarenal IVC (n=4) and double IVC (n=1).

After the 24-hour follow-up exam, there were no reports of filter-related symptomatic PE (0%). There were no reports of hematoma or insertion site complications when the insertion site was controlled by means of duplex and clinical examinations. Abdominal radiography performed during this period to ascertain filter stability (migration) in the vena cava showed no cases of filter migration or other filter-related complications.

There was one case of symptomatic IVC obstruction by filter thrombosis during hospitalization. This patient had underlying Behcet disease and DVT with free-floating IVC thrombosis. Lower leg swelling was aggravated after filter placement. A one-week follow-up by contrast enhanced abdominal CT scan showed total an IVC obstruction under the filter level (Fig. 2A). This IVC obstruction was success-

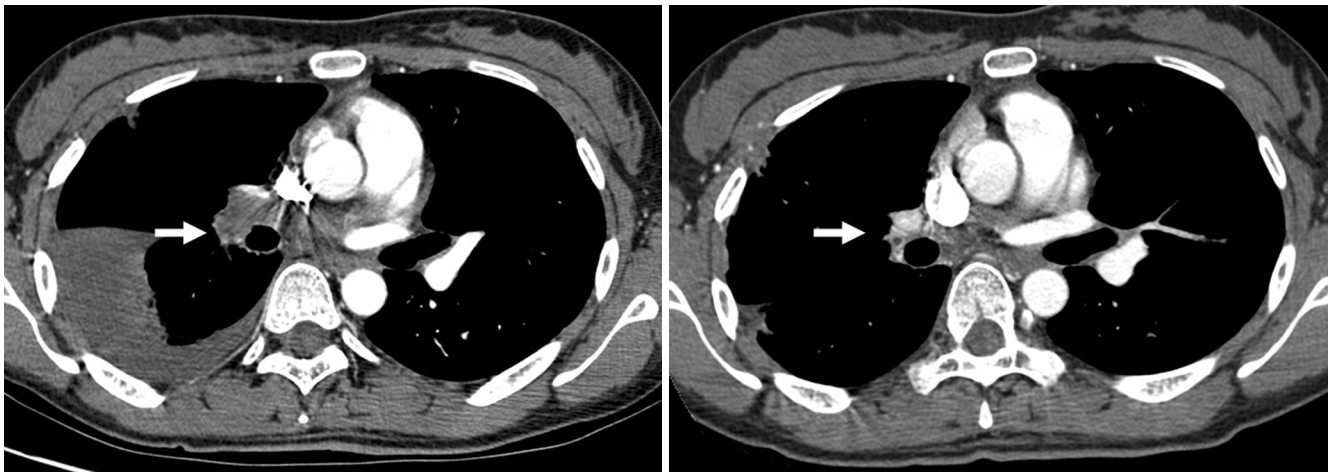


Fig. 3A, B. A 64-old women had symptomatic pulmonary thromboembolism (white arrow).
B. Patient underwent anticoagulation therapy during the entire follow-up period, the pulmonary embolism completely resolved at 1-year follow-up (white arrow).

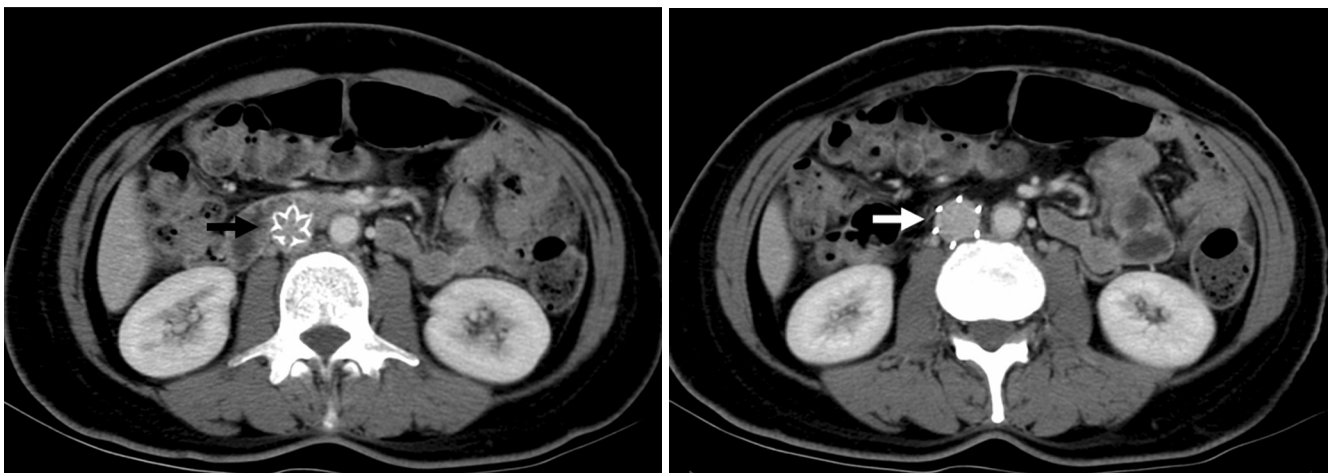


Fig. 4A, B. Abdominal CT demonstrates normal central placement of inferior vena cava filter without wall penetration or tilt (black and white arrow).

fully treated with intravenous urokinase and heparin. Thrombus was still detected in the one-month follow-up CT (Fig. 2B). This patient underwent anticoagulation therapy during the entire follow-up period. The thrombus was found to be completely resolved in the 6- and 12-month follow-up intervals using contrast abdominal CTs (Fig. 2C).

During the follow-up period (mean:15.4 months, range: 2 to 28 months), no cases of recurrent symptomatic PE (Figs. 3A, B), IVC thrombosis, filter migration, filter breakage or vessel wall perforation were observed (Figs. 4A, B) at simple radiography and contrast abdominal CT. Eight patients (19%) in this study group died after filter placement: three at two months, two at four months, one at eight, nine, 11 months, respectively. All deaths were judged by the clinician not to be caused by recurrent pulmonary embolism but rather by the underlying disease process: cervical carcinoma (n=2), pancreatic adenocarcinoma (n=2), urogenic sepsis (n=1), intracranial hemorrhage (n=1), liver cirrhosis with spontaneous bacterial peritonitis (n=1) and ovarian cancer (n=1).

DISCUSSION

Presently, there are seven devices for percutaneous IVC interruption approved by the US Food and Drug Administration (FDA); the stainless steel Greenfield filter, the titanium Greenfield filter (Boston Scientific/Medi-tech, Watertown, MA), the Bird's Nest filter, Gunter Tulip filter (Cook, Bloomington, IN), the Simon nitinol filter (Nitinol Medical Technologies, Woburn, MA), VenaTech low-profile filter (Braun Venatech, Evanston, IL), and TrapEase filter (Cordis, Europa N.V., L.J. Roden, The Netherlands). Despite the popularity of these IVC filters, there has been no prospective clinical study comparing the effectiveness and complications associated with the different filter designs. None of these devices is ideal. Thus, the search for an ideal device continues (3).

Insertion of IVC filters offers protection from life-threatening PE while subjecting the patient to a small incidence of associated filter complications. The major complications related to the insertion of permanent IVC filters are insertion site thrombosis, filter migration, strut erosion through the IVC wall, recurrent pulmonary embolism, IVC obstruction and lower extremity venous insufficiency (4).

Thrombotic complications after filter placement, another key IVC filter attribute, may in fact be a major discriminating variable among the design. Thrombosis associated with IVC filters occurs in two instances - outright IVC thrombosis and access-site thrombosis. Caval obstruction and/or filter thrombosis reported varies widely (0–28%) (5).

Filter occlusion may result from successful clot trapping. An initial partial occlusion may develop into a total occlusion. Or, occlusion may be due to the presence of the device in the vena cava. In filter occlusion, it is difficult to determine which of the two possibilities could have been responsible for the event. Although thrombosis due to successful clot trapping by the filter is an undesired event, it represents a trade-off situation between possible thrombosis and potentially fatal PE due to inadequate clot trapping. In this study, one case of caval obstruction by filter thrombosis occurred during hospitalization, which was successfully treated with intravenous urokinase and heparin.

Access site thrombosis is a serious complication because it poses an additional risk for patients with PE. The size of the introducer system is important in minimizing the risk for incidence of insertion site thrombosis. In the days after filter implantation, femoral insertion of the titanium Greenfield filter (14 F outer diameter introducer system) was reported to give a high incidence of insertion site thrombosis (ranging between 19–41% (6, 7) and 28% for the Simon nitinol filter with a smaller introducer sheath (7–F) (8)). The introducer sheath for the TrapEase IVC filter uses only a 6-F diameter, which is the smallest system of all vena cava filters currently available. In this study, Duplex US of the insertion site revealed there was no case (0%) of hematoma. There were no cases of thrombophlebitis at the site of implantation between 24 hours and discharge. In addition, there were no other complications that are known to be associated with filter insertion, such as air embolism, PE due to freed or dislodged thrombus as a result of catheter manipulation and wound infection. We believe that none of insertion site complications were due to filter placement through the right jugular vein and smaller introduce sheath (9, 10).

Filter migration has had a variation of definitions in all the manuscripts the authors mention making head-to-head comparisons difficult. Filter migration is a complication because of the potentially fatal consequences. The risks include migration to a location or position where the device no longer protects against PE or embolization of the filter into the heart or pulmonary artery. Distal filter migration occurred most often, and the incidence was 0–53% in the most frequently deployed filters (8, 11–15). Rose et al. (11) found movement in 28 of 53 patients (53%) with routine follow roentgenograms. The newer filter designs have not prevent migration. To detect distal or proximal filter migration, abdominal radiography must be performed. Some of the reported filter movement may have been secondary to measurement errors, since changes less than 0.5 cm could come from patient positioning,

breathing, and parallax of the roentgenogram beam. In this study, controlled abdominal radiography was performed at day one or earlier and at one, six, and 12 months after implantation. There were no cases of migration.

Malpositioning can include tilting of the filter, asymmetry or entwining of struts of the device, and improper anatomic placement. Tilting and the asymmetric positioning of the device can lead to decreased filter filtration or effectiveness because of the larger-than-intended spaces between the filter struts. This can increase the risk for larger-than-intended size thrombi to pass through the filter and, inadvertently, into the lungs. Tilting has been observed in the Venatech filter in as many as 16% of the placements (12). Asymmetry or the entwining of struts has been reported with the titanium Greenfield filter at an incidence of up to 71% (16). In this study, there was no case of tilting or asymmetry. The design of the TrapEase filter would appear to be such that the chance of tilting and asymmetric placement are minimized because of the long side struts being directly connected to the proximal and distal baskets. This may reduce the possibility of individual side struts attaching asymmetrically to the vessel walls during filter release. Improper placement of the filter has been reported to occur in the heart (17), renal vein (3), spermatic vein, iliac vein (18), lumbar vein (19), and suprarenal caval vein (20). All filters were implanted in the IVC in this study.

Experiments using both the titanium Greenfield and the stainless steel Greenfield filters deployed in sheep showed that all filters demonstrated IVC penetration at one or more sites over a 12-month period. Histological analysis revealed intimal remodelling, chronic inflammation, and adventitial thinning around the hook sites (21). In the review of collected case series, IVC wall penetration was found to occur in 4% of titanium Greenfield filters, 37% of Simon Nitinol filters, and 38% of Bird's Nest filter (5). In the MGH series, nine out of 96 patients who underwent autopsies had evidence of IVC penetration (15). None of these patients died as a result of this finding. Although one of the criticisms of TrapEase is the issue of radial force and possible caval rupture, there was no case of caval wall penetration and retroperitoneal hemorrhage on follow-up contrasted abdominal CT in this study.

Recurrent PE following IVC filtration has been reported to range from 2–6% (1), with fatal PE occurring in 0.8–3.7% of the cases (22, 23). Embolus can occur through or from the filter or via collateral pathways, particularly where there has been well-developed caval thrombosis and collateral veins. This study had no cases of recurrent symptomatic PE. Symptoms of PE in early follow-ups were reported to be related to the preimplantation status of the

patient and did not signify a worsening of the pulmonary status because of possible recurrent PE. No incidence of recurrent symptomatic PE in our series suggests the TrapEase filter is effective at clot trapping.

The TrapEase IVC filter has several advantages over currently available filters. First, the TrapEase has the smallest introducer system of all permanent IVC filters (6F), thereby reducing the risk of insertion site complications (10). Its double-basket, symmetric design with long connecting side struts appears to provide a low risk of tilting, a phenomenon often observed with umbrella filters. Thus, the risk of compromised clot trapping is reduced. In addition, the symmetry of the filter not only allows for the introduction through both jugular and femoral routes with a single kit but also removes the risk of a filter being incorrectly implanted, as could occur with asymmetric devices. Another advantage of the small-sized sheath is the option of introducing the filter by a brachial approach (24).

A long-term follow-up of patients treated with IVC filters is difficult because of their age and poor health condition. Further, most recurrent PE are asymptomatic. As noted by other authors, 20–45% of patients (mean: 30%) died within the first year following filter implantation (25, 26). In this study, eight patients (19%) died in the first 12 months of using an IVC filter placement due to underlying diseases. The mortality rate was related to the underlying disease, mainly due to cancer (50%), which appeared to be the only predicting prognostic factor in this study.

Even though the follow-up period is short, the 6-F TrapEase permanent IVC filter is a safe, effective device with a low overall complication rate that can be used for thromboembolic disease with a high risk of PE.

References

1. Ferris EJ, McCowan TC, Carver DK, McFarland DR. Percutaneous inferior vena caval filters: follow-up of seven designs in 320 patients. *Radiology* 1993;188:851-856
2. Rousseau H, Perreault P, Otal P, Stockx L, Golzarian J, Oliva V, et al. The 6-F nitinol TrapEase inferior vena cava filter: results of a prospective multicenter trial. *J Vasc Interv Radiol* 2001;12:299-304
3. Grassi CJ. Inferior vena caval filters: analysis of five currently available devices. *AJR Am J Roentgenol* 1991;156:813-821
4. Tardy B, Mismetti P, Page Y, Decouses H, Da Costa A, Zeni F, et al. Symptomatic inferior vena cava filter thrombosis: clinical study of 30 consecutive cases. *Eur Respir J* 1996;9:2012-2016
5. Streiff MB. Vena caval filters: a comprehensive review. *Blood* 2000;95:3669-3677
6. Mewissen MW, Erickson SJ, Foley WD, Lipchik EO, Olson DL, McCann KM, et al. Thrombosis at venous insertion sites after inferior vena caval filter placement. *Radiology* 1989;173:155-157
7. Kantor A, Glanz S, Gordon DH, Sclafani SJ. Percutaneous insertion of the Kimray-Greenfield filter: incidence of femoral

- vein thrombosis. *AJR Am J Roentgenol* 1987;149:1065-1066
8. Simon M, Athanasoulis CA, Kim D, Steinberg FL, Porter DH, Byse BH, et al. Simon nitinol inferior vena cava filter: initial clinical experience. Work in progress. *Radiology* 1989;172:99-103
 9. Schleich JM, Morla O, Laurent M, Langella B, Chaperon J, Almange C. Long-term follow-up of percutaneous vena cava filters: a prospective study in 100 consecutive patients. *Eur J Vasc Endovasc Surg* 2001;21:450-457
 10. Kinney TB. Update on inferior vena cava filters. *J Vasc Interv Radiol* 2003;14:425-440
 11. Rose BS, Simon DC, Hess ML, Van Aman ME. Percutaneous transfemoral placement of the Kimray-Greenfield vena cava filter. *Radiology* 1987;165:373-376
 12. Ricco JB, Crochet D, Sebilotte P, Serradimigni A, Lefebvre JM, Bouissou E, et al. Percutaneous transvenous caval interruption with the "LGM" filter: early results of a multicenter trial. *Ann Vasc Surg* 1988;2:242-247
 13. Greenfield LJ, Cho KJ, Tauscher JR. Limitations of percutaneous insertion of Greenfield filters. *J Cardiovasc Surg (Torino)* 1990;31:344-350
 14. Schneider PA, Geissbuhler P, Piguat JC, Bounameaux H. Follow-up after partial interruption of the vena cava with the Gunther filter. *Cardiovasc Intervent Radiol* 1990;13:378-380
 15. Athanasoulis CA, Kaufman JA, Halpern EF, Waltman AC, Geller SC, Fan CM. Inferior vena caval filters: review of a 26-year single-center clinical experience. *Radiology* 2000;216:54-66
 16. Sweeney TJ, Van Aman ME. Deployment problems with the titanium Greenfield filter. *J Vasc Interv Radiol* 1993;4:691-694
 17. Roehm JO Jr, Johnsrude IS, Barth MH, Gianturco C. The bird's nest inferior vena cava filter: progress report. *Radiology* 1988;168:745-749
 18. Cimochoowski GE, Evans RH, Zarins CK, Lu CT, DeMeester TR. Greenfield filter versus Mobin-Uddin umbrella: the continuing quest for the ideal method of vena caval interruption. *J Thorac Cardiovasc Surg* 1980;79:358-365
 19. Greenfield LJ, Cho KJ, Proctor M, Bonn J, Bookstein JJ, Castaneda-Zuniga WR, et al. Results of a multicenter study of the modified hook-titanium Greenfield filter. *J Vasc Surg* 1991;14:253-257
 20. Brenner DW, Brenner CJ, Scott J, Wehberg K, Granger JP, Schellhammer PF. Suprarenal Greenfield filter placement to prevent pulmonary embolus in patients with vena caval tumor thrombi. *J Urol* 1992;147:19-23
 21. Proctor MC, Greenfield LJ, Cho KJ, Moursi MM, James EA. Assessment of apparent vena caval penetration by the Greenfield filter. *J Endovasc Surg* 1998;5:251-258
 22. Nicolaides AN, Arcelus J, Belcaro G, Bergqvist D, Borris LC, Buller HR, et al. *Prevention of venous thromboembolism*. European Consensus Statement, 1-5 November 1991, developed at Oakley Court Hotel, Windsor, UK. *Int Angiol* 1992;11:151-159
 23. Paiement GD, Desautels C. Deep vein thrombosis: prophylaxis, diagnosis, and treatment--lessons from orthopedic studies. *Clin Cardiol* 1990;13(4 Suppl 6):VI19-22
 24. Stavropoulos SW, Clark T, Jacobs D, Soulen M, Shlansky-Goldberg R, Solomon J, et al. Placement of a vena cava filter with an antecubital approach. *Acad Radiol* 2002;9:478-481
 25. Lord RS, Benn I. Early and late results after Bird's Nest filter placement in the inferior vena cava: clinical and duplex ultrasound follow-up. *Aust N Z J Surg* 1994;64:106-114
 26. Poletti PA, Becker CD, Prina L, Ruijs P, Bounameaux H, Didier D, et al. Long-term results of the Simon nitinol inferior vena cava filter. *Eur Radiol* 1998;8:289-294