

Delayed Postoperative Spinal Epidural Hematoma after Cervical Laminoplasty

Masato Tomii,¹ Junichi Mizuno,¹ Ken Kazama,¹ Tadao Matsushima,¹ and Kazuo Watanabe^{1,2}

A 56-year-old man underwent cervical laminoplasty for cervical spondylosis. On the 7th postoperative day, he suddenly felt severe neck pain, and tetraplegia developed rapidly over 1.5 hrs. Computed tomography demonstrated a huge hematoma compressing the cervical spinal cord. Clot was evacuated 3 hrs after the onset of symptoms. The patient's postoperative course was uneventful. His blood pressure could not be properly controlled in the perioperative period. Surgeons should keep in mind that delayed postoperative spinal epidural hematoma (DPSEH) can occur more than a week after surgery, and meticulous blood pressure control is important for more than a week after a spinal operation.

Keywords: delayed postoperative spinal epidural hematoma, risk factor, hypertension

Introduction

Symptomatic postoperative spinal epidural hematoma (PSEH) is a well-known but rare complication of spinal surgery, occurring in 0.1% to 0.5% of cases, and it is usually diagnosed within a few days, especially within 24 hrs of surgery because the wound healing process is not yet then complete.^{1,2)} Meanwhile, less frequent are reports of symptomatic delayed postoperative spinal epidural hematoma (DPSEH), with a reported frequency of 0.05–0.17% on the 4th to 7th postoperative day,^{3,4)} with the 13th day after surgery being the latest day for symptom onset.⁵⁾ Once neurological deterioration due to PSEH develops, emergency evacuation is required.^{6–9)} Some risk factors for PSEH have been reported.^{1,9,10)}

A case of postoperative DPSEH developing 7 days after cervical laminoplasty that required urgent evacuation of hematoma is reported to identify risk factors that predispose a patient to DPSEH (PSEH) and to call attention to the clinical features of this uncommon entity.

¹Department of Neurosurgery, Southern TOHOKU General Hospital, Iwanuma, Miyagi, Japan

²Department of Neurosurgery, Southern TOHOKU Research Institute for Neuroscience, Southern TOHOKU General Hospital, Koriyama, Fukushima, Japan

Received: April 24, 2017; Accepted: July 6, 2017
Online November 22, 2017

Copyright© 2018 by The Japan Neurosurgical Society
This work is licensed under a Creative Commons Attribution-NonCommercial-NoDerivatives International License.

Case Report

A 56-year-old man presented with numbness affecting his left 2nd and 3rd fingers. His body mass index was 25.66 kg/m², and he had been smoking half a pack a day of cigarettes for 36 years. Physical examination demonstrated no myelopathy. Mild weakness of his left hand (grasping power of the left hand, 25.0 kg; grasping power of the right, 38.6 kg) was noted. Cervical magnetic resonance (MR) imaging showed C3–C7 canal stenosis (Fig. 1). Preoperative coagulation studies were normal. He had been found to have hypertension for several years on annual medical check-ups, but he paid no attention and had received no treatment. His preoperative systolic/diastolic blood pressure was 166/110 mm Hg.

Operation

The patient underwent a unilateral open door-type C4 to C6 laminoplasty. Horizontal amputation of the spinous processes of C4 to C6 was performed. After bilateral laminar exposure was carried out, the lower part of the C3 and the upper part of the C7 laminae were partially removed. Following the left side laminotomy, the outer cortical bone of the right side of each lamina was also drilled out to facilitate elevation. After elevation of the laminae, 14-mm Laminoplasty Baskets (Ammtec, Tokyo, Japan) were fixed with 4-mm or 5-mm-long screws at each lamina. The surgery was uneventful; the operation time was 130 min, and estimated blood loss was 20 ml.

Postoperative Course

Approximately, 115 ml of fluid was drained postoperatively, and the drain was removed 41 hrs after the operation. The patient complained of slight neck pain, but computed tomography (CT) of the cervical spine 18 hrs after the operation showed no abnormality, including no hematoma (Fig. 2). His blood pressure was 151-173/92-118 mmHg, and antihypertensive drugs were administered several times when his systolic blood pressure was over 160 mmHg. As a result, his blood pressure was briefly below 140/90 mmHg after antihypertensive drug administration, but it was generally over 150/90 mmHg. On postoperative day 2, he began a program of progressive physical therapy and out-of-bed activity with soft corset on his neck. The patient suddenly felt severe stabbing neck and shoulder pain on the 7th postoperative day without any triggers such as straining-associated events when he was resting on the bed. And he had no episode of violent neck twisting episode. His blood pressure was 191/115 mmHg at that time. His blood pressure 2 hrs before this event was 170/105 mmHg. Tetraplegia developed rapidly after autokinetic

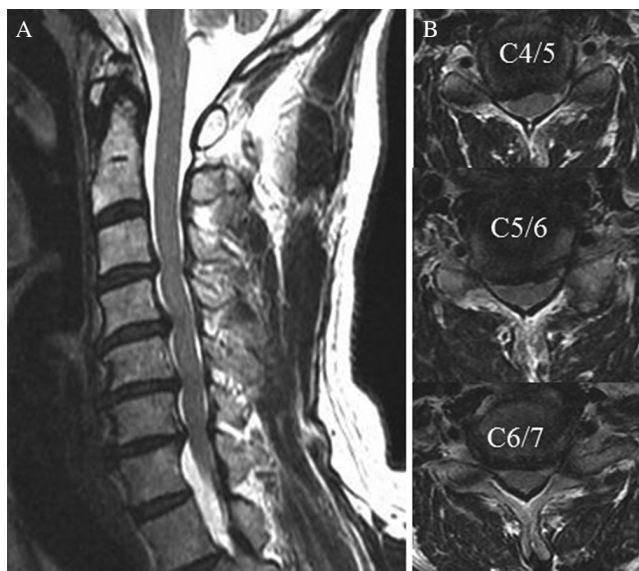


Fig. 1 Preoperative MR images of the cervical spine show spinal canal stenosis from C3/4 to C6/7. (A) A sagittal T2-weighted image. (B) Axial T2 images at the C4/5, C5/6 and C6/7 levels.

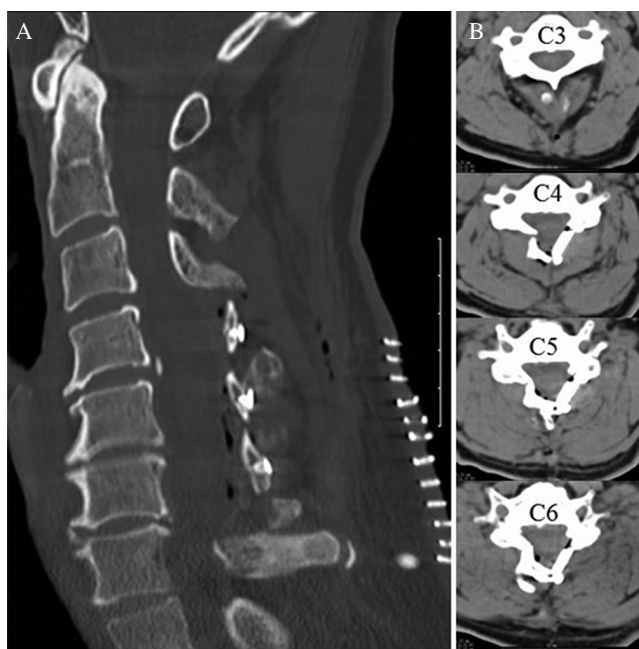


Fig. 2 Postoperative CT scans obtained 18 h after cervical laminoplasty. (A) A sagittal image (bone window). (B) Axial images at the C3, C4, C5, and C6 levels (soft-tissue window). The cervical laminoplasty was done, and there is no sign of a hematoma.

movement of both legs, more on the right side, and no voluntary motion of the four extremities was possible at 1.5 hrs (Frankel Grade B). Emergency cervical spine CT demonstrated a huge hematoma compressing the spinal cord (Fig. 3). We could not take MR imaging, because of his neurologic deterioration was intense and we judged him to be treated promptly. An emergency operation was undertaken 3 hrs after the onset of symptoms along with intravenous administration

of 1000 mg of methylprednisolone and 200 ml of osmotic diuretic (glycerin). A huge hematoma between the bilateral posterior muscles was evacuated, 3 implants from the C4 to C6 laminae were removed, and the epidural hematoma was evacuated. The hematoma occupied the whole epidural space of the operative field, affecting the right upper cervical levels more. However, significant arterial bleeding was identified neither from the posterior muscles nor the epidural space. From the distribution of the epidural hematoma, we postulated intraspinal epidural venous plexus at the upper cervical epidural space is the site of bleeding, but we could not confirm the source of bleeding. After complete evacuation of the hematoma, good pulsation of the dural tube was confirmed. A superficial drain was placed at the time of closure. The drain was discontinued on postoperative day 3. The patient's course after the revision surgery was uneventful, and the motor weakness of both legs had almost improved completely within 2 days. However, his left triceps muscle and wrist flexion strength were graded at 3/5 each, and his axial neck pain remained; these required 2 more months to recover.

Discussion

The present case demonstrated that cervical PSEH can occur 7 days after cervical laminoplasty, and hypertension may be involved.

It is well known that spontaneous spinal epidural hematomas (SSEHs) rarely cause neurological symptoms such as tetra- and paraplegia.^{6,8} In the present case, the possibility that the epidural hematoma was already present within a few days after surgery and became symptomatic after a week could not be ruled out. However, the CT scans taken the day after surgery did not demonstrate a significant hematoma, and the onset of sharp peri-incisional pain and bilateral neurological deficits occurred within a short time on the 7th day after surgery. In addition, the hematoma observed at surgery consisted mostly of hard clot, with no fluid component. Thus, it is natural to presume that the epidural hematoma started to develop within a short time on the 7th day after surgery.

Several risk factors for PSEH within 3 days after surgery have been reported, but one must ask whether there any differences in the risk factors between early and delayed hematoma cases. Most reports of risk factors for PSEH were about hematomas that developed within a couple of days after surgery, and there have been no reports of the specific risk factors for DPSEH after surgery because DPSEH is so very rare. The risk factors for PSEH include preoperative, intraoperative, and postoperative factors. The preoperative factors include: age greater than 60 years;¹⁰ the use of preoperative nonsteroidal anti-inflammatory agents;¹⁰ Rh-positive blood type;¹⁰ a history of hepatitis C and/or low platelet counts;⁴ hemoglobin level less than 10 g/dl;¹⁰ and preoperative coagulopathy.^{1,6,9,11} Intraoperative factors include: involvement of more than five spinal segments that require surgical treatment;^{1,2,10} previous spinal surgery at the same site at which the hematoma developed⁴ and blood loss greater than 1 liter.¹⁰ The postoperative factors include: international normalized ratio greater than 2.0 within the first 48 hrs;¹⁰ the use of intravenous heparin therapy soon after surgery;¹²

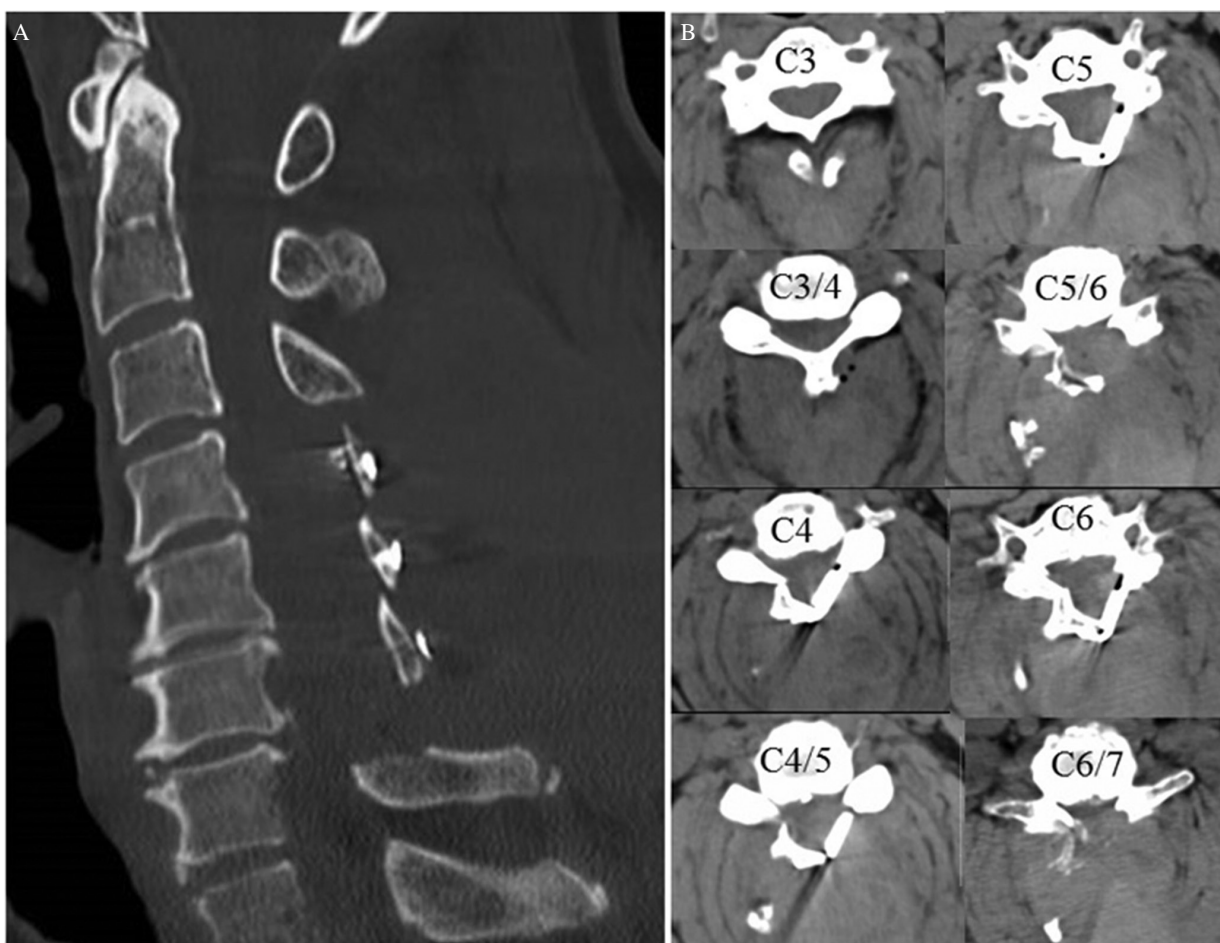


Fig. 3 Postoperative CT scans obtained 7 days after cervical laminoplasty demonstrate a huge epidural and intramuscular hematoma compressing the spinal cord. (A) A sagittal image (bone window). (B) Axial images from C3 to C6/7 (soft-tissue window).

and straining-associated events (straining, sneezing, and lifting).^{6,13} Meanwhile, there are a couple of reports that hypertension (HT) is one of the risk factors for PSEH. Liao et al.⁸ defined HT based on a systolic/diastolic blood pressure of at least 140/90 mmHg or the need for antihypertensive drugs. In their study, the incidence of HT in SSEH patients was 34.3% in the emergency department and 20% in the postoperative ward. They presumed that HT may occur coincidentally with SSEH rather than being a predisposing factor for SSEH. Meanwhile, Awad, et al.¹⁰ analyzed the records of 14,932 patients undergoing spinal surgery, and 32 (0.2%) required re-operation within one week of the initial procedure due to PSEH. They reported that pre-operative HT was not significantly different between the hematoma group and the control group, but the blood pressure tended to be higher in the hematoma group than in the control group. Yin and Ni² reported over 2,338 cervical spinal surgeries, and 12 (0.5%) cases of acute PSEH were identified. Although they did not define HT, they reported that two-thirds of the patients had a history of hypertensive disease or transitory hypertension after surgery. They also concluded that patients who have a history of hypertensive disease may be at higher risk for developing an acute PSEH, because hypertensive

disease and bleeding from the cervical vertebral body easily increase the epidural venous pressure, which goes beyond the normal cerebrospinal fluid pressure and leads to continuous bleeding. In the present case, the patient had been on preoperative nonsteroidal anti-inflammatory agents, and his Rh blood type was positive. However, other factors, other than HT, that had been reported were all negative. Using preoperative nonsteroidal anti-inflammatory agents and a positive Rh blood type are both common. There was insufficient evidence to support these two factors as risk factors of PSEH.⁴ As far as blood pressure, his blood pressure could not be properly controlled in the perioperative period, so that his blood pressure was generally high during that time. Although the pathogenesis of DPSEH may be multifactorial, it was presumed that the main cause of the hemorrhage in the present case was continuous HT.

From the reports of SSEH, it is difficult to establish the absolute time limit for intervention to achieve recovery of patients with SSEH.^{7,8} Lauton et al. and Liao et al.^{7,8} reported that the time limit was within 12 hrs, and Yi et al.⁹ reported it was within 8 h. Groen et al.⁶ showed that late decompression (operative interval >36 hrs) after a complete sensorimotor deficit correlated highly with unfavorable outcome.

In general, there is a consensus that patient's preoperative neurological status and the rapidity of surgical intervention are correlated with the neurological outcome.^{8,13)} In the present case, the patient's preoperative neurological status was severe, but revision surgery 3 hrs after the symptoms began resolved most of the major symptoms.

Conclusion

DPSEH is very rare but should be kept in mind for prompt diagnosis and therapy. Meticulous perioperative blood pressure control for more than a week after a spinal operation is important.

Conflicts of Interest Disclosure

The authors declare that they have no conflicts of interest.

References

- 1) Kou J, Fischgrund J, Biddinger A, Herkowitz H: Risk factors for spinal epidural hematoma after spinal surgery. *Spine* 27: 1670–1673, 2002
- 2) Yin G, Ni B: Acute postoperative cervical spinal epidural hematoma. *Acta Orthop Traumatol Turc* 48: 437–442, 2014
- 3) Aono H, Ohwada T, Hosono N, et al.: Incidence of postoperative symptomatic epidural hematoma in spinal decompression surgery. *J Neurosurg Spine* 15: 202–205, 2011
- 4) Uribe J, Moza K, Jimenez O, Green B, Levi AD: Delayed postoperative spinal epidural hematomas. *Spine J* 3: 125–129, 2003
- 5) Sokolowski MJ, Dolan M, Aminian A, Haak MH, Schafer MF: Delayed epidural hematoma after spinal surgery: a report of 4 cases. *J Spinal Disord Tech* 19: 603–606, 2006
- 6) Groen RJ, van Alphen HA: Operative treatment of spontaneous spinal epidural hematomas: a study of the factors determining postoperative outcome. *Neurosurgery* 39: 494–508; discussion 508–509, 1996
- 7) Lawton MT, Porter RW, Heiserman JE, Jacobowitz R, Sonntag VK, Dickman CA: Surgical management of spinal epidural hematoma: relationship between surgical timing and neurological outcome. *J Neurosurg* 83: 1–7, 1995
- 8) Liao CC, Lee ST, Hsu WC, Chen LR, Lui TN, Lee SC: Experience in the surgical management of spontaneous spinal epidural hematoma. *J Neurosurg* 100: 38–45, 2004
- 9) Yi S, Yoon DH, Kim KN, Kim SH, Shin HC: Postoperative spinal epidural hematoma: risk factor and clinical outcome. *Yonsei Med J* 47: 326–332, 2006
- 10) Awad JN, Kebaish KM, Donigan J, Cohen DB, Kostuik JP: Analysis of the risk factors for the development of post-operative spinal epidural haematoma. *J Bone Joint Surg Br* 87: 1248–1252, 2005
- 11) Laglia AG, Eisenberg RL, Weinstein PR, Mani RL: Spinal epidural hematoma after lumbar puncture in liver disease. *Ann Intern Med* 88: 515–516, 1978
- 12) Spanier DE, Stambough JL: Delayed postoperative epidural hematoma formation after heparinization in lumbar spinal surgery. *J Spinal Disord* 13: 46–49, 2000
- 13) Neo M, Sakamoto T, Fujibayashi S, Nakamura T: Delayed postoperative spinal epidural hematoma causing tetraplegia. Case report. *J Neurosurg Spine* 5: 251–253, 2006

Corresponding author:

Masato Tomii, MD, Department of Neurosurgery, Southern TOHOKU General Hospital, 1-2-5 Satonomori, Iwanuma, Miyagi 989-2483, Japan.

✉ masatotomii@ybb.ne.jp