

Bilateral gemination of permanent maxillary canine with labial and palatal talon's cusps: A rare entity

D B Nandini¹, B S Deepak², Deepak Ningombam Singh³, P Aparnadevi¹

Departments of ¹Oral Pathology and Microbiology, ²Conservative Dentistry and Endodontics and ³Oral Medicine and Radiology, Dental College, Regional Institute of Medical Sciences, Imphal, Manipur, India

Abstract

Gemination is a morphologic anomaly of the tooth characterized by the formation of a macrodont. Bilateral presentation is rarely reported in permanent canines. Talon's cusp is an accessory cusp projecting lingually from the cingulum to the incisal edge and may be seen facially sometimes. Simultaneous occurrence of facial and lingual talons on the same tooth is rare. Concurrent occurrence of all the three entities has not been reported. These anomalies can cause unpleasant esthetic appearance due to irregular morphology. The presence of deep grooves on these teeth increases the susceptible to caries and periodontal disease requiring an endodontic intervention. Proper clinical and radiographic examination provides an accurate diagnosis and helps the clinician in the proper treatment planning and avoiding further complications. This article presents a unique case of simultaneous occurrence of bilateral gemination in the permanent maxillary canines with labial and palatal talon's cusps, which has not been reported in the literature till date.

Keywords: Anomaly, bilateral, canine, complications, facial talon, gemination, labial talon, lingual/palatal talon, permanent dentition, talon's cusp

Address for correspondence: Dr. D B Nandini, Department of Oral Pathology and Microbiology, Dental College, Regional Institute of Medical Sciences, Imphal, Manipur, India.

E-mail: nannidb29@gmail.com

Submitted: 26-Mar-2020, **Accepted:** 29-Jan-2021, **Published:** 19-Mar-2021

INTRODUCTION

Gemination and fusion are morphologic anomalies of the tooth characterized by the formation of a macrodont. Both these anomalies have been named as "double teeth" or "connoted teeth." Gemination is an anomaly caused when a single tooth bud attempts to divide resulting in a structure with two completely separated teeth (twinning) or incompletely separated crowns with a single root and root canal. Fusion occurs when two separate tooth buds fuse together completely or incompletely during development, resulting in a large tooth. Tooth number is normal in gemination, while one tooth is missing in fusion.

This rule does not apply if there are supernumerary teeth. Fusion can also be the union of a normal tooth bud with a supernumerary tooth germ. In such case, the tooth count is normal and the differentiation from gemination might be difficult, if not impossible. Gemination and fusion are more common in the primary dentition than the permanent dentition. Mandibular anterior region and incisors are more often affected. The unilateral occurrence is more commonly reported than bilateral presentation.^[1] The frequency of gemination or fusion ranges from 0.01% to 0.04% in the primary dentition and 0.05% in the permanent dentition.^[2]

This is an open access journal, and articles are distributed under the terms of the Creative Commons Attribution-NonCommercial-ShareAlike 4.0 License, which allows others to remix, tweak, and build upon the work non-commercially, as long as appropriate credit is given and the new creations are licensed under the identical terms.

For reprints contact: WKHLRPMedknow_reprints@wolterskluwer.com

How to cite this article: Nandini DB, Deepak BS, Singh DN, Aparnadevi P. Bilateral gemination of permanent maxillary canine with labial and palatal talon's cusps: A rare entity. J Oral Maxillofac Pathol 2021;25:S71-5.

Access this article online

Quick Response Code:



Website:

www.jomfp.in

DOI:

10.4103/jomfp.JOMFP_118_20

Talon's cusp is an accessory cusp-like structure projecting from the cingulum area or labial surface of the tooth composed of normal enamel, dentin and varying degree of pulp tissue with or without pulp horn. It may be seen on palatal/lingual and facial/labial surface of incisors or canines and may connect with the incisal edge to produce a 'T' shaped, or if more cervical, a 'Y' shaped crown contour. The occurrence of talon's cusp is said to be 0.73% to 8% of the population.^[3] The prevalence of talon's cusps in the Indian population ranges from 1% to 8%.^[4]

Only one case of bilateral gemination in the permanent maxillary canines has been published so far by Gangadharan *et al.*^[5] which makes this the second case. However, their case did not report talon's cusps. To the best of our knowledge, the present case is the first case reporting bilateral gemination with facial and palatal talon's cusps in permanent maxillary canines. Literature search showed no published case report involving all the three entities.

CASE REPORT

A female patient aged 23 years reported to the hospital with a chief complaint of discolored upper front teeth. On intraoral examination, the maxillary right and left canines appeared to have an abnormal morphology with an increased mesiodistal dimension and presence of facial and palatal talon's cusps [Figures 1-3]. The canine teeth bilaterally were unusually large with a groove showing blackish discoloration on the labial surface. The teeth count was found to be normal (28 teeth), and the third molars were clinically missing in all quadrants. Intraoral periapical radiograph of both canines revealed a single root and single root canal with a bifid crown [Figure 4]. The right canine (FDI 13) showed prominent coronal radio opacity which was separated by a radiolucent line in the crown while the left canine (FDI 23) revealed two distinct coronal radio opacity. Electric pulp testing, percussion and periodontal probing showed no abnormalities. Based on these findings, a diagnosis of bilateral gemination of permanent maxillary canines with labial and palatal talon's cusps was made. The patient was advised all the treatment options. The patient was not willing for reduction of the tooth surface and wanted only the removal of discoloration. Glass ionomer restoration was done to fill up the grooves in both the teeth.

DISCUSSION

Bilateral occurrence of gemination is a rare entity. Bilateral gemination with labial and palatal talon's cusps on permanent maxillary canine is an extremely rare occurrence. The etiology of gemination is uncertain. Evolution,

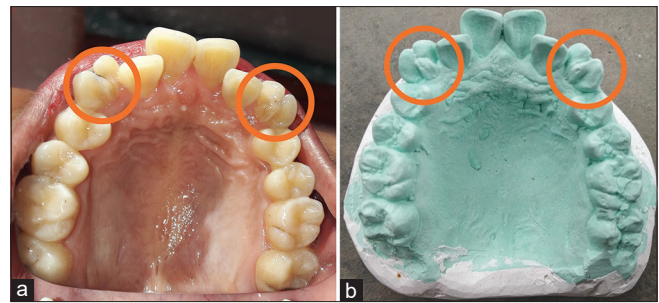


Figure 1: Clinical photograph (a) and cast (b) showing bilateral gemination with facial and palatal talon's cusps on permanent maxillary canines

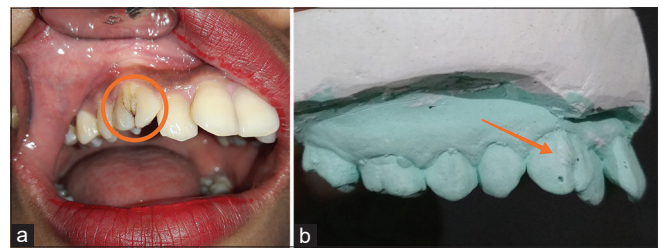


Figure 2: Gemination on the right permanent maxillary canine showing facial and palatal talon's cusps. (a) Clinical picture (b) on the cast

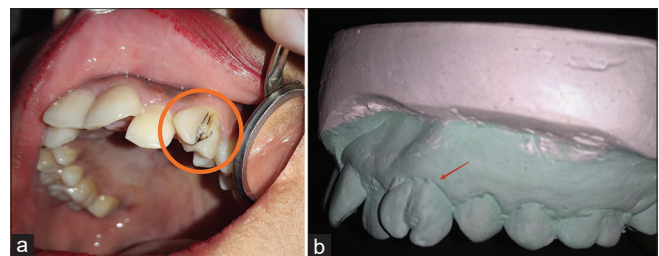


Figure 3: Gemination on the left permanent maxillary canine showing facial and palatal talon's cusps. (a) Clinical picture (b) on the cast





trauma during development, heredity and environmental factors are thought to play a role in gemination. Hereditary tendency with autosomal recessive or dominant mode of inheritance affecting the dental lamina is suggested. Association of gemination with syndromes such as chondroectodermal dysplasia and achondrodysplasia is also observed. Nutritional deficiency, endocrine disturbances, infectious inflammatory processes, excessive ingestion of medicines and ionizing radiation are other suggested etiologies. A complex interplay between genetic and environmental factors seems to play a role causing this anomaly.^[1,6] Aguiló *et al.*^[7] classified gemination as shown in Table 1. Gemination is generally asymptomatic. However, the affected teeth may cause clinical problems in the form of poor esthetics, malocclusion, impaction of adjacent teeth, and caries or periodontal destruction.

Talon's cusp was first recognized by Mitchell in 1892.^[8] Mellor and Ripa later coined the term "talon"

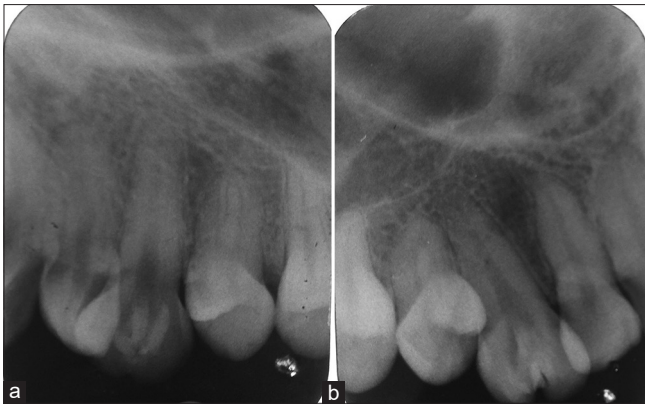

Figure 4: Intraoral periapical radiograph of the right (a) and left (b) permanent maxillary canines

Table 1: Classification of gemination according to Aguiló *et al.*^[7]

Type	Diagram	Description
Type 1		Enlarged crown with notch on the incisal edge, pulp chamber can be bifid, normal radicular dimension, cervical widening of canal
Type 2		Straight/normal incisal edge, large pulp chamber and root canals with increased radicular dimension
Type 3		Two fused crowns, with complete or partial vertically running groove, which extends cervically. Coronal portion may or may not be symmetrical. Pulp chamber coronally can be fused or shared but end as two separate canals
Type 4		Two separate crowns with separate root and canals (Twinning)

due to its resemblance to eagle's talon.^[9] It is also called as dens evaginatus which is more commonly used for the posterior teeth. Multifactorial etiology with genetic and environmental involvement during the morphodifferentiation stage of tooth development is suggested. Talon's cusps may be associated with somatic abnormalities, such as Mohr's syndrome, Rubenstein–

Taybi syndrome, Sturge–Weber syndrome, Ellis-van Creveld syndrome, Berardinelli–Seip syndrome and Alagille syndrome.^[7] However, the present case was not associated with any anomalies.

Talon's cusps occur most commonly on the maxillary teeth than the mandibular teeth. Most commonly affected teeth include the maxillary permanent incisors (90% cases), especially the lateral incisors (67%) followed by the central incisors (24%), and less frequently the mandibular incisors (6%) and maxillary canine (9%).^[10] Involvement of canine is very rare. Unilateral cases are more common. Talon's cusp usually occurs on the lingual surfaces of the teeth, while facial talons are rare. Talon's cusp is more often reported in males than females. The facial talon's cusp has a higher predilection for females. Simultaneous occurrence of facial and lingual talons on the same tooth is extremely rare. Some reported cases in the literature are shown in Table 2.^[3,11-18]

The etiology of talon's cusp is poorly understood. It has been suggested that the condition may have a multifactorial etiology that may include both the environmental and genetic factors. Genetic inheritance in five siblings was reported by Elmubarak.^[19] Hyperactivity of dental lamina early in the odontogenesis has been suggested. Hattab *et al.* suggested that the talon's cusp might be formed as a result of an outward folding of the inner enamel epithelial cells and a transient focal hyperplasia of mesenchymal dental papilla.^[6]

Hattab *et al.*^[6] have classified only lingual talons and Chin-Ying *et al.*^[20] also included labial talons in their classification [Table 3]. In the present case, both geminated teeth had talon's cusps, and the mesiodistal width of the teeth was significantly increased. Facial talon's cusp has been categorized into three stages depending on its form starting from the slightest to most extreme forms by Mayes^[21] [Table 4].

The present case is similar to type 1 category of gemination with respect to incisal aspect and type II labial talon's cusp bilaterally and type II lingual talons on 23 and type III talons on 13, but radiographically both the maxillary canines have only enlarged pulp chamber without any bifid appearance [Figure 4].

The mere presence of talon's cusp does not warrant endodontic or restorative treatment unless other dental problems such as caries, loss of periodontal attachment, occlusal interference, irritation to the soft tissues or for

Table 2: Reported cases with labial and palatal talon's cusps on the same tooth in permanent dentition^[3,11-18]

Authors	Year	Place	Sex	Affected tooth (FDI)
Abbott ^[11]	1998	Australia	Female	21
McKaig and Shaw ^[12]	2001	Birmingham	Female	11
Dunn WJ ^[3]	2004	America	Female	12
Shashikiran <i>et al.</i> ^[13]	2005	India	Female	21
Sumer and Zengin ^[14]	2005	Turkey	Female	11
Cubukcu <i>et al.</i> ^[15]	2006	Turkey	Female	11
Ekambaram <i>et al.</i> ^[16]	2008	China	Female	Gemination with labial and palatal talon's cusps 41,42
Guyen <i>et al.</i> ^[17]	2016	Turkey	-	Fusion with labial and lingual talon Supernumerary tooth (mesiodens)
Goswami <i>et al.</i> ^[18]	2016	India	Male	31, 32
Nandini <i>et al.</i> (present case)	2020	India	Female	Fusion with facial and lingual talon's cusps 13, 23 Bilateral gemination with facial and palatal talon's cusp

Table 3: Clinical classification of Talon's cusp based on its length by Hattab *et al.*^[6] and by Chin-Ying *et al.*^[20]

Type	Description by Hattab <i>et al.</i> ^[6]	Description by Chin-Ying <i>et al.</i> ^[20]
Type 1	Talon: Well-delineated cuspal projections from the palatal surface of primary or permanent anterior teeth and extend at least half the distance from the cemento-enamel junction to the incisal edge	Major talon: Talons with well-defined cusps projecting from an anterior tooth facial/labial or lingual/palatal surface and extend at least half the distance from the cemento-enamel junction to the incisal edge
Type 2	Semi talon: Projection extends less than half the distance from the cemento-enamel junction to the incisal edge	Minor talon: Talons occur on the same surfaces but extend more than one fourth and less than half from the cemento-enamel junction to incisal edge
Type 3	Trace talon: Talon's cusps are just prominent and well-developed cingula	Trace talon: Talons with enlarged talons and prominent cingula which occupy less than the one fourth the distance from the cemento-enamel junction to the incisal edge

Table 4: Classification of Talon's cusp according to Mayes^[21]

Type	Description
Stage 1	The slightest form, consisting of slightly raised triangle on the labial surface of an incisor extending the length of the crown, but not reaching the cemento-enamel junction or the incisal edge
Stage 2	The moderate form, consisting of a raised triangle on the labial surface of an incisor that extends the length of the crown, does not reach the cemento-enamel junction, but does reach the incisal edge and can be observed clearly and palpated easily at this stage; and
Stage 3	The most extreme form, consisting of a freeform cusp, extending from the cemento-enamel junction to the incisal edge on the labial surface of an incisor

esthetic reasons exist. Treatment modalities depend on the size and morphology of the talon's cusp and the extension of pulp tissue. As the patient wanted only restorative procedure for esthetic reasons, discoloration was selectively removed from the labial grooves and glass ionomer restoration was done.

CONCLUSION

The occurrence of bilateral gemination of permanent canines with labial and lingual talons is a very rare condition. A conservative approach was done to prevent caries and to maintain the vitality of the tooth.

Declaration of patient consent

The authors certify that they have obtained all appropriate

patient consent forms. In the form the patient (s) has/have given his/her/their consent for his/her/their images and other clinical information to be reported in the journal. The patients understand that their names and initials will not be published and due efforts will be made to conceal their identity, but anonymity cannot be guaranteed.

Financial support and sponsorship

Nil.

Conflicts of interest

There are no conflicts of interest.

REFERENCES

1. Türkaskan S, Gökçe HS, Dalkız M. Esthetic rehabilitation of bilateral geminated teeth: A case report. *Eur J Dent* 2007;1:188-91.
2. Duncan WK, Helpin ML. Bilateral fusion and gemination: A literature analysis and case report. *Oral Surg Oral Med Oral Pathol* 1987;64:82-7.
3. Dunn WJ. Unusual case of labial and lingual talon cusps. *Mil Med* 2004;169:108-10.
4. Hamasha AA, Safadi RA. Prevalence of talon cusps in Jordanian permanent teeth: A radiographic study. *BMC Oral Health* 2010;10:6.
5. Gangadharan H, Ashna BR, Vengal M. Bilateral Gemination: A case report. *International J Oral Health Med Res* 2016;2:112-5.
6. Hattab FN, Yassin OM, Al-Nimri KS. Talons cusp in the permanent dentition associated with other dental anomalies: Review of literature and report of seven cases. *J Dent Child*. 1996;63:368-76.
7. Aguiló L, Gandia JL, Cibrian R, Catala M. Primary double teeth. A retrospective clinical study of their morphological characteristics and associated anomalies. *Int J Paediatr Dent* 1999;9:175-83.
8. Mitchell WH: Letter to the editor. *Dental Cosmos* 1892;34:1036.

9. Mellor JK, Ripa LW. Talon cusp: A clinically significant anomaly. *Oral Surg Oral Med Oral Pathol* 1970;29:225-8.
10. Glavina D, Skrinjarić T. Labial talon cusp on maxillary central incisors: A rare developmental dental anomaly. *Coll Antropol* 2005;29:227-31.
11. Abbott PV. Labial and palatal "talon cusps" on the same tooth: A case report. *Oral Surg Oral Med Oral Pathol Oral Radiol Endod* 1998;85:726-30.
12. McKaig SJ, Shaw L. Dens evaginatus on the labial surface of a central incisor: A case report. *Dent Update* 2001;28:210-2.
13. Shashikiran ND, Babaji P, Reddy VV. Double facial and a lingual trace talon cusps: A case report. *J Indian Soc Pedod Prev Dent* 2005;23:89-91.
14. Sumer AP, Zengin AZ. An unusual presentation of talon cusp: A case report. *Br Dent J* 2005;199:429-30.
15. Cubukcu CE, Sonmez A, Gultekin V. Labial and palatal talon cusps on geminated tooth associated with dental root shape abnormality: A case report. *J Clin Pediatr Dent* 2006;31:21-4.
16. Ekambaram M, Yiu CK, King NM. An unusual case of double teeth with facial and lingual talon cusps. *Oral Surg Oral Med Oral Pathol Oral Radiol Endod* 2008;105:e63-7.
17. Guven Y, Kasimoglu Y, Tuna EB, Gencay K, Aktoren O. Prevalence and characteristics of talon cusps in Turkish population. *Dent Res J (Isfahan)* 2016;13:145-50.
18. Goswami S, Mitra M, Saha S, Halder S. A case of fused teeth with facial and lingual talon cusps in the mandibular anterior region: A case report. *Arch Med Health Sci.* 2016;4:75-7.
19. Elmubarak NA. Genetic risk of talon cusp: Talon cusp in five siblings. *Case Rep Dent* 2019;2019:3080769.
20. Chin-Ying S, Giriya V, Fei YJ. Bilateral talon cusps in primary teeth: Clinical significance and treatment. *ASDC J Dent Child* 2001;68:239-43.
21. Mayes AT. Labial talon cusp: A case study of pre-European-contact American Indians. *J Am Dent Assoc* 2007;138:515-8.