

Laparoscopic Proximal Gastrectomy With Gastric Tube Reconstruction

Yoshitake Ueda, MD, PhD, Norio Shiraishi, MD, PhD, Manabu Toujigamori, MD, Hidefumi Shiroshita, MD, PhD, Tsuyoshi Etoh, MD, PhD, Masafumi Inomata, MD, PhD

ABSTRACT

Background and Objectives: There is no standardized method of reconstruction in laparoscopic proximal gastrectomy (LPG). We present a novel technique of reconstruction with a long, narrow gastric tube in LPG for early gastric cancer (EGC).

Methods: During the laparoscopic procedure, the upper part of the stomach is fully mobilized with perigastric and suprapancreatic lymphadenectomy, and then the abdominal esophagus is transected. After a minilaparotomy is created, the entire stomach is pulled outside. A long, narrow gastric tube (20 cm long, 3 cm wide) is created with a linear stapler. The proximal part of the gastric tube is formed into a cobra head shape for esophagogastric tube anastomosis, which is then performed with a 45-mm linear stapler under laparoscopic view. The end of the esophagus is fixed on the gastric tube to prevent postoperative esophageal reflux.

Results: Thirteen patients with early proximal gastric cancer underwent the procedure. The mean operative time was 283 min, and median blood loss was 63 ml. There were no conversions to open surgery, and no intraoperative complications.

Conclusion: This new technique of reconstruction after LPG is simple and feasible. The procedure has the potential of becoming a standard reconstruction technique after LPG for proximal EGC.

Key Words: Gastric tube reconstruction, Laparoscopic surgery, Proximal gastrectomy.

INTRODUCTION

Advances in diagnostic and endoscopic techniques, along with mass screening programs, have increased the detection of early gastric cancer (EGC) in the upper one-third of the stomach, especially in Japan and Korea.^{1,2} The standard operation for proximal EGC is total gastrectomy (TG) in Western countries.³ In contrast, proximal gastrectomy (PG) is performed as an optional treatment for proximal EGC in Asian countries because of advantages over TG in preserving the function of the remnant stomach, such as better postoperative nutritional status after PG than after TG.^{4,5} However, PG has not yet spread worldwide because a standardized technique of reconstruction after PG is lacking. Some surgeons have emphasized the usefulness of jejunal interposition or jejunal pouch reconstruction after PG.⁶ However, because these reconstruction methods are complicated and time consuming, they have not been widely accepted. PG followed by direct anastomosis between the esophagus and remnant stomach has also been developed and is considered a simple reconstruction method because only one anastomosis is necessary. However, this procedure can potentially increase postoperative complications, such as reflux esophagitis, gastric stasis, and anastomotic stenosis.^{7,8} Thus, the best reconstruction method after PG remains debatable.

We have reported PG with reconstruction using a narrow gastric tube in open surgery.⁵ Our procedure is a simple, safe technique that may prevent esophageal reflux and anastomotic stenosis. We have modified this reconstruction method to apply it to laparoscopic proximal gastrectomy (LPG). Our LPG technique, followed by reconstruction with a long, narrow cobra-head-shaped gastric tube, was developed for proximal EGC. We introduce a technique for laparoscopic gastric reconstruction after LPG.

METHODS

Patients

At Oita University Hospital, from July 2009 through December 2014, 13 LPGs were performed, followed by reconstruction with a long, narrow cobra-head-shaped gastric tube. Our indication for LPG is proximal EGC, for

Department of Gastroenterological and Pediatric Surgery, Oita University Faculty of Medicine, Oita, Japan (all authors).

Address correspondence to: Yoshitake Ueda, MD, PhD, Department of Gastroenterological and Pediatric Surgery, Oita University Faculty of Medicine, 1-1 Idagaoka, Hasama-machi, Yufu, Oita 879-5593, Japan; Telephone: +81-97-586-5843, Fax: +81-97-549-6039, E-mail: yoshimd@oita-u.ac.jp

DOI: 10.4293/JSLS.2016.00046

© 2016 by JSLS, Journal of the Society of Laparoscopic Surgeons. Published by the Society of Laparoscopic Surgeons, Inc.

which the preoperative diagnosis is clinical T1N0M0 gastric cancer (Japanese Classification of Gastric Cancer by the Japanese Gastric Cancer Association⁹) located in the upper one-third of the stomach without invasion of the esophagus. Diagnosis was made according to preoperative endoscopy, endoscopic ultrasonography, upper gastrointestinal series, and abdominal computed tomography.

Operative Techniques

After induction of general anesthesia, the patient is placed in reverse Trendelenburg position with the legs apart. Pneumoperitoneum with 10 mm Hg CO₂ is established through the umbilical trocar, and 4 other working trocars are placed in the upper abdomen (**Figure 1A**). With laparoscopic techniques, the left side of the greater omentum is opened toward the lower pole of the spleen with laparoscopic coagulating shears. The left gastroepiploic artery and vein are clipped and divided. After the posterior gastric artery is resected, the short gastric artery and vein are divided. Then, the lesser omentum is opened from the left side of the hepatoduodenal ligament toward the esophagogastric junction. The vagus nerve is also divided. The left gastric artery and vein are clipped and divided, along with the no. 7 lymph nodes. Thus, perigastric lymph nodes without nodes 4d, 5, and 6 are dissected by using laparoscopic procedures. The upper two-thirds of the stomach with perigastric lymph nodes and abdominal esophagus are fully mobilized, and the abdominal esophagus is transected with a laparoscopic linear stapler.

After a minilaparotomy of ~5 cm is made in the upper abdomen immediately above the bulb of the duodenum (**Figure 1B**), the wound is protected with a wound-sealing device (Alexis Wound Retractor S; Applied Medical,

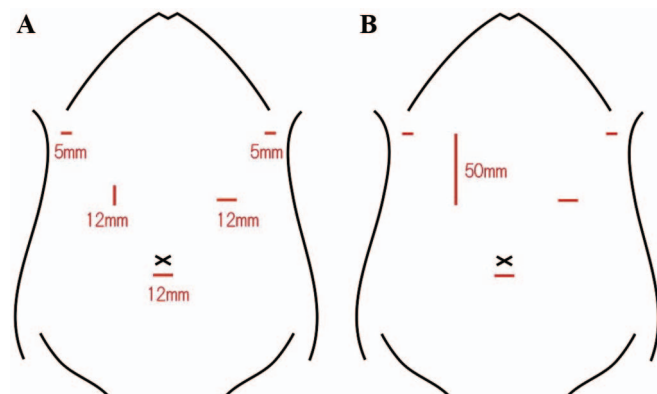


Figure 1. (A) Placement of the trocars for LPG. (B) A minilaparotomy of ~5 cm in length is made in the upper abdomen.

Rancho Santa Margarita, California, USA). The stomach is then pulled outside through the minilaparotomy wound. After PG is performed with techniques similar to those used in open surgery, a long, narrow gastric tube (20 cm long, 3 cm wide) is formed, with the proximal side resembling a cobra's head (**Figure 2, 3**). Thus, the upper two-thirds of the stomach and regional lymph nodes (Nos. 1, 2, 3, 4sa, 4sb, and 7) are resected. A pyloroplasty is not performed.

After pneumoperitoneum is re-established, laparoscopic surgical techniques are used to perform an esophagogastrostomy by direct anastomosis between the posterior wall of the esophagus and anterior wall of the gastric tube with a 45-mm linear stapler (**Figures 4, 5**). To prevent esophageal reflux, both the right and left ends of the esophageal wall are fixed to the gastric wall with laparoscopic interrupted sutures (**Figures 6–8**). A drain is inserted into the peritoneal cavity near the anastomosis, and the wound is closed.

RESULTS

Thirteen patients (12 men and 1 woman) underwent LPG followed by this reconstruction procedure. No cases were converted to open surgery. The mean operative time was 283 minutes, and mean blood loss was 63 ml. No severe complications, such as anastomotic leakage, anastomotic stenosis, pancreatic fistula, or intra-abdominal abscess, occurred. Histologic examination of the resected specimens showed that the postoperative depth of tumor invasion was the mucosal layer in 6 patients, the submucosal layer in 4, the muscle layer in 2, and the subserosal layer in 1. Lymph node metastasis was observed in only 1 patient. Postoperative endoscopy at the 1-year follow-up revealed only 3 patients with reflux esophagitis of grade B (n = 1) or C (n = 2),

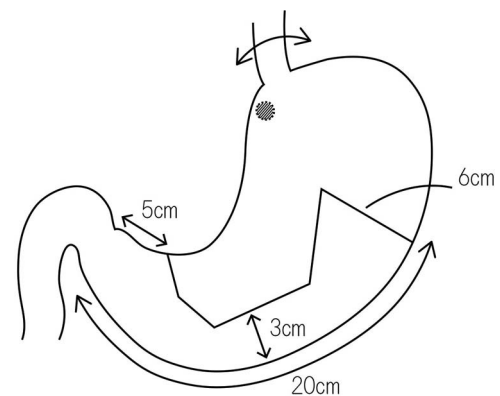


Figure 2. Schematic of LPG and the formation of a cobra-head-shaped gastric tube.

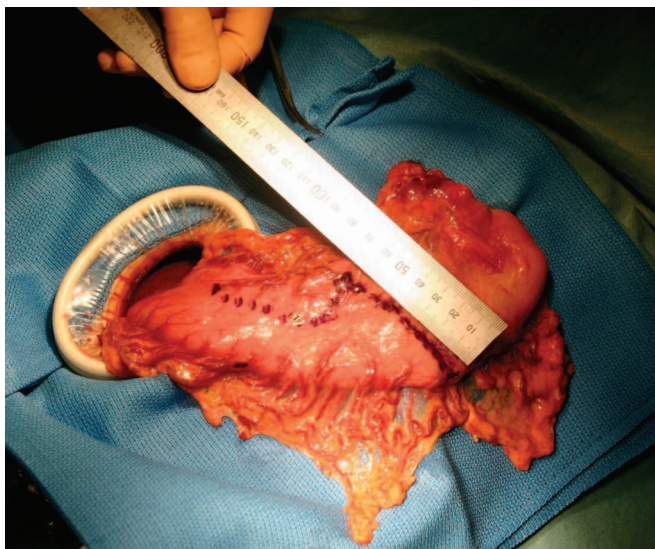


Figure 3. The cobra-head-shaped gastric tube is formed with linear staplers.

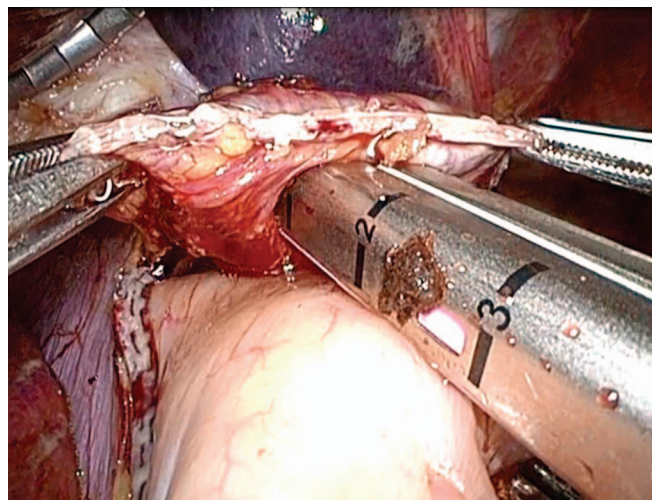


Figure 5. Intraoperative view of the formation of the esophago-gastric tube direct anastomosis between the posterior wall of the esophagus and the anterior wall of the gastric tube with a 45-mm linear stapler.

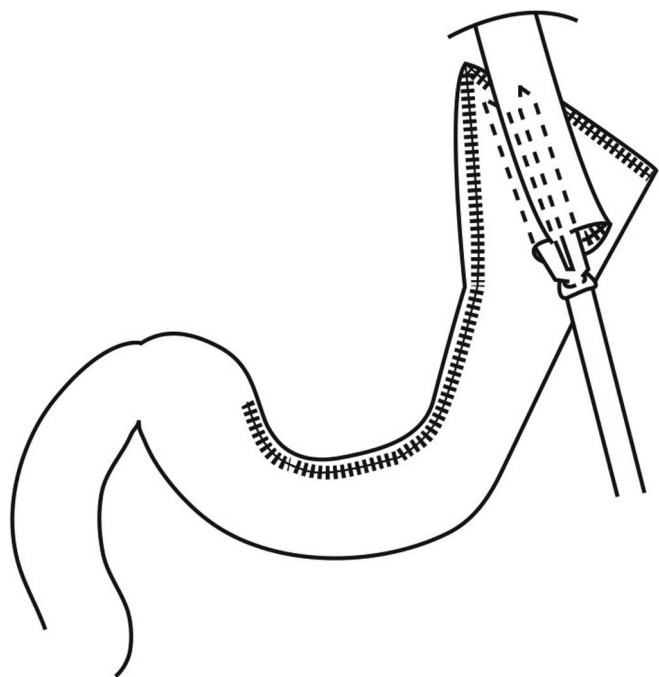


Figure 4. Schematic of formation of an esophago-gastric tube anastomosis with a linear stapler.

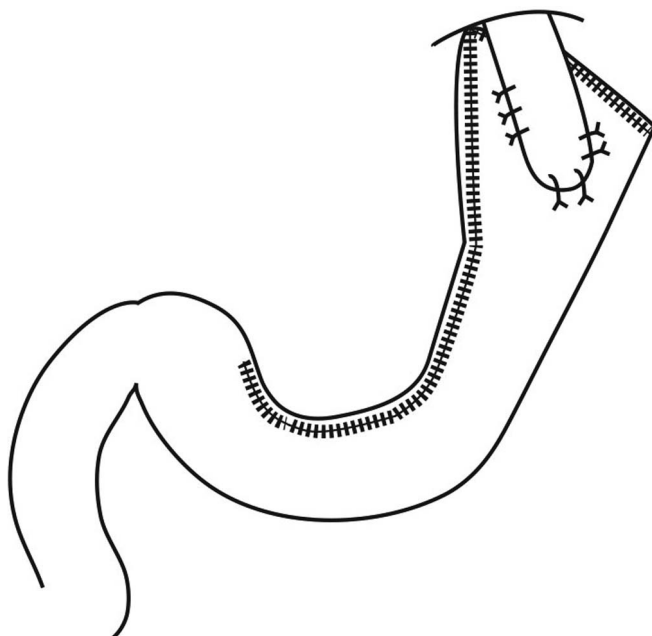


Figure 6. Schematic of the completion of an esophago-gastric tube anastomosis.

according to the Los Angeles classification.¹⁰ The condition in those patients was well controlled by medication only.

DISCUSSION

Our laparoscopic reconstruction method using a long, narrow cobra-head-shaped gastric tube after LPG is

presented. We have reported the benefits of gastric tube reconstruction after open PG, including technical simplicity, fewer reflux symptoms, and preservation of the proximal segment of the jejunum, compared with other post-PG reconstruction methods, especially jejunal interposition and jejunal pouch reconstruction. In addi-

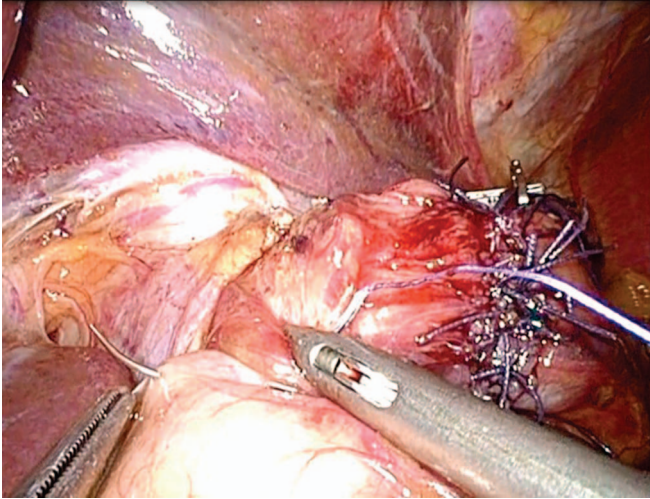


Figure 7. Intraoperative view of the formation of the esophagogastric tube anastomosis shows the fixation of both the right and left ends of the esophageal wall to the gastric wall with laparoscopically placed interrupted sutures.

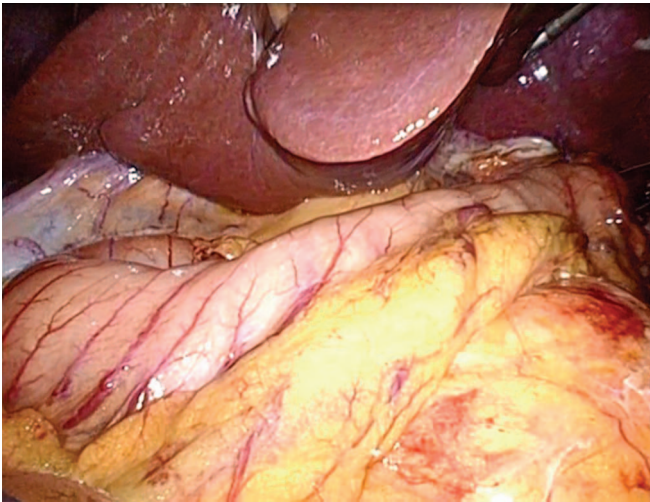


Figure 8. When the esophagogastric tube anastomosis was completed, the gastric tube had a curve similar to the gastric angle.

tion, this procedure results in shorter operating times and faster recovery. Therefore, we modified this reconstruction method to apply it to laparoscopic procedures. The characteristics of our laparoscopic reconstruction procedure include: (1) side-to-side esophagogastric tube anastomosis with a linear stapler; (2) a long (20 cm) and narrow (3 cm wide) cobra-head-shaped gastric tube; and (3) noninjury of the antrum of the remnant stomach without dissection of lymph nodes nos. 5 and 6.

The circular stapler is in popular use for forming anastomoses in jejunal interposition or jejunal pouch reconstruction after TG and PG.^{8,11} Reconstruction with the circular stapler appears physiological; however, the circular stapler is a double-staggered row stapler, and some management is necessary to use it in laparoscopic construction of anastomoses because of its potential to cause leakage and stenosis of the anastomosis. We perform our reconstruction method with side-to-side esophagogastric tube anastomosis with a linear stapler. This device is a tri-stapler that is easy to use in laparoscopic procedures and causes fewer problems with the anastomosis than circular staplers.¹² None of our patients experienced postoperative leakage or stenosis of the anastomosis. We believe that our reconstruction method is technically feasible.

Preventing postoperative esophageal reflux is the most significant challenge in reconstruction by esophagogastric remnant anastomosis after LPG. Esophageal reflux after LPG is caused by stasis in the remnant stomach and loss of the natural antireflux system, including the angle of His and the lower esophageal sphincter. The advantages of our gastric tube procedure for resolving the problems reported are as follows: (1) the long, narrow gastric tube, which has a curved formation similar to the gastric angle, helps to prevent reflux of the gastric juices; (2) the esophagus is laid on the cobra-head-shaped end of the gastric tube at the anastomosis, and the tube becomes a pseudo-fundus; and (3) the noninjured antrum of the remnant stomach without dissection of lymph nodes nos. 5 and 6 helps preserve peristalsis in the antrum. No patients in our series had symptoms of reflux esophagitis, but the condition was observed in 3 patients by endoscopy; those patients improved with medication only. These results are equivalent to those of previous reports on LPG^{7,8} and may be related to the long, narrow gastric tube's functioning as a pyloric ring.

After PG, some patients experience severe gastric stasis caused by resection of the vagus nerve and removal of the pacemaker responsible for gastric smooth muscle peristalsis. No patients in our series had food residue on postoperative endoscopy, suggesting that postoperative food residue in the remnant stomach depends on the functional imbalance between food reservoir capacity and discharge capacity of the remnant stomach. Our reconstruction method offers improved balance between reservoir and discharge capacity.

Previously, we reported that our gastric tube reconstruction after open PG contributes to better quality of life (QOL) of patients by increasing food intake and reducing

postoperative body weight loss in comparison with jejunal interposition reconstruction after PG.^{5,13} We have not yet investigated the postoperative QOL of patients who have undergone LPG with our novel reconstruction method. There are few reports on the QOL of patients after PG in relation to QOL after reconstruction methods.¹⁴ Long-term follow-up of patients who undergo our reconstruction method after LAPG is necessary to evaluate functional outcomes and postoperative QOL of these patients over time.

In conclusion, our new technique of gastric tube reconstruction in LPG is technically feasible. Although longer follow-up and a larger number of patients are needed to evaluate functional outcomes over time, our reconstruction method using a long, narrow gastric tube has the potential to become the standard reconstruction technique for LPG in patients with proximal EGC.

The authors thank Ms. Noriko Ando for kindly drawing detailed schematics of the surgical procedures.

References:

1. Jeong O, Park Y-K. Clinicopathological features and surgical treatment of gastric cancer in South Korea: the results of 2009 nationwide survey on surgically treated gastric cancer patients. *J Gastric Cancer*. 2011;11:69–77.
2. Sano T, Hollowood K. Early gastric cancer: diagnosis and less invasive treatments. *Scand J Surg*. 2006;95:249–255.
3. Wen L, Chen XZ, Wu B, et al. Total vs. proximal gastrectomy for proximal gastric cancer: a systematic review and metaanalysis. *Hepatogastroenterology*. 2012;59:633–640.
4. Braga M, Zuliani W, Foppa L, Di Carlo V, Cristallo M. Food intake and nutritional status after total gastrectomy: results of a nutritional follow-up. *Br J Surg*. 1988;75:477–480.
5. Adachi Y, Katsuta T, Aramaki M, Morimoto A, Shiraishi N, Kitano S. Proximal gastrectomy and gastric tube reconstruction for early cancer of the gastric cardia. *Dig Surg*. 1999;16:468–470.
6. Iwata T, Kurita N, Ikemoto T, Nishioka M, Andoh T, Shimada M. Evaluation of reconstruction after proximal gastrectomy: prospective comparative study of jejunal interposition and jejunal pouch interposition. *Hepatogastroenterology*. 2006;53:301–303.
7. Ahn SH, Lee JH, Park do J, Kim HH. Comparative study of clinical outcomes between laparoscopy-assisted proximal gastrectomy (LAPG) and laparoscopy-assisted total gastrectomy (LATG) for proximal gastric cancer. *Gastric Cancer*. 2013;16:282–289.
8. Aihara R, Mochiki E, Ohno T, et al. Laparoscopy-assisted proximal gastrectomy with gastric tube reconstruction for early gastric cancer. *Surg Endosc*. 2010;24:2343–2348.
9. Japanese Gastric Cancer Association. Japanese classification of gastric cancer, 14th ed. Tokyo: Kanehara Publishing Co., 2010.
10. Lundell LR, Dent J, Bennett JR, et al. Endoscopic assessment of oesophagitis: clinical and functional correlates and further validation of the Los Angeles classification. *Gut*. 1999;45:172–180.
11. Hiki N, Fukunaga T, Yamaguchi T, et al. Laparoscopic esophagogastric circular stapled anastomosis: a modified technique to protect the esophagus. *Gastric Cancer*. 2007;10:181–186.
12. Okabe H, Obama K, Tanaka E, Tsunoda S, Akagami M, Sakai Y. LPG with a hand-sewn esophago-gastric anastomosis using a knifeless endoscopic linear stapler. *Gastric Cancer*. 2013;16:268–274.
13. Adachi Y, Inoue T, Hagino Y, Shiraishi N, Shimoda K, Kitano S. Surgical results of proximal gastrectomy for early-stage gastric cancer: jejunal interposition and gastric tube reconstruction. *Gastric Cancer*. 1999;2:40–45.
14. Braga M, Zuliani W, Foppa L, Di Carlo V, Cristallo M. Food intake and nutritional status after total gastrectomy: results of a nutritional follow-up. *Br J Surg*. 1988;75:477–480.