



Received: 2014.10.28
Accepted: 2014.11.10
Published: 2015.03.01

Authors' Contribution:

- A** Study Design
- B** Data Collection
- C** Statistical Analysis
- D** Data Interpretation
- E** Manuscript Preparation
- F** Literature Search
- G** Funds Collection

Torsion of the Greater Omentum Secondary to Omental Lymphangioma in a Child: A Case Report

Kewal Arunkumar Mistry^{1ABDEF}, Dayashankar Iyer^{2ED}

¹ Department of Radiology, Dr Rajendra Prasad Government Medical College, Kangra, India

² Department of Surgery, Dr Rajendra Prasad Government Medical College, Kangra, India

Author's address: Kewal Arunkumar, Department of Radiology, Dr Rajendra Prasad Government Medical College, Kangra, India, e-mail: drkewalmd@gmail.com

Summary

Background:

Omental cyst and omental torsion both are uncommon but important causes of acute abdomen with a difficult clinical diagnosis due to nonspecific features. Here we report a case of an eight year old child with acute abdominal pain referred for USG and CT scan which revealed two cysts in greater omentum leading to secondary omental torsion.

Case Report:

An eight year old male child presented to casualty with severe pain abdomen since 1 day. There was no history of vomiting or altered bowel habits. The patient was febrile with tachycardia on arrival. On examination rigidity and tenderness all over abdomen were present. Serum amylase was within normal range. USG and CECT abdomen were done subsequently. USG showed two well defined cystic lesions in lower abdomen with presence of some internal echogenic debris and calcified foci in their dependent part. There was also presence of omentum with a whirl of blood vessels seen along anterior abdominal wall leading to these lesions suggesting torsion. On colour Doppler the presence of blood flow within the whirl of vessels was seen. Mild amount of free fluid was also seen in the peritoneal cavity. On CECT abdomen the findings of omental cysts and torsion of greater omentum with free fluid in abdomen were confirmed. The cysts measured 60×55 and 65×55mm on CT. The patient was taken for an emergency laparotomy for indication of acute generalized peritonitis. Two large omental cysts were found in the pelvic cavity along with torted greater omentum along with 150 ml of hemorrhagic fluid in peritoneal cavity. The cysts and twisted necrotic part of the greater omentum were excised at surgery. No postoperative complications were observed. Histopathologic examination was suggestive of lymphangioma of omentum.

Conclusions:

Lymphangioma of the omentum is an not very uncommon however acute presentation with omental torsion and infarction is an unusual entity. Optimal utilization of preoperative imaging with USG, Doppler and contrast enhanced CT scan can provide correct diagnosis.

MeSH Keywords:

Abdomen, Acute • Lymphangioma, Cystic • Omentum • Torsion, Mechanical

PDF file:

<http://www.polradiol.com/abstract/index/idArt/892873>

Background

Omental and mesenteric cystic lesions are rare causes of an abdominal mass. The clinical diagnosis is difficult due to the lack of any characteristic findings [1]. Most of these lesions are congenital and of lymphatic origin. Mode of presentation of these entities can be in the form of long-standing abdominal distension, a palpable mass or rarely as acute abdomen mimicking appendicitis or peritonitis [2]. Possible complications include torsion, hemorrhage,

rupture, infection and very rarely malignant transformation [3].

Case Report

An eight-year-old male child presented to Casualty Department with a one-day history of severe abdominal pain. There was no history of vomiting or altered bowel habits. The patient was febrile with tachycardia on arrival. On examination, rigidity and tenderness of the whole abdomen

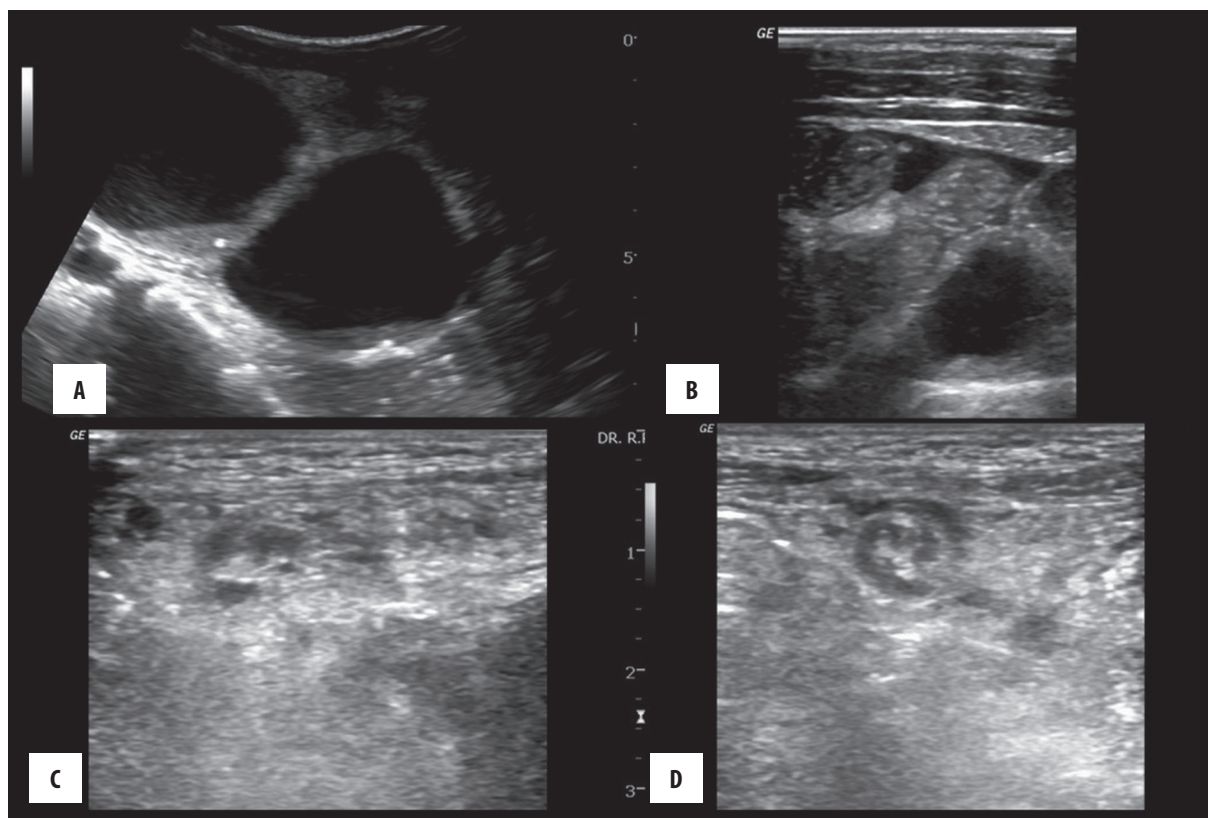


Figure 1. (A) Coronal US image of the lower abdomen showing two well-defined cystic structures with internal debris in the dependent part. (B) Mild ascites. (C, D) Coronal and axial US images showing a whirl of blood vessels along the anterior abdominal wall.

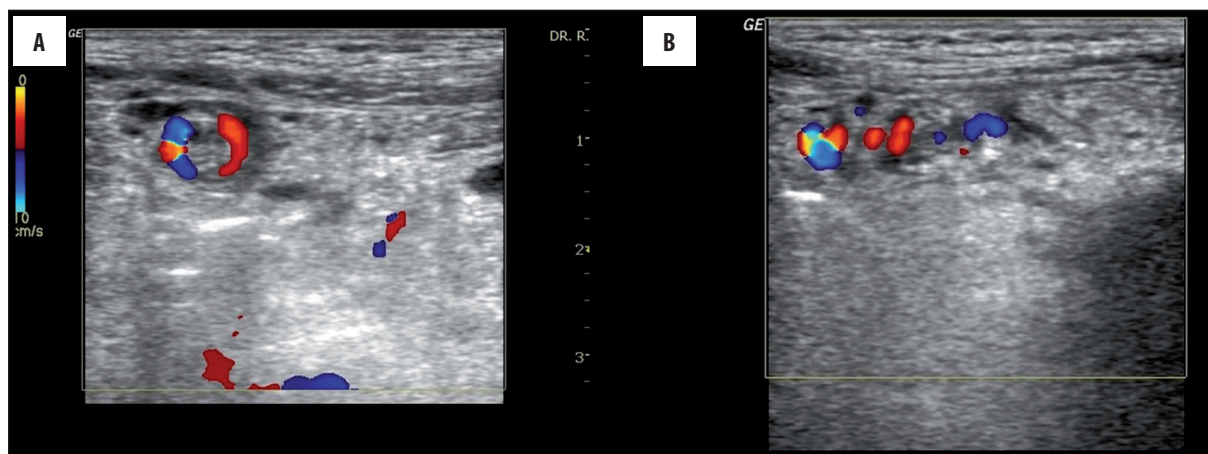


Figure 2. (A, B) The presence of blood flow in the whirl of blood vessels seen along the anterior abdominal wall.

were present. Serum amylase was within normal range. US and CECT (Contrast-enhanced computed tomography) of the abdomen were carried out subsequently. US showed two well defined cystic lesions in the lower abdomen with presence of some internal echogenic debris and calcified foci in their dependent part (Figure 1). There was also the omentum with a "whirl" of blood vessels seen along the anterior abdominal wall, suggesting a torsion. Color Doppler revealed blood flow within that "whirl of vessels" (Figure 2). A mild amount of free fluid was also seen in the peritoneal cavity. On CECT of the abdomen, the omental cysts and torsion of the greater omentum with free fluid in the abdomen were confirmed (Figures 3 and 4). The cysts measured 60×55 and 65×55 mm on CT.

The patient was taken for an emergency laparotomy for acute generalized peritonitis. Two large omental cysts were found in the pelvic cavity with a twisted greater omentum and with 150 mL of hemorrhagic fluid in the peritoneal cavity (Figure 5). The cysts and the twisted necrotic part of the greater omentum were excised during surgery. No postoperative complications were observed. Histopathological examination was suggestive of lymphangioma of the omentum.

Discussion

Omental cysts are mostly benign epithelium-lined cysts most of which are of lymphatic origin [4]. Benign

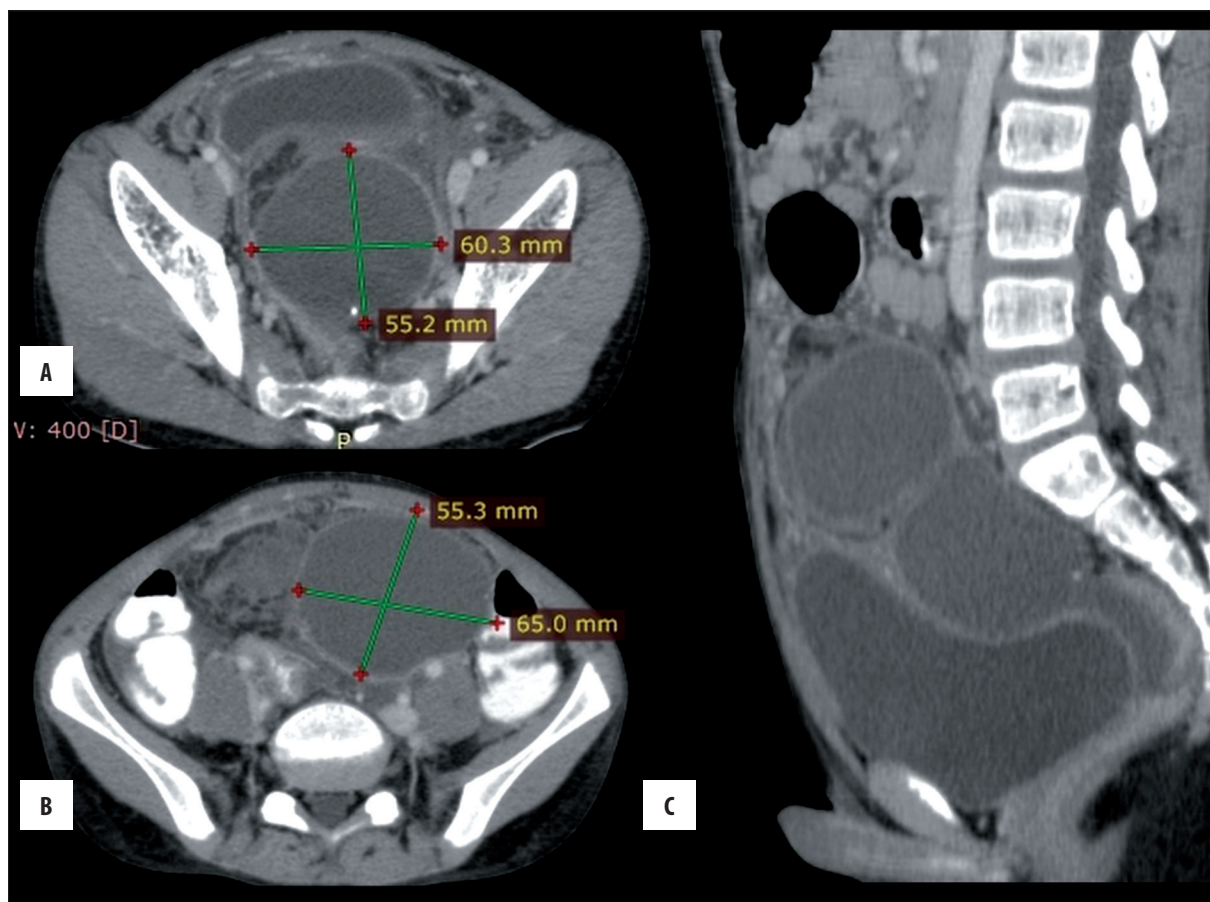


Figure 3. (A, B) Axial and (C) sagittal contrast-enhanced CT images showing two cystic masses in the lower abdomen and pelvis.

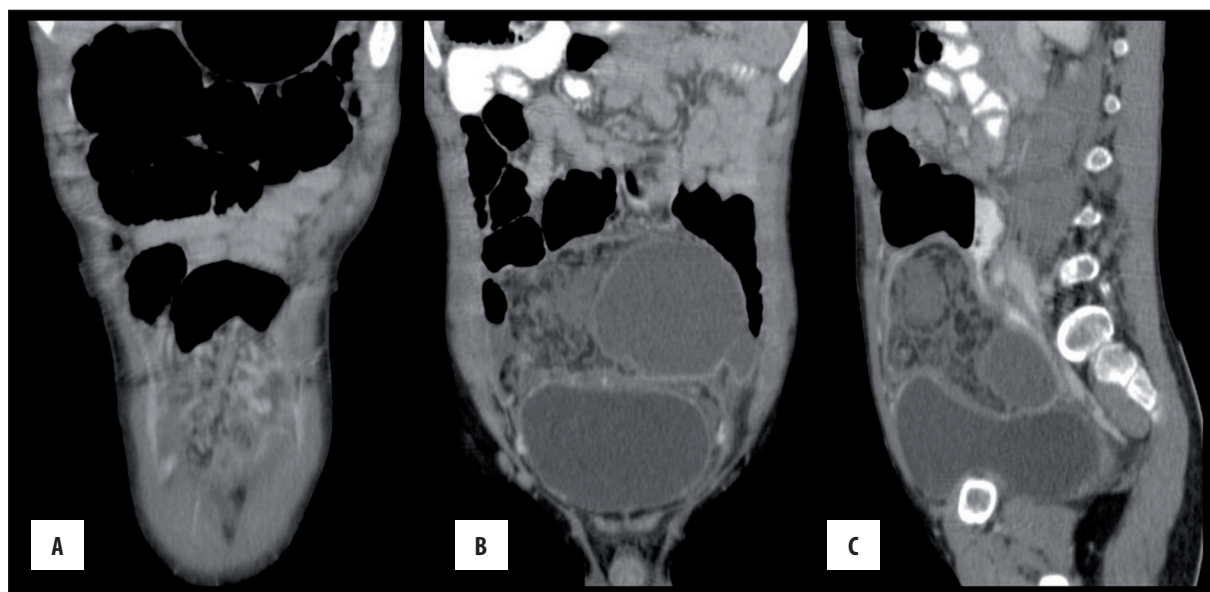


Figure 4. (A) Coronal reformatted CECT image showing a whirl of blood vessels along the anterior abdominal wall leading to omental cysts. (B, C) Coronal and sagittal reformatted CECT images showing a fatty mass with streaks of higher attenuation in the right lower abdomen suggestive of a torsed omentum.

proliferation of ectopic lymphatics which lack communication with the normal lymphatic system may be the etiology [5]. On US, abdominal lymphangiomas present as anechoic cystic masses showing posterior acoustic enhancement

which may be multilocular with the internal septae with or without internal echogenic debris. CT provides further information, such as the exact size, anatomical location, adjacent organ involvement and associated complications,

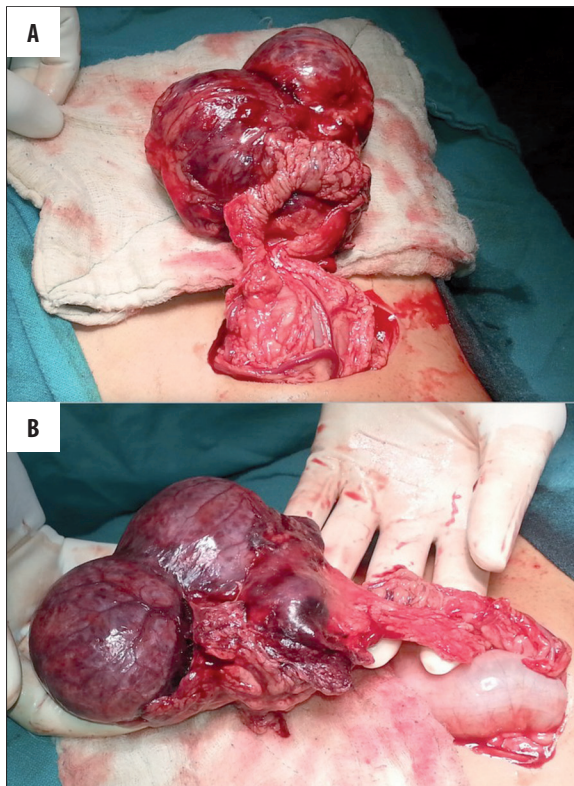


Figure 5. (A, B) Intraoperative images of omental cysts with a torsed omental pedicle. Histopathology was suggestive of lymphangioma.

if any. They present as loculated, thin-walled cystic masses which can show enhancement of the walls and septae after intravenous contrast injection. Calcifications are uncommonly seen [6]. The differential diagnoses of the omental and mesenteric cysts include: congenital duplication of the bowel, intraabdominal abscesses, ovarian masses such as cysts and teratomas, pancreatic tumors, retroperitoneal tumors and lipomas [7]. It may be difficult to differentiate a

large abdominal lymphangioma from ascites [8]. Malignant transformation of a few omental cysts has been reported, including sarcoma and adenocarcinoma. Cystectomy is indicated even if the patient is asymptomatic due to the possibility of complications such as torsion, rupture, hemorrhage and infection [3].

Omental torsion is a rare condition, the preoperative diagnosis of which can be difficult due to the lack of specific clinical findings. The clinical differentials include acute appendicitis, complicated Meckel's diverticulum acute cholecystitis, cecal diverticulitis, appendicitis, twisted ovarian cyst etc. [9,10]. Primary omental torsion is less common than secondary torsion [11]. The more common secondary torsion is associated with adhesion of the free end of the greater omentum to a cyst, tumor, surgical scar, sac of a hernia or an inflammatory focus [12]. Torsion of the omentum due to omental hydatid has also been reported [13]. The twisted omentum may appear as a hyperechoic mass with poor vascularity on US. However, it can be of a limited value in this condition due to the presence of bowel gas and operator dependency [10]. CT is also advocated as the preoperative diagnostic technique [9]. CT and MRI can show specific findings such as a whirling mass of fibrous and fatty tissue around a vascular pedicle, a spiral fat pattern, a fatty mass demonstrating a whirling pattern, a circumscribed fatty mass with streaks of hyper-attenuation, fibrous folds with concentric distribution [14]. Early diagnosis of omental torsion is critical as it can lead to omental necrosis, peritonitis, bowel obstruction, adhesion formation and sepsis. Omentectomy is the traditional treatment option for torsion of the omentum [10].

Conclusions

Lymphangioma of the omentum is not very rare. However, acute presentation with omental torsion and infarction is an unusual entity. Optimal utilization of preoperative imaging with US, Doppler and contrast-enhanced CT can provide a correct diagnosis.

References:

- Egozi EI, Ricketts RR: Mesenteric and omental cysts in children. *Am Surg*, 1997; 63(3): 287-90
- Shackelford GD, McAlister WH: Cysts of the omentum. *Pediatr Radiol*, 1975; 3(3): 152-55
- Shaheen, Hakeem S, Maheshwari V, Bhargava S: A rare combination of omental cyst, ovarian cyst and leiomyoma of uterus. *Journal of South Asian Federation of Obstetrics and Gynecology*, 2010; 2(2): 147-48
- Moralioğlu S, Sönmez K, Türkyılmaz Z: A Child with a Giant Omental Cyst. *Acta Chir Belg*, 2007; 107: 724-25
- Mohite PN, Bhatnagar AM, Parikh SN: A huge Omental Lymphangioma with extension into Labia Majorae: A case report. *BMC Surgery*, 2006; 6: 18
- Rao TN, Parvathi T, Suvarchala A: Omental Lymphangioma in Adults-Rare Presentation Report of a Case. *Case Rep Surg*, 2012; 2012: 629482
- Oh YS, Han SY, Han BR et al: Laparoscopic treatment of an omental cyst misdiagnosed as an adnexal cyst: A case report. *Journal of Women's Medicine*, 2010; 3(2): 84-87
- Lugo-Olivieri CH, Taylor GA: CT differentiation of large abdominal lymphangioma from ascites. *Pediatr Radiol*, 1993; 23(2): 129-30
- Gargano T, Maffi M, Cantone N et al: Secondary Omental Torsion as a Rare Cause of Acute Abdomen in a Child and the Advantages of Laparoscopic Approach. *Eur J Pediatr Surg Rep*, 2013; 1: 35-37
- Tandon AA, Lim KS: Torsion of the greater omentum: A rare preoperative diagnosis. *Indian J Radiol Imaging*, 2010; 20(4): 294-96
- Montiel-Jarquina A, Lopez-Colombob A, Navab A et al: Clinical Characteristics of Torsion of the Omentum. *Gastroenterology Res*, 2009; 2(4): 220-23
- Lo C, Chen T, Liu H, Liu C et al: CT diagnosis of primary torsion of the greater omentum. *European Journal of Radiology Extra*. 2004;52: 69-72
- Parmar HD: The primary torsion omental hydatid cyst: A rare case. *Natl J Med Res*, 2012; 2(3): 391-92
- Papanicolaou C, Biba K, Anthimidis G et al: Secondary torsion of the greater omentum: Report of a case with an interesting characteristic plain abdominal X-ray. *The Internet Journal of Surgery*, 2008; 16(1): 19