

PEDIATRIC UROLOGY

ORIGINAL ARTICLE

# The management of moderate and severe congenital penile torsion associated with hypospadias: Urethral mobilisation is not a panacea against torsion

Adel Elbakry \*, Ahmed Zakaria, Adel Matar, Ahmed El Nashar

Department of Urology, Suez Canal University, Ismailia, Egypt

Received 16 November 2012, Received in revised form 18 December 2012, Accepted 18 December 2012

Available online 24 January 2013

## KEYWORDS

Hypospadias;  
Penile torsion;  
Chordee;  
Urethral mobilisation;  
Urethral plate

**Abstract Objectives:** To evaluate the effectiveness of urethral mobilisation for correcting moderate and severe penile torsion associated with distal hypospadias.

**Patients and methods:** Nineteen patients with distal hypospadias and congenital moderate and severe penile torsion were treated surgically. The hypospadias was at the distal shaft, coronal and glanular in seven, eight and four patients, respectively, and six had mild chordee. The mean (SD, range) angle of torsion was 94.7 (19.9, 75–160)°. The urethra was mobilised down to the perineum. If the urethral mobilisation was insufficient the right border of the tunica albuginea was anchored to the pubic periosteum. The hypospadias was repaired using the urethral mobilisation and advancement technique, with a triangular plate flap for meatoplasty. The patients were followed up for 12–18 months.

**Results:** All patients had a successful functional and cosmetic outcome, with no residual torsion. Two patients had a small subcutaneous haematoma that resolved

\* Corresponding author. Address: Paediatric Urology and Reconstructive Urological Surgery, Suez Canal University, Ismailia, P.O. Box 76, Mansoura 35511, Egypt. Tel.: +20 11 44224994/01067330881/+20 50 2233600; fax: +20 50 2221442.

E-mail addresses: [adelelbakry@yahoo.com](mailto:adelelbakry@yahoo.com), [adelelbakry1@gmail.com](mailto:adelelbakry1@gmail.com) (A. Elbakry).

Peer review under responsibility of Arab Association of Urology.



Production and hosting by Elsevier

after conservative treatment. Massive oedema occurred in three patients and was treated conservatively. Urethral mobilisation did not correct the penile torsion completely. Although the mean (SD, range) angle of torsion was reduced to 86.1 (14.3, 65–130)°, statistically significantly different ( $P = 0.001$ ), it was not clinically important. The presence of chordee had no significant correlation with the reduction of penile torsion.

**Conclusion:** Urethral mobilisation cannot completely correct moderate and severe penile torsion but it might only partly decrease the angle of torsion. Periosteal anchoring of the tunica albuginea might be the most reliable manoeuvre for the complete correction of penile torsion.

© 2013 Arab Association of Urology. Production and hosting by Elsevier B.V. All rights reserved.

## Introduction

Penile torsion can be a congenital, or an acquired lesion after trauma, circumcision or urethral reconstruction. Congenital penile torsion can occur in association with hypospadias or as a single deformity with no hypospadias. The causes and pathogenesis of congenital penile torsion are not exactly known [1–3]. It might be due to abnormal skin attachment, or abnormal development of the dartos fascia that causes disorientation of the penile shaft and corporeal rotation around its longitudinal axis [1]. Extensive unilateral adhesions between the pubic bone and corpus cavernosa was proposed by Zhou et al. [2] as a cause of persistent penile torsion after skin and fascial release. Several techniques have been described to correct penile torsion, but none of these techniques has gained consensus as an optimal, ideal and versatile technique [1–3]. Bhat et al. [3] prospectively studied the effect of urethral mobilisation for correcting penile torsion, and concluded that extensive urethral mobilisation from the corona to the perineum might be a single and adequate corrective procedure in the cases of moderate and severe penile torsion. However, one of the effective techniques for repairing distal penile hypospadias is urethral mobilisation and advancement, which has been used by several authors and given good results [4–6]. Although these clinical reports have no strong evidence-based conclusions they provoked us to explore the outcome of urethral mobilisation as corrective surgery for both the repair of distal hypospadias and associated congenital moderate and severe penile torsion. We evaluated the outcome of urethral mobilisation and advancement for distal hypospadias repair, and estimated whether urethral mobilisation can effectively correct moderate and severe penile torsion and to what extent.

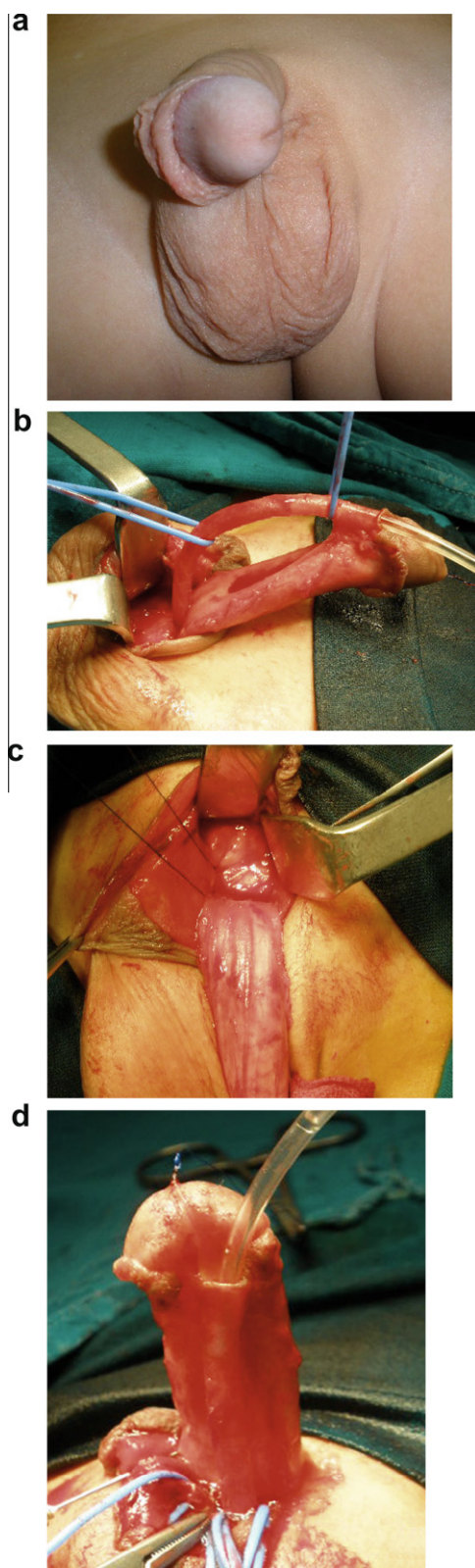
## Patients and methods

In a prospective study, from 2004 to 2010, 19 patients (mean age 3.3 years, SD 1.3, range 1–6) with distal hypospadias and congenital penile torsion had their

hypospadias repaired and penile torsion corrected in our department. Seven patients had distal shaft, eight had coronal and four had glanular hypospadias. Six patients had mild chordee. All patients had penile torsion towards the left side. The angle of penile rotation was measured from the midline using a protractor, giving a mean (SD, range) of 94.7 (19.7, 75–160)° (Fig. 1a). The operative techniques of hypospadias repair and correction of penile torsion were explained to the parents of the children. An informed signed consent was obtained from the parents of all the children and the study was approved by the local ethics committee.

## Operative technique

The angle of torsion was reconfirmed by inducing an artificial erection. A glans traction suture of 4/0 polypropylene was fixed and a suitably sized catheter was introduced into the urethra. A subcoronal circumferential incision was made 2 mm proximal to the hypospadiac orifice, and the penile shaft was degloved down to the base of the penis. Complete penile degloving did not change the angle of penile torsion. The urethral plate was dissected and mobilised, cutting any fibrovascular bands of bifurcated spongiosum attached to the glans. The urethra was mobilised by separating the corpus spongiosum from the corpora cavernosum using a small blunt-tipped and curved scissors that dissected the corpus spongiosum from the corpus cavernosum safely and rapidly, with no injury to the spongiosal envelope. Urethral mobilisation proceeded down to the scrotoperineal junction, using small vein retractors (Fig. 1b). An artificial erection was used to reassess the degree of torsion and the angle was measured after urethral mobilisation. Because the improvement in torsion was partial the pubic periosteum was exposed and the right border of tunica albuginea was anchored to the pubic periosteum using a 4/0 polypropylene suture to correct the anticlockwise torsion (Fig. 1c). The effectiveness of periosteal fixation was tested by a repeated artificial erection. If there was under- or over-correction the suture was readjusted or removed and replaced until the tor-



**Figure 1** a, Coronal hypospadias with a penile torsion of 100°; b, The urethra is mobilised down to the level of the scrotoperineal junction using vein retractors; c, A 4/0 polypropylene suture is taken in the lateral border of the right corpus cavernosum and the pubic periosteum to rotate the penile shaft in a clockwise direction, correcting the torsion; and d, An artificial erection showing the corrected torsion.

sion was optimally corrected, as assessed by an artificial erection (Fig. 1d). The chordee in 6 patients with distal penile and coronal hypospadias was corrected by complete excision of the fibrovascular tissue around the urethral plate at the level of the coronal sulcus; no dorsal tunical plication was needed. A V-shaped incision was made in the glanular part of the urethral plate to fashion a triangular or V-shaped flap which was not separated from the glans tissue. Glans wings were dissected laterally to prepare the glans flaps. The hypospadiac orifice was trimmed to remove the distal few millimetres (3–5 mm) of thin hypoplastic mucosa devoid of supportive spongiosum tissue. The dorsal aspect of the urethra was opened to the extent that was suitable for anastomosis with the V-shaped distal plate flap (Fig. 2a). Suturing of the mobilised urethra to the V-shaped flap was completed using 6/0 polyglactin interrupted sutures. The urethra was fixed to the cavernosal bodies at the midline by a few stitches of 6/0 polyglactin suture (Fig. 2b). The glans flaps were closed at the midline in two layers using 6/0 polyglactin sutures (Fig. 2c). The distal edge of the urethra was fixed to the glans flaps by one stitch on each side. The prepuce was then circumcised and the penile skin closed. A silicone catheter (6–8 F) was inserted and removed after 48 h (Fig. 2d).

#### Follow-up data

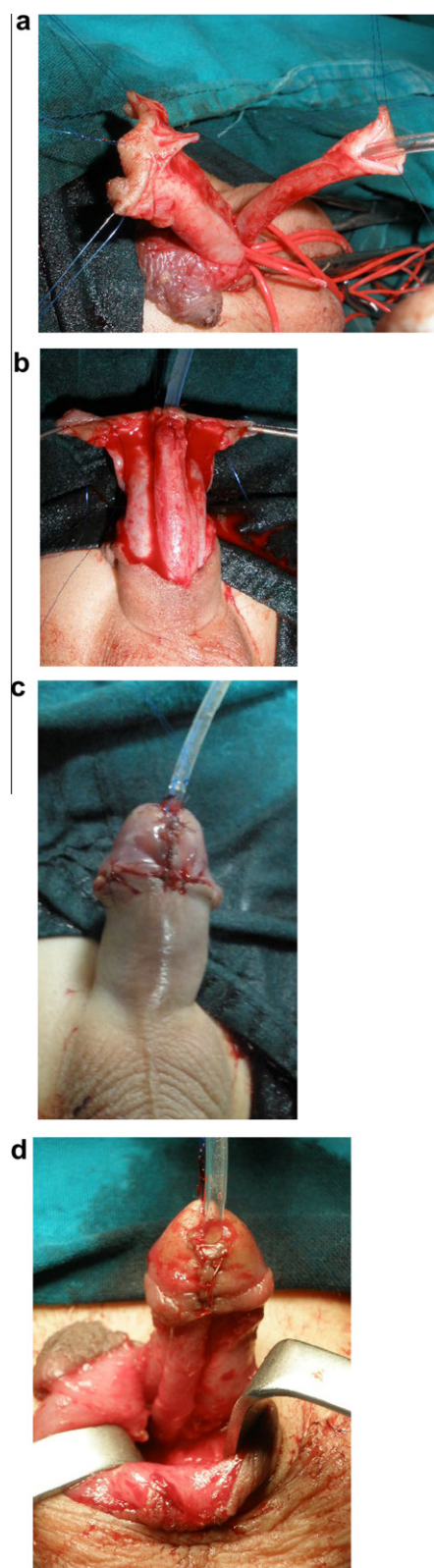
Patients were followed up for a mean (SD, range) of 13.6 (1.9, 12–18) months. The patients were examined every 3 months during the follow-up to assess the site and diameter of the neomeatus and the direction and calibre of the urinary stream. The parents were asked to observe the orientation of the penile shaft and glans during a morning erection.

The Wilcoxon signed-rank test was used to determine whether the urethral mobilisation significantly reduced and/or completely corrected moderate and severe penile torsion. The Mann–Whitney test was used to assess the effect of the presence of chordee on the degree of reduction of the angle of penile torsion after urethral mobilisation.

#### Results

There were acute complications in 5 patients; three had massive oedema, relieved by a compressive dressing and ice-packs, and two had a small subcutaneous haematoma that resolved spontaneously after conservative measures. The hypospadias was repaired successfully in all cases. The neomeatus was vertical and in the midline at the glans tip. There were no urethrocutaneous fistulae, meatal stenosis or penile curvature.

Urethral mobilisation decreased the angle of penile torsion in 12 patients and did not change it in the remaining seven, as indicated by an artificial erection.



**Figure 2** a, The mobilised urethra is spatulated dorsally to be anastomosed to the triangular distal plate; b, Urethral advancement and anastomosis to the urethral plate up to the glans tip; c, Glanular flaps are approximated and glanuloplasty is completed; and d, Skin closure; the glans closure line is in the midline with the scrotal median raphe.



**Figure 3** The optimal correction of penile torsion and a successful hypospadias repair at 3 months after surgery.

The mean (SD, range) reduction in the angle of torsion was 8.7 (7.6, 0–30)°. Thus, after urethral mobilisation the angle of penile torsion decreased from 94.7 (19.7, 75–160)° to 86.1 (14.3, 65–130)°, a statistically significant difference ( $P = 0.001$ ). However, the difference between the angles of torsion before and after urethral mobilisation was trivial in practice and of no clinical significance. The presence of chordee had no significant correlation with the degree of reduction of the angle of penile torsion after urethral mobilisation ( $P = 0.961$ ). Fixation of the lateral border of the right tunica albuginea to the pubic periosteum (periosteal anchoring of the tunica albuginea) was necessary for the optimal and complete correction of penile torsion in all patients. This manoeuvre was repeated once or twice in nine patients to avoid the over- or under-correction of penile torsion. Based on our extensive experience in hypospadias surgery and drug records in the patients' files, the periosteal anchoring suture did not cause significant pain after surgery, and no extra doses of analgesia were required. The corrected position of the penile shaft and glans penis was maintained throughout the follow-up, either when flaccid (Fig. 3) or during a morning erection, as noted by the parents.

## Discussion

Our study indicates that urethral mobilisation extended to the scrotoperineal angle is insufficient for the complete correction of moderate and severe penile torsion, but statistically it significantly reduced the angle of torsion. Periosteal anchoring of the tunica albuginea was

necessary for the complete adjustment of penile torsion. The study also confirmed the reliability of the urethral mobilisation and advancement technique with a glans triangular flap in the repair of distal hypospadias.

Urethral mobilisation and advancement is an old technique used for glanular, coronal and distal penile hypospadias repair. It has several advantages over other techniques, mainly because of a very low incidence of fistula and/or stricture formation, an effect which is logical due to obviating the reconstruction of a neourethra 'hypospadias repair without neourethra' [4–7]. However, the two disadvantages of that technique are the demanding dissection and the separation of the corpus spongiosum from corpora cavernosa, which can be a bloody manoeuvre, and the significant rates of meatal stenosis due to circumferential sutures around the neomeatus [4–6]. The former problem can be avoided by meticulous sharp dissection through the correct plane between the spongiosal and cavernous bodies, using a small and curved blunt-tipped scissors. We have found this method to be easy and rapid, and bleeding is a minor problem. The use of acutely sharp-tipped scissors might cause injury to the spongiosal and/or cavernous bodies, causing significant bleeding and postoperative haematoma. The use of the distal triangular flap of the urethral plate avoids circular fixation of the neomeatus to the glanular tissue, and minimises the possibility of meatal stenosis. The use of a triangular flap at the distal part of the urethral plate for creating a neomeatus and distal neourethra is an old technique. It was advocated in 1973 by Horton et al. [7] in the 'flip-flap' technique for hypospadias repair. Mollaeian et al. [8] used a triangular distal plate flap and urethral mobilisation to manage a large series of distal and midpenile hypospadias; they had no cases of meatal stenosis. Our results for hypospadias repair are similar to those reported by Mollaeian et al. [8]. Although the technique of urethral mobilisation and a distal plate triangular flap has a good outcome in distal hypospadias, it can result in meatal retraction and/or ventral curvature if it is used to repair midpenile hypospadias, because mobilisation of the urethra cannot bridge the deficient length without tension [9]. For an objective judgement of the required extent of urethral mobilisation in relation to the length of the deficient urethra, Atala [6] found that the length of mobilised urethra should be four to five times the length of the deficient segment. Others concluded that mobilisation of the entire penile and bulbar urethra can provide up to 2.5 cm of tension-free extra length in children [10].

Penile torsion is a relatively rare but well-known congenital deformity, but its specific cause and pathogenesis are not known [1,2]. Unlike chordee, which is deviation of a part of penile shaft from the straight longitudinal axis, penile torsion is a right or left rotation of the penile shaft around its longitudinal axis [1–3]. Because the ex-

act cause and pathogenesis of penile torsion is unknown, there are several anti-torsion techniques that have been used for correction. Degloving and re-attachment of penile skin is a simple technique used by several authors [1,10,11]. Others advocated dissection and re-attachment of dorsal dartos fascial flaps to counter-rotate the shaft and correct penile torsion [12,13]. Skin degloving and fascial flap re-attachment techniques give good results in mild cases of penile torsion, but residual and/or recurrent torsion usually occurs because of the unsustainable effect of these techniques, in which the core problem of corporeal rotation is not actually corrected [1,10–13]. Another group of corrective methods for penile torsion is that dealing with the corporeal problem directly. Hsieh et al. [14] described an obliquely orientated plication of the tunica albuginea, and diagonal tunicular plication was advocated by Snow [15]. Slawin and Nagler [16] described the technique of angular tunicular excision in the direction that can counter-rotate the corpora cavernosa. However, these techniques cannot gain wide acceptance due to the risk of injury to the neurovascular bundles and/or erectile tissue. Moreover, these techniques might not be effective in severe penile torsion.

Baht et al. [3] used extensive mobilisation of the urethral plate and urethra for correcting moderate and severe penile torsion in 27 patients; 18 of them had hypospadias. They reported the complete correction of penile torsion by skin degloving in one patient, by mobilisation of the fibrovascular spongiosum and urethral plate into the glans in 13 (48%), by mobilisation of the urethral plate and penile urethra in seven (26%), and by mobilisation of the proximal urethra down to the bulbar urethra in six (22%).

Our findings differ from those reported by Baht et al. [3]. This discrepancy might be explained by the heterogeneity in the pathogenesis and underlying causal factors of the condition. In about half of their patients the penile torsion was due to an asymmetrical attachment of the divergent hypoplastic spongiosum to the glans. More extensive urethral mobilisation down to the bulbous urethra might release adhesions condensed under the pubic bone [2]. The present patients responded minimally to urethral mobilisation, and this was evident on the induction of an artificial erection. Although the difference between the angles of torsion before and after urethral mobilisation was statistically significant, the mean reduction was 8.7°, which was not clinically important. This might indicate an intrinsic longitudinal disorientation of the corpora cavernosa around the longitudinal axis of the penile shaft. Zhou et al. [2] found that the left corpus cavernosum is relatively hypoplastic in cases of penile torsion. Asymmetrical development of the corpora cavernosa around the longitudinal axis of the penis, and/or a fibrous band that tightly attaches the left corpus cavernosum to the pubic periosteum,

might cause persistent penile torsion. Zhou et al. found that releasing that fibrous band was not successful in correcting the penile torsion, because the adhesions were too dense, tough and difficult to dissect and release. Those authors used tunical fixation to the pubic periosteum and concluded that this manoeuvre is the most reliable treatment for such cases of penile torsion. In the present patients the penile torsion was corrected completely using the same technique as that described by Zhou et al. [2]; the outcome was optimal and sustained during the follow-up. Bauer and Kogan [13] retrospectively analysed the correction of penile torsion in 25 patients. They concluded that persistent torsion after the release of chordee is due to fibrosis of Buck's fascia, but their finding lacked histological evidence.

Mobilisation of the urethral plate and corpus spongiosum, and resection of the underlying fibrous bands, might contribute to correcting chordee, with or without division of the urethral plate [3,17]. In 1966, Culp [18] reported 17 cases of hypospadias with chordee and penile torsion. He found that penile torsion was persistent despite the complete removal of chordee. However, Mobley [19] reported that the complete removal of chordee in one case decreased the angle of torsion from 180° to 120°. We found that the presence of chordee had no significant correlation with the degree of reduction of the angle of penile torsion after urethral mobilisation. These data confirm our findings that urethral mobilisation alone might be insufficient for the complete correction of moderate and severe penile torsion. Thus, tunical fixation to the pubic periosteum is the simplest and most reliable technique for correcting the original pathology that causes corporeal rotation.

All of the present patients had penile torsion to the left side. Previous published data indicate that penile torsion is mostly towards the left [2,3,14]. In an epidemiological study of the incidence of penile torsion in neonates, Sarkis and Sadasivam [20] found that penile torsion was counter-clockwise in 99% of affected infants. This phenomenon is not fully understood, but further studies of the embryogenesis of the penile shaft and genital tubercle, and the intrauterine factors that might induce cavernosal disorientation and penile torsion, should be designed and carried out.

There are several limitations to the present study. There were relatively few patients, and not all degrees of penile torsion were included. Cases of hypospadias with mild torsion were not included because the required correction is too simple, and it is not ethical to dissect and mobilise a long urethral segment for these cases. Such mild torsion could be corrected by skin degloving, fascial dissection and reattachment, or by cutting the fanned spongiosum that is asymmetrically attached to the glans [8]. The outcome of the correction of torsion was assessed subjectively by the parents on a morning erection in the child. Another limitation is the lack of tri-

als assessing the cause(s) of the anticlockwise direction of torsion in all of our patients.

We recommend that when hypospadias is associated with moderate and severe penile torsion, then degloving and the release of all fascial attachments should be the first manoeuvres. If the torsion persists totally or partly, then anchoring the tunica albuginea to the pubic periosteum is the most reliable and effective method for correcting torsion. Extensive urethral mobilisation causes a minimal reduction of the angle of penile torsion and should be avoided as an anti-torsion technique.

In conclusion, urethral mobilisation down to the scrotoperineal region is insufficient for the complete correction of moderate and severe penile torsion. It can only reduce the angle of torsion. Periosteal anchoring of the tunica albuginea is the most reliable and sustainable method for correcting moderate and severe penile torsion. This study also confirmed the reliability of the urethral mobilisation and advancement technique with a glans triangular flap in the repair of distal hypospadias. Further studies are needed to understand the pathogenesis of congenital penile torsion.

#### Conflict of interest

None.

#### Source of funding

None.

#### References

- [1] Bar-Yosef Y, Binyamini J, Matzkin H, Ben-Chaim J. Degloving and realignment – simple repair of isolated penile torsion. *Urology* 2007;**69**:369–71.
- [2] Zhou L, Mei H, Hwang AH, Xie HW, Hardy BE. Penile torsion repair by suturing tunica albuginea to the pubic periosteum. *J Ped Surg* 2006;**41**:E7–9.
- [3] Bhat A, Bhat MP, Saxena G. Correction of penile torsion by mobilization of urethral plate and urethra. *J Ped Urol* 2009;**5**:451–7.
- [4] Koff SA. Mobilization of the urethra in the surgical treatment of hypospadias. *J Urol* 1981;**125**:394–7.
- [5] Nasrallah PF, Minott HB. Distal hypospadias repair. *J Urol* 1984;**131**:928–30.
- [6] Atala A. Urethral mobilization and advancement for midshaft to distal hypospadias. *J Urol* 2002;**168**:1738–41.
- [7] Horton CE, Devine CJ, Baran N. Pictorial history of hypospadias repair techniques. In: Horton CE, editor. *Plastic and Reconstructive Surgery of the Genital Area*. Boston: Little Brown; 1973. p. 237–48.
- [8] Mollaiean M, Sheikh M, Tarlan S, Shojaei H. Urethral mobilization and advancement with distal triangular urethral plate flap for distal and select cases of mid shaft hypospadias: experience with 251 cases. *J Urol* 2008;**180**:290–4.
- [9] Warwick RT, Parkhouse H, Chapple CR. Bulbar elongation anastomotic meatoplasty (BEAM) or subterminal and hypospadiac urethroplasty. *J Urol* 1997;**158**:1160–7.
- [10] Redman JF, Bissada NK. One-stage correction of chordee and 180-degree penile torsion. *Urology* 1976;**7**:632–3.

- [11] Azmy A, Eckstein HB. Surgical correction of torsion of penis. *BJU Int* 1981;**53**:378–9.
- [12] Fisher PC, Park JM. Penile torsion repair using dorsal dartos flap rotation. *J Urol* 2004;**171**:1903–4.
- [13] Bauer R, Kogan BA. Modern technique for penile torsion repair. *J Urol* 2009;**182**:286–91.
- [14] Hsieh JT, Wong WY, Chen J, Chang HJ, Liu SP. Congenital isolated penile torsion in adults: untwist with placcation. *Urology* 2002;**59**:438–40.
- [15] Snow BW. Penile torsion correction by diagonal corporal plication sutures. *Int Braz J Urol* 2009;**35**:56–9.
- [16] Slawin KM, Nagler HM. Treatment of congenital penile curvature with penile torsion: a new twist. *J Urol* 1992;**147**:152–4.
- [17] Acimi S. Proximal hypospadias. Effect of urethral mobilization on release of chordee. *Urology* 2012;**80**:894–8.
- [18] Culp OS. Struggles and triumphs with hypospadias and associated anomalies: review of 400 cases. *J Urol* 1966;**96**:339–51.
- [19] Mobley JE. Congenital torsion of the penis. *J Urol* 1973;**109**:517–9.
- [20] Sarkis PE, Sadasivam M. Incidence and predictive factors of isolated neonatal penile torsion. *J Ped Urol* 2007;**3**:495–9.