

A novel insertion technique for urinary catheters in female dogs with the use of a guidewire

Joris H. Robben DVM, PhD, DECVECC, DECVIM 

Division of Emergency and Intensive Care Medicine, Department of Clinical Sciences, Faculty of Veterinary Medicine, Utrecht University, Utrecht, the Netherlands

Correspondence

Dr. Joris H. Robben, Division of Emergency and Intensive Care Medicine, Department of Clinical Sciences, Faculty of Veterinary Medicine, Utrecht University, Yalelaan 108, 3584 CM Utrecht, the Netherlands.
Email: j.h.robben@uu.nl

Abstract

Background: Complicated transurethral urinary bladder catheterization in female dogs is a commonly encountered urologic problem, often causing inadvertent trauma to the lower urinary tract and breach in aseptic technique.

Key Concepts: A novel method for transurethral insertion of urinary catheters in female dogs is described. The main variation from current procedures involves the application of the Seldinger technique with the use of an introduction catheter that is specifically designed to feed into the urethra, and the use of a guidewire to replace the introducer with an indwelling balloon catheter.

Significance: The technique presented offers a step-by-step approach that could improve success in urinary catheter placement. This modification may facilitate catheter insertion, be less traumatic, and offer better control of asepsis, especially with challenging urethral catheterization. The technique also offers an easy method to replace the catheter. Application of the technique may reduce catheter-associated urinary tract infections as it addresses certain infection-related risk factors. Prospective validation studies are needed to support its advantages over current urinary catheter placement techniques.

KEYWORDS

Foley, lower urinary tract, Seldinger, urinary tract—small animal, urination

1 | INTRODUCTION

Doctor Sven Ivar Seldinger, a Swedish radiologist, published a technique that bears his name for the first time in 1953.¹ This technique originally resolved catheter-associated problems related to percutaneous angiography that were until then in essence through-the-needle techniques. Seldinger's introduction of a flexible, round-ended, metal leader (guidewire) offered the possibility to replace a percutaneously inserted, rigid, sharp introduction needle with a more flexible and potentially longer catheter with the same or a slightly larger diameter. This reduced the risk of hemorrhage and vessel damage, and

enabled the catheterization of comparatively smaller arteries. Since its introduction, the procedure has become known under different synonyms, such as the “guidewire insertion procedure” or “over-the-wire technique.” Over more than 50 years, the technique has been adapted to a multitude of clinical situations and organ systems, supporting new applications such as the insertion of instrumented and multilumen catheters, easy replacement of (nonfunctional) catheters, percutaneous positioning of stents, or gaining alternative access as with percutaneous nephrostomy.²

Any veterinary clinician and technician knows how challenging the introduction and maintenance of an indwelling urinary catheter in

This is an open access article under the terms of the [Creative Commons Attribution-NonCommercial](https://creativecommons.org/licenses/by-nc/4.0/) License, which permits use, distribution and reproduction in any medium, provided the original work is properly cited and is not used for commercial purposes.

© 2020 The Authors. *Journal of Veterinary Emergency and Critical Care* published by Wiley Periodicals LLC on behalf of Veterinary Emergency and Critical Care Society

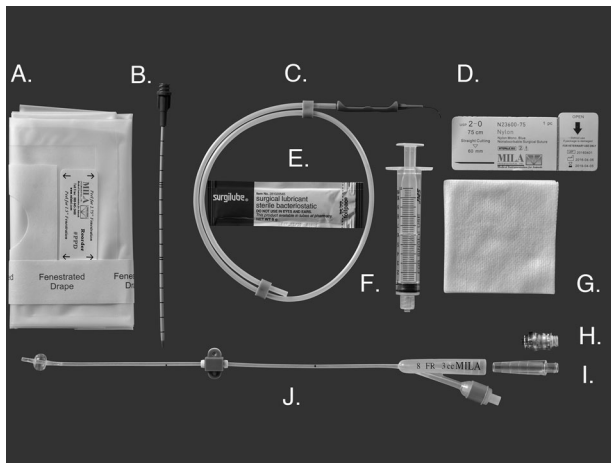


FIGURE 1 The components of the female canine guidewire inserted Foley catheter kit. (A) Fenestrated sterile drape, (B) introducer with soft tip, (C) hydrophilic guidewire, (D) 3-0 suture pack, (E) lubricating gel, (F) 10-mL syringe, (G) sterile gauze, (H) needle free port, (I) barbed adapter, (J) open-ended Foley catheter, female Luer-lock with suture wing and cover

female dogs can be. While the introduction of a more rigid catheter is easier, once in position it can traumatize the urinary bladder wall.³ On the other hand, more flexible urinary catheters can be very challenging to insert but have the advantage that they are less traumatic once in place. A modified Seldinger technique is described that offers the possibility to combine the best characteristics of both catheter types and may resolve several issues related to current placement of a transurethral indwelling catheter in female dogs.

2 | MATERIAL AND METHODS

Aside from standard equipment and materials necessary for urinary catheter placement, the following materials are needed: an introducer catheter with a Luer-lock and a soft angled tip; a synthetic, hydrophilic guidewire; and a radiopaque, open-ended silicone indwelling urinary catheter with a 3.0 mL balloon cuff (Foley catheter; Figure 1).

The following outline describes the introduction of the indwelling Foley urinary catheter using a modified Seldinger technique. A more detailed description of the technique for transurethral insertion of urinary catheters, with aspects that may also apply to this technique, can be found elsewhere.³

1. Palpate the cranial rim of the pubic bone and measure the distance between the vulva and the cranial rim to determine the depth the indwelling catheter should be inserted. The balloon of the Foley catheter should sit cranial to the pelvic inlet.
2. Clip and surgically prepare the perivulvar area, vulva, and vestibule according to standard hospital procedures with special attention to the technique of asepsis.
3. The introducer and indwelling catheter are prepared prior to the introduction by flushing with a sterile isotonic electrolyte solution.

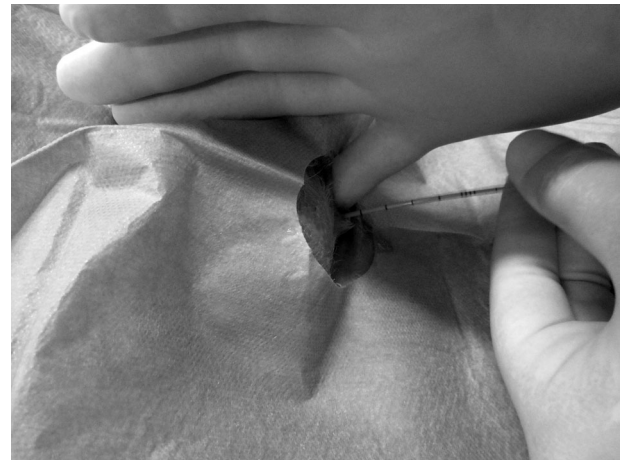


FIGURE 2 The introducer is advanced by digital palpation through the vaginal vestibule and urethra into the urinary bladder



FIGURE 3 The guidewire is advanced into the bladder through the introducer

This will enable the catheters to slide over the guidewire more easily. Confirm the patency and fluid retention of the Foley catheter balloon.

4. Sterile lubricating gel is applied to the tip of the introducer and the operators' fingers. Use digital palpation or visualization methods to advance the introducer through the vestibule and into the urethral opening; continue feeding into the urinary bladder (Figure 2).
5. Advance the guidewire with the use of its container via the introducer into the bladder (Figure 3). The length of the guidewire left outside the vulva should have the full length of the Foley catheter that will be used, plus a few centimeters extra.

Note: as the guidewire can slip out of the urethra by accident while performing the next step and picking up the Foley catheter, it may help to initially insert the guidewire 10-20 cm deeper than necessary and pull it out to the right position immediately prior to the introduction of the indwelling catheter.

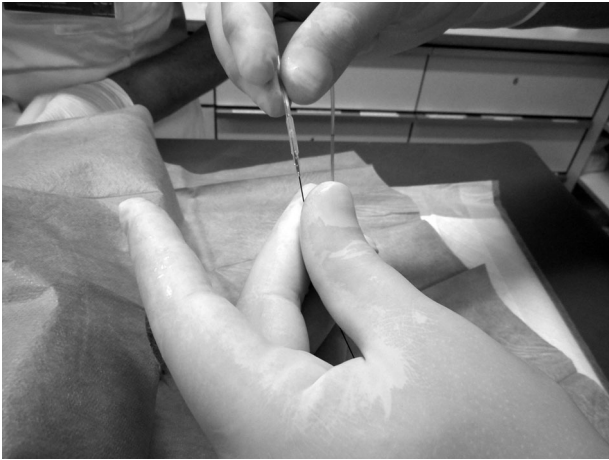


FIGURE 4 The open-ended Foley catheter is placed over the guidewire



FIGURE 6 The indwelling Foley catheter is guided over the guidewire into the urinary bladder

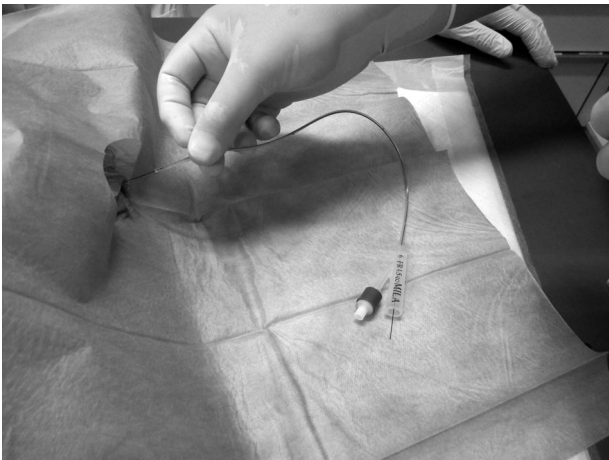


FIGURE 5 In order to grasp the guidewire, it must protrude a few centimeters out of the funnel of the Foley catheter before guiding the indwelling catheter over the guidewire past the vulva

6. Remove the introducer over the guidewire, while leaving the guidewire in place. Ensure the guidewire does not come out while guiding the introducer back over and off the guidewire.
7. Place the open-ended indwelling catheter over the guidewire (Figure 4). Make sure the guidewire protrudes a few centimeters out of the funnel of the Foley catheter. Next, the indwelling catheter can be guided over the guidewire, past the vulva, into the vestibule and urethra (Figure 5).
8. Advance the indwelling catheter deep into the urinary bladder to ensure the balloon of the catheter sits clearly in the bladder lumen, before filling the balloon with sterile water or electrolyte solution according to the manufacturer's instructions (Figure 6).
9. Determine, by slightly moving the indwelling catheter back and forth, if the balloon sits freely in the bladder lumen. The balloon should not sit in the bladder neck as it can cause the dog to strain.
10. Remove the guidewire while holding the indwelling catheter near the vulva.

11. Urine should flow freely out of the catheter. If not, check patency by infusing sterile fluid into the catheter and aspirate with a syringe. To check the position of the indwelling catheter, a radiograph or ultrasound can be performed.
12. Affix the indwelling catheter according to hospital procedure. In-hospital maintenance of the urinary catheter requires a sterile, closed urine collection system to maintain cleanliness and minimize bacterial contamination.

3 | DISCUSSION

Although more rigid (eg, polyvinylchloride or polypropylene) urinary catheters can be easier to insert, they tend to damage the urinary bladder wall once in position.^{3,4} Mainly for this reason, they are often not used as indwelling catheters in dogs. More flexible (eg, silicone or polyurethane) catheters are less likely to cause trauma, but in the author's experience have some serious drawbacks related to placement. They are difficult to guide through the vestibule of the vagina, and especially the external urethral orifice. This can lead to multiple, time-consuming attempts. Often a metal stylet is used to give the flexible urinary catheter more rigidity. However, the stiffness that is obtained with a metal stylet is often still insufficient. Also during manipulation, the wire tends to get dislodged, either by backing out of the catheter leaving the tip again too flexible or, by exiting the catheter through a side hole.³ The latter is often a result of the elasticity of the catheter material and moving the catheter in and out of the urogenital system during the insertion attempts. The inadvertent trauma, that is, mucosal or even deeper lacerations, to the lower urinary tract caused by these manipulations, may lead to unnecessary discomfort and pain in our patients.

The described modified Seldinger technique offers several potential advantages over currently applied methods of catheter introduction. The relatively short introduction catheter that has the right rigidity but still a flexible tip, may handle much more easily than a longer

urinary catheter. This may help shorten average time for gaining transurethral access to the urinary bladder and be less traumatic. Any obstructions caused by urethral mucosal folds can be effectively overcome with the use of some saline flush while advancing the introducer, if necessary. With a narrower vulva and vaginal vestibule in which finger guidance of the catheter is impossible, a more rigid introducer aids with an unguided, blind introduction of the catheter into the urethra.

Catheter-related infections in the ICU occur in 8.3% to 19% of dogs with an indwelling catheter.⁵⁻⁷ Strict protocols to maintain asepsis during insertion and maintenance are considered crucial in reducing the risk of the development of a catheter-related urinary tract infection.^{5,7} This modified Seldinger technique may improve the aseptic technique of urinary catheter placement. First, the potentially shortened time to gain access and insert the indwelling catheter with fewer attempts contributes to the asepsis of the procedure. Second, less trauma to the lower urinary tract may also decrease chances of lower urinary tract infections. Third, the indwelling catheter is not used to gain access to the urinary bladder but stays sterile until access has been obtained and the catheter can be inserted with a single action.

A urinary catheter that is in place for more than 6 days is an important risk factor for development of urinary tract infection in people.^{8,9} Besides the increased risk related to time, the formation of a biofilm has been considered a potential complicating factor.¹⁰ The modified Seldinger technique offers a simple way to replace an indwelling urinary catheter. This could also help reduce the risk of urinary bladder contamination and infection.

The use of the guidewire could be a challenging aspect of the modified Seldinger technique. The guidewire is relatively long and sometimes difficult to control, and can easily compromise the aseptic technique. Guidewires may slip out of the urinary tract and it may be hard to estimate how far it has been fed into the lower urinary tract. As the guidewire ends in the lumen of the urinary bladder it could become knotted, especially if inserted too far. This would prevent introduction of the indwelling catheter. However, because of the small diameter of the thin, flexible, synthetic guidewire used here, even with a knot, the guidewire could likely be extracted without any problems.

The Foley catheter must be guided over the guidewire and because the length of the guidewire has its practical limits, the length of the Foley catheter also has to be limited. Since the urinary tract in female dogs is relatively short compared to male dogs, this should not be a problem. However, this indwelling catheter is shorter than certain urinary Foley catheters currently available for use in both male and female dogs. Therefore, the shorter Foley catheter may increase the risk of the balloon not residing in the bladder lumen after placement, especially in large dogs. One should be aware of this risk and pay special attention to a correct positioning of the balloon of the Foley catheter.

Prospective validation studies are needed to support the potential advantages of this urethral catheterization technique, especially the reduced incidence of catheter-associated urinary infections, over current urinary catheter placement techniques.

ORCID

Joris H. Robben DVM, PhD, DECVECC, DECVIM  <https://orcid.org/0000-0001-8606-4096>

ENDNOTE

* Female Canine Guidewire Inserted Foley Catheter Kit, MILA International Inc., Florence, KY.

ACKNOWLEDGMENTS

The author thanks Jeff Vitullo (Mila International Co.) for his continuous support and technical feedback, and all the ICU technicians who contributed by testing and giving feedback on the use of the kit.

The guidewire-inserted urinary catheter kit was developed with the technical and financial support of Mila International Co. The author did not receive any personal financial compensation.

CONFLICT OF INTEREST

The author declares no other conflict of interest.

REFERENCES

1. Seldinger SI. Catheter replacement of the needle in percutaneous arteriography: a new technique. *Acta Radiol.* 1953;39(5):368-376. <https://doi.org/10.3109/00016925309136722>.
2. Higgs ZCJ, Macafee DAL, Braithwaite BD, et al. The Seldinger technique: 50 years on. *Lancet.* 2005;366:1407-1409. [https://doi.org/10.1016/S0140-6736\(05\)66878-X](https://doi.org/10.1016/S0140-6736(05)66878-X).
3. Aldrich J. Urethral catheterization. In: Burkitt Creedon JM, Davis H, eds. *Advanced Monitoring and Procedures for Small Animal and Critical Care.* Hoboken, NJ: Wiley-Blackwell; 2012:395-408.
4. Lees GE, Osborne CA, Stevens JB, et al. Adverse effects caused by polypropylen and polyvinyl feline urinary catheters. *Am J Vet Res.* 1980;41:1836-1840.
5. Smarick SD, Haskins SC, Aldrich J, et al. Incidence of catheter-associated urinary tract infection among dogs in a small animal intensive care unit. *J Am Vet Med Assoc.* 2004;224:1936-1940.
6. Ogeer-Gyles J, Mathews K, Weese JS, et al. Evaluation of catheter-associated urinary tract infections and multi-drug-resistant *Escherichia coli* isolates from the urine of dogs with indwelling urinary catheters. *J Am Vet Med Assoc.* 2006;229:1584-1590.
7. Sullivan LA, Campbell VL, Onuma SC. Evaluation of open versus closed urine collection systems and development of nosocomial bacteriuria in dogs. *J Am Vet Med Assoc.* 2010;237:187-190.
8. Platt R, Polk BF, Murdock B, et al. Risk factors for nosocomial urinary tract infection. *Am J Epidemiol.* 1986;124:977-985.
9. Maki DG, Tambyah PA. Engineering out the risk of infection with urinary catheters. *Emerg Infect Dis.* 2001;7:342-347.
10. Segev G, Bankirer T, Steinberg D, et al. Evaluation of urinary catheters coated with sustained-release varnish of chlorhexidine in mitigating biofilm formation on urinary catheters in dogs. *J Vet Int Med.* 2013;27:39-46.

How to cite this article: Robben JH. A novel insertion technique for urinary catheters in female dogs with the use of a guidewire. *J Vet Emerg Crit Care.* 2020;30:597-600. <https://doi.org/10.1111/vec.12999>