



A case report of the world largest spindle cell renal tumor (9 kg) with longest survival, removed by innovative technique

Feraidoon Khayyamfar^a, Farzaneh Gholfam^b, Parvin Delavar^a, Mohamadreza Mirzabozorg^c, Naheed Hamzehi Esfahani^a, Amirmahdi Khayyamfar^{d,*}

^a Department of Urology, Maostafa Khomainsi Hospital, Shahed Medical College, Shahed University, Tehran, Iran

^b Department of General Surgery, Maostafa Khomainsi Hospital, Shahed Medical College, Shahed University, Tehran, Iran

^c Department of Pathology, Maostafa Khomainsi Hospital, Shahed Medical College, Shahed University, Tehran, Iran

^d Student Research Committee, School of Medicine, Iran University of Medical Sciences, Tehran, Iran

ARTICLE INFO

Keywords:

Kidney cancer
Nephrectomy
Spindle cell tumor
Largest renal tumor

ABSTRACT

Renal cell carcinoma includes about 2% of global cancer and mostly diagnosed in early stages due to wide usage of imaging studies, in this article we report a huge 9 kg renal mass.

A 54 years old woman consulted for her stomach ache, in the CT scan study, it revealed a huge abdominal mass occupying most of the abdomen and pelvic area. Innovative surgical resection was performed. Our 9kg renal mass was the first and largest fully solid spindle cell renal tumor, with the longest survival ever reported.

Introduction

Renal cell carcinoma (RCC) is the ninth most common cancer and includes about 2% of global cancer, and nowadays renal masses are diagnosed in early stages due to the increased use of imaging studies; therefore, presentation as a very large mass is rarely encountered if they remain undiagnosed, renal tumors can grow to huge sizes because of their ability to create new vessels for supporting their growth.^{1,2}

In this article, we report a patient with a huge renal mass, probably the world's largest spindle cell tumor removed, which was weighted 9 kg.

Case presentation

A 54 years old woman weighed 120 kg and with a height of 168 cm (body mass index: 42.52) consulted a gastroenterologist for her stomachache. She was found to have a hard fixed massive abdominal mass extending from below of her rib cage to the left lower of the abdomen on her first clinical examination. All laboratory tests were normal. The patient was using Tab Levothyroxine 1.5 mg daily for her hypothyroidism. Abdominal computed tomography revealed a 48 cm abdominal mass occupying most of the abdomen and pelvic area. (Fig. 1).

Due to the very large size of the tumor, there was a major vascular challenge, a tumor growing from the left kidney that pushed all the

bowels to the opposite side. Full bowel preparation was given to the patient to reduce the complications of bowel damage.

The patient was placed in a supine position, and a midline incision was made from the xiphoid process to the pubic symphysis. Abdominal fascia was opened, and then transverse and descending colon were dissected to approach the left kidney in retroperitoneum. A large mass was felt from the very left and upper abdominal cavity to the lower abdomen. A meticulous dissection was done around the tumor, and a bipolar clamping device was used all through the surgery for dissection and production of hemostasis to decrease intraoperative bleeding during the kidney dissection from surroundings by LigaSure™, suture ligation was required for the large vessels very few times less than five suture ligation and LigaSure™ was capable of hemostasis and cutting off all collaterals which were supplying the mass from surroundings. After freeing all tumors from surrounding tissues, renal pedicle and its surrounding tissue became accessible but it was difficult to dissect.

Dissection was getting more difficult by getting close to the pedicle, so we decided to use a new technique for controlling the renal pedicle by using a midline incision to have better access to hold the kidney.

So, we passed several through and through 1/0 silk sutures (1 cm apart) by passing a needle in a stepwise manner to cover all the vessels passing through the area between the aorta, vena cava, and a large renal mass (Fig. 2), a sudden ligation of all the threads that have been passed all over the pedicle was made and the pedicle was cut by knife, distal to

* Corresponding author.

E-mail address: a.khayyamfar@gmail.com (A. Khayyamfar).

<https://doi.org/10.1016/j.eucr.2022.102011>

Received 13 December 2021; Received in revised form 18 January 2022; Accepted 23 January 2022

Available online 25 January 2022

2214-4420/© 2022 The Authors.

Published by Elsevier Inc.

This is an open access article under the CC BY-NC-ND license

(<http://creativecommons.org/licenses/by-nc-nd/4.0/>).

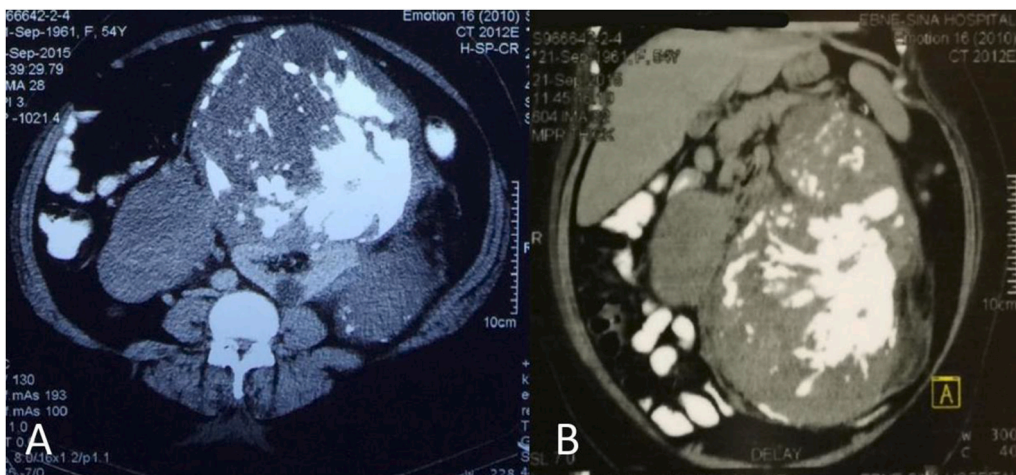


Fig. 1. Abdominal CT images (A: axial view, B: coronal view).

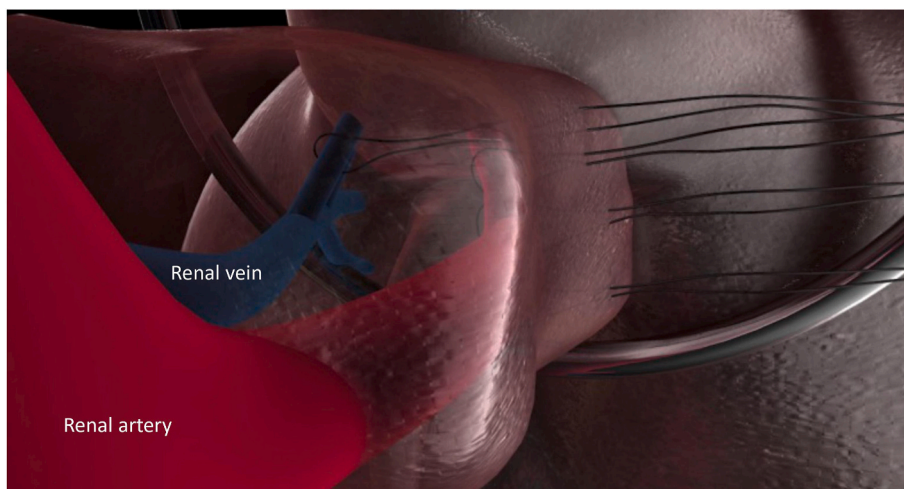


Fig. 2. Schematic view of through and through suturing.

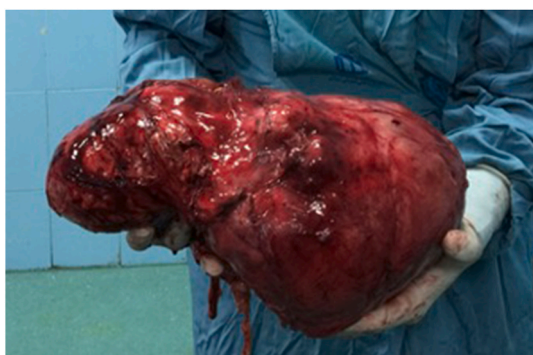

Fig. 3. The main bulk of the tumor.

the ligated area. The kidney was removed with no major bleeding. The weight of the main renal mass was 7500 gr. There were another two masses removed (sized 15-12-8 cm and 7-5-5 cm, weighted 900 gr and 600 gr) close to the renal mass as well (Fig. 3).

Patient’s bleeding during the surgery was estimated to be 600 ml. Her admission hemoglobin was 11.8 g/dL, one unit of packed red blood cells was infused at the end of the surgery. One unit of fresh frozen plasma (FFP) on the first postoperative day, and another unit of packed

red blood cells on the third postoperative day was infused, immediate postoperative hemoglobin was 10.5 g/dL. Microscopically, the tumor consisted of low-grade spindle cell carcinoma.

The patient had hypoxia (O2 saturation of 70%) with peripheral and central cyanosis on the second, third, and fourth postoperative days, which was managed by blood transfusion, IV hydration, and oxygen mask throughout the cyanotic period.

Finally, the patient was discharged on the 7th postoperative day stable and with no distinguishable complaints. During follow-up, two small (5,2,3, cm) masses were seen at the site of the previous surgery at the third postoperative month. One year after the initial surgery, the patient was operated for mass removal and incisional hernia. On long follow-up, patient died after three and a half years due to pelvic metastasis.

Discussion

Literature search was performed using the PubMed database for published case reports of large renal tumors. Several cases of giant renal cell carcinomas have been reported in the literature. Surgical exploration and removal of these large tumors need meticulous surgical skills. The difficulty includes gaining access to the renal hilum, minimizing blood loss, and avoiding damage to the surrounding tissues.³ An innovative technique for closure of renal vessels was used, and we know that

renal pedicles ligation in this manner has a risk of arteriovenous fistula, but by using several through and through suturing, this risk would decrease. Avoiding losing blood during this difficult dissection might have been worth it. Large renal tumors are mostly malignant neoplasms.⁴ Currently, the largest reported renal tumor is a 13kg RCC, which was mostly consists of cystic components.³ To the best of our knowledge, our 9 kg renal mass was the first and the largest fully solid spindle cell renal tumor, with the longest survival ever reported. Histology of the tumor was reported as low-grade spindle cell carcinoma, described as a rare type of RCC that is an epithelial tumor with proximal tubular differentiation with a survival between 4 and 38 months.⁵

Patients with large RCC usually have a poorer prognosis because of the tumor's slow growth; during the long period of having the tumor, nearly 33% of the patients have metastasis at the time of diagnosis.¹

Conclusion

Patients with renal tumors are usually present with no renal

symptoms and may have unrelated complaints. Teamwork, Adequate operating exposure by large skin incision, using innovative techniques for the renal hilar vessels, and the help of a vascular surgeon may cause a better and safer surgical removal of large renal tumors.

References

1. Padala SA, Barsouk A, Thandra KC, et al. Epidemiology of renal cell carcinoma. *World J Oncol.* 2020 Jun;11(3):79–87.
2. Sawh LR, Budhooram S, Ewe P, Rattan R, Sawh SL. A case report of one of the largest {3.63kg} renal tumour removed in the Western Hemisphere. A combined Uro vascular approach for complete removal. *Int J Surg Case Rep.* 2016;24:156–161.
3. Takeda K, Murray G, Vohra N, Fallon JT. A case of the world's largest renal cell carcinoma. *LJU Case Rep.* 2021 Jan;4(1):49–52.
4. Taneja R, Singh DV. Giant renal angiomyolipoma: unusual cause of huge abdominal mass. *J Clin Imaging Sci.* 2013 Nov 28;3:56.
5. Shen SS, Ro JY, Tamboli P, et al. Mucinous tubular and spindle cell carcinoma of kidney is probably a variant of papillary renal cell carcinoma with spindle cell features. *Ann Diagn Pathol.* 2007 Feb;11(1):13–21.