



Contents lists available at ScienceDirect

International Journal of Surgery Case Reports

journal homepage: www.casereports.comIatrogenic retained foreign body in the right atrium. Lessons to Learn[☆]Charles H. Choi, Maqsood M. Elahi^{*}, Subbareddy Konda

Division of Cardiothoracic Surgery, Department of Surgery, Texas A&M Health Science Center at Scott & White Memorial Hospital, 2401 S. 31st Street, Temple, TX 76508, USA

ARTICLE INFO

Article history:

Received 3 May 2013

Received in revised form 4 July 2013

Accepted 8 July 2013

Keywords:

Foreign body

Right Atrium

Atrial thrombus

Minimally invasive

Plastic cannula

ABSTRACT

INTRODUCTION: We report a case of a retained foreign body in the right atrium and the review of the literature discussing several cases where the poor attention and management of medical staff has led to worsening consequences to patient's health.

PRESENTATION OF CASE: In our case the mass demonstrated on MRI scan turned out to be an inflammatory process and organized clotted blood built around a broken piece of a plastic cannula protruding out of the right atrium. This caused debilitating pleuritic pain to the patient on presentation.

DISCUSSION: The cause of this iatrogenic retained piece of cannula may well be from the patients prior diagnostic investigations.

CONCLUSION: Algorithm managed indications for surgical removal of such foreign bodies in symptomatic patients lead to better patient's outcomes and decreases the chances of infection, embolization, or erosions within the heart. Keeping this in view, we managed our patient with success.

© 2013 The Authors. Published by Elsevier Ltd on behalf of Surgical Associates Ltd. All rights reserved.

1. Introduction

Literature describes several case reports of retained intracardiac foreign bodies especially in left sided chambers. Our aim was to report a case of an unusual foreign body that extended from the right atrium to the tricuspid valve, thus causing tricuspid regurgitation. Minimally invasive approach was utilized to excise the foreign body mass with an embedded plastic cannula in it.

2. Presentation of case

A 42 year-old caucasian female without significant past medical history, other than a history of status post ablation left leg varicosities, presented to the ED with the complaint of ongoing chest pain. She described the unbearable pain as sharp, pleuritic in nature, originating under her left breast and radiating to her back and neck. Even when taking a deep breath, the patient defines the pain as, "it is like somebody sticking a knife into her chest." She denied any frank shortness of breath, fever, nausea or vomiting and had not been diaphoretic. The cardiac biomarkers and electrocardiogram at the time of presentation were unremarkable. Subsequent chest X-ray and V/Q scans performed demonstrated no acute cardiopulmonary abnormality and a low probability for a pulmonary embolus

respectively. On further exploring her medical history, it was noticed that post ablation of her left leg varicosities, she developed deep vein thrombosis of the right lower extremity and hence was commenced on anticoagulants.

Given that, she underwent a contrast magnetic resonance imaging (MRI) of chest for cardiac morphology and function. MRI demonstrated a mobile mass in the right atrium with echo-dense linear structure extending from the right atrium to the tricuspid valve causing tricuspid regurgitation (TR Fig. 1a). The dilemma of her excruciating pain symptoms still remained unclear and the right atrial mass causing TR was thought to be plausible endocarditis in nature.

She was taken to operating theatre for removal of the right atrial mass via minimally invasive approach. The femoral artery and veins were dissected and used for cardiopulmonary bypass (CPB) cannulation source. CPB was established after heparinization. Right anterior mini-thoracotomy was done through the 4th intercostal space. Soft-tissue retractor was placed to gain the access. Pericardium was opened anterior to the phrenic nerve. Tapes were passed around the SVC and IVC and heart was fibrillated. Right atrium was opened (Fig. 1b). It was found that there was a large mass assembled around a piece of plastic cannula extending from the right atrial appendage onto the tricuspid valve (Fig. 2a). The mass along with the plastic cannula was excised (Fig. 2b). Methodical examination of the right atrium was carried out. Tricuspid valve was inspected and made sure that all the leaflets were coapting well. This was also reconfirmed by no evidence of TR on intraoperative transesophageal echocardiogram (TEE) post-removal of the mass. Once satisfaction to our intracardiac inspection was achieved, the right atriotomy was closed in 2 layers, and cardiopulmonary bypass was weaned off successfully. Decannulation was

[☆] This is an open-access article distributed under the terms of the Creative Commons Attribution-NonCommercial-No Derivative Works License, which permits non-commercial use, distribution, and reproduction in any medium, provided the original author and source are credited.

^{*} Corresponding author. Tel.: +1 254 458 7651; fax: +1 254 724 7482.

E-mail address: manzoor.elahi@hotmail.com (M.M. Elahi).

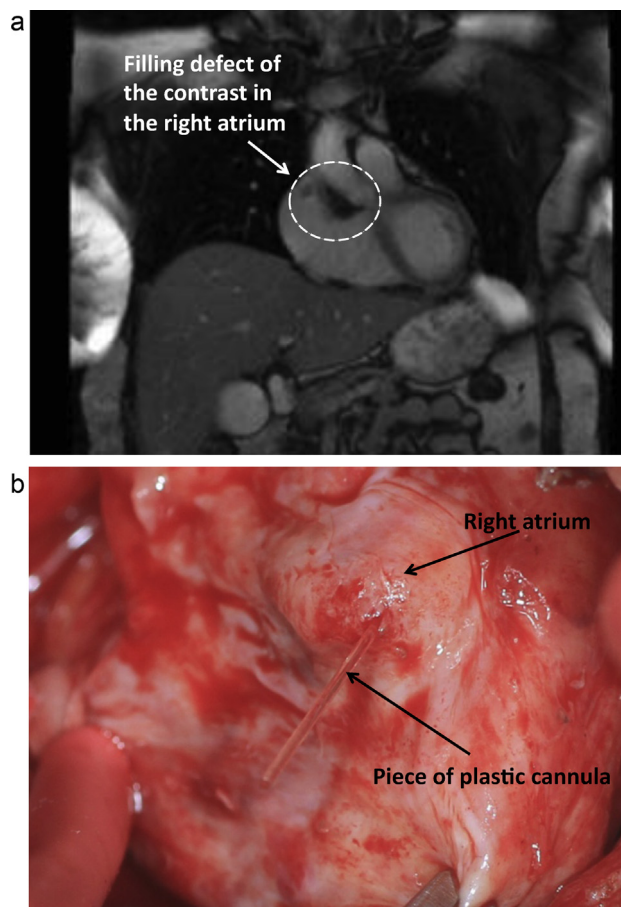


Fig. 1. (a) Mass in the right atrium demonstrated by the filling defect of the contrast suggesting abnormality of some sort in the right atrium. Given the short interval time frame of appearance and the enhancement characteristics, this mass likely represents intraluminal thrombus. (b) (Surgeon's view) The tip of the black arrow points to the right atrium with a mass protruding outward from the atrium. The mass was a piece of a subclavian vein plastic cannula.

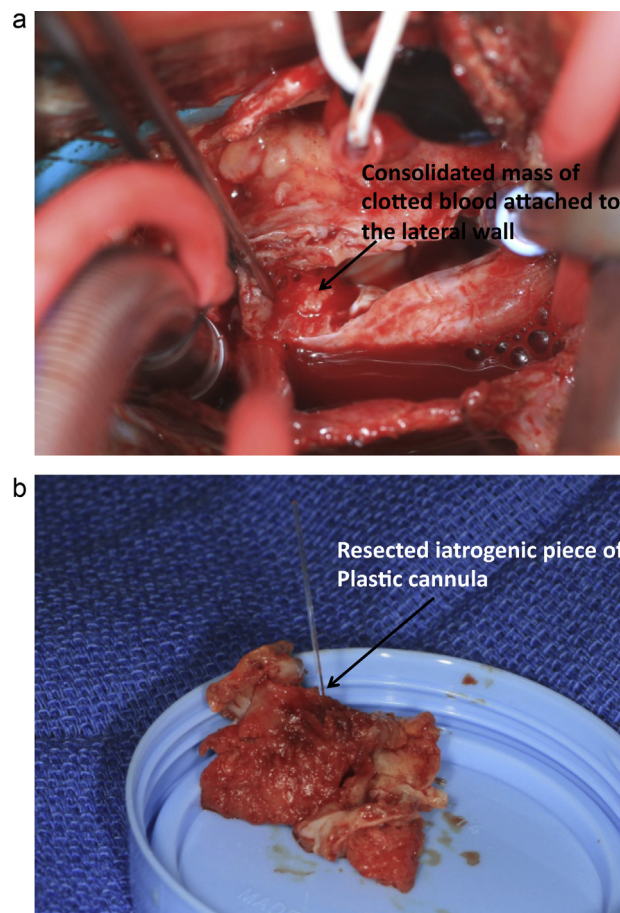


Fig. 2. (a) (Surgeon's view) Right atrium opened. The black arrow is pointing to a consolidated mass of clotted blood attached to the lateral wall. Pair of forceps are pointing towards the plastic tubing protruding from the mass. (b) Resected mass with a retained iatrogenic piece of plastic cannula.

undertaken, heparin was reversed with protamine and hemostasis was secured. 24-French Blake drain was placed in the pericardial cavity for drainage and the right anterior thoracotomy wound was closed in routine fashion. Patient had an uneventful recovery and discharged home within 3 days.

3. Discussion

There have been several case reports describing retained intracardiac foreign bodies especially in left sided chambers. However, right atrial foreign bodies are less widely encountered. We report a case of a young woman who presented to us with repeated episodes of debilitating stabbing chest pain. The differential diagnosis at the time was perplexed and ranged from recurrent polyserositis, familial Mediterranean fever, amyloidosis, idiopathic pericarditis and tuberculosis associated with polyserositis. Nevertheless, we found during the surgery that there was a retained iatrogenic piece of plastic cannula embedded in the inflamed right atrial mass causing the symptoms of the patient.

Earlier review conducted in 5000 patients who received intracardiac catheters inserted for treatment modalities suggested iatrogenic retention incidence of 0.07%.¹ Such retained foreign bodies in the heart could lead to number of complications, that may include thrombus formation, tricuspid valve insufficiency, neurological manifestations secondary to cardio-embolic stroke,

infections, and arrhythmias.^{2,4,5} In this regard, Actis Dato et al. evaluated fourteen cases of foreign bodies in the heart and provided some procedural guidelines about the management of foreign bodies in the heart.⁵ The authors suggested that if the patient is symptomatic, surgical removal of the foreign body is indicated; asymptomatic with associated risk of infection, embolization, or erosion, surgery is indicated; and if patient is asymptomatic without the associated symptoms, surgery is indicated depending on the nature and location of the foreign body within the heart.⁵ Our patient presentation was no exception to this list.

Several imaging techniques may well be helpful in detecting such abnormalities. These include new generation computer tomography scans, echocardiography, and MRI. In our case we relied on MRI yet the scans remained inconclusive in delineating between the mass or foreign body from the surrounding muscle tissues and/or organs.³

It is interesting to note that patients may remain asymptomatic for a period of time before constitutional signs and symptoms begin to appear as in our case.⁴ Tsutsui and coworkers in 2003 suggested the identification of chemotherapy and dialysis retained catheter fragments during routine chest X-rays, though the patients in their report remained primarily asymptomatic.⁴ The exact aetiology of such retained plastic cannula fragment in our patient is still not clear, however our patient did recall to have a past history of cardiac catheterization several months prior to the surgery.

4. Conclusion

Henceforth, in view of catheters being widely used and necessary for a variety of procedures and treatments in this current age and era, it is of prime importance for physicians and other medical staff to be aware of the proper insertion and removal of plastic cannulas whenever being used on a patient. It is of utmost importance that the removal of the plastic cannulas be confirmed by two different attending personnel, a nurse and by the attending physician. This will help prevent many complications. We emphasize that every department should be equipped with the proper protocols for managing catheter based vascular access.⁴ Our case is one, such examples. The patient presented in this report was very fortunate that the plastic cannula fragment did not immediately pierce the right atrial wall, which could have led to severe internal bleeding into the pericardial cavity and ultimately progressing to further complications.

Conflict of interest

None.

Funding

None.

Ethical approval

We have obtained written consent from the patient and that is available to be provided, should the Editor ask to see it.

Author contributions

Maqsood Elahi contributed in study design, case identification and writing. Charles Choi helped in study design, collection of data and searching the literature. Subbareddy Konda helped in case identification, refining the literature search and writing and others.

References

1. Santini F, Gatti G, Borghetti V, Oppido G, Mazzucco A. Routine left atrial catheterization for post-operative management of cardiac surgical patients: is the risk justified? *Eur J Cardiothorac Surg* 1999;**16**:218–21.
2. Hynes MS, Mesana TG, Burwash IG. Retained left atrial catheter: a case report and review of the literature. *J Am Soc Echocardiogr* 2005;**18**:1423.
3. Sabageh D, Odujoko OO, Komalafe AO. Right atrial myxoma as a possible cause of hemorrhagic stroke and sudden death. *Niger Med J* 2012;**53**:102–4.
4. Tsutsui JM, Hueb WA, Nascimento SA, Borges Leal SM, de Andrade JL, Mathias Jr W. Detection of retained surgical sponge by transthoracic and transesophageal echocardiography. *J Am Soc Echocardiogr* 2003;**16**:1191–3.
5. Actis Dato GM, Arslanian A, Di Marzio P, Filosso PL, Ruffini E. Posttraumatic and iatrogenic foreign bodies in the heart: report of fourteen cases and review of the literature. *J Thorac Cardiovas Surg* 2003;**126**:408–14.

Open Access

This article is published Open Access at scimedirect.com. It is distributed under the [IJSCR Supplemental terms and conditions](#), which permits unrestricted non commercial use, distribution, and reproduction in any medium, provided the original authors and source are credited.