



# ECPR successfully used in 5.5-hour cardiac arrest caused by peripartum cardiomyopathy: a case report and minireview

Fei Lin<sup>1#</sup>, Yong Cao<sup>2#</sup>, Minghai Xian<sup>1</sup>, Youkuan He<sup>1</sup>, Qingping Xia<sup>3</sup>, Li Deng<sup>1,4</sup>

<sup>1</sup>Department of Extracorporeal Life Support, The People's Hospital of Gaozhou, Gaozhou, China; <sup>2</sup>Department of Cardiovascular Surgery, The People's Hospital of Gaozhou, Gaozhou, China; <sup>3</sup>Department of Science and Education, The People's Hospital of Gaozhou, Gaozhou, China; <sup>4</sup>Department of Cardiovascular Surgery, The First Affiliated Hospital of Harbin Medical University, Harbin, China

**Contributions:** (I) Conception and design: L Deng; (II) Administrative support: None; (III) Provision of study materials or patients: Y Cao, Y He; (IV) Collection and assembly of data: Q Xia; (V) Data analysis and interpretation: F Lin, M Xian; (VI) Manuscript writing: All authors; (VII) Final approval of manuscript: All authors.

<sup>#</sup>These authors contributed equally to this work.

**Correspondence to:** Li Deng, PhD. Department of Cardiovascular Surgery, The First Affiliated Hospital of Harbin Medical University, 23 Youzheng St., Harbin 150001, China; Department of Extracorporeal Life Support, The People's Hospital of Gaozhou, No. 89 Xiguan Road, Gaozhou 525200, China. Email: dengli\_198118@163.com; Qingping Xia, MD. Department of Science and Education, The People's Hospital of Gaozhou, No. 89 Xiguan Road, Gaozhou 525200, China. Email: 770544866@qq.com.

**Background:** Cardiac arrest (CA) caused by peripartum cardiomyopathy (PPCM) is a catastrophic disease that can lead to a high mortality rate in young women. Cardiopulmonary resuscitation (CPR) is the initial first aid measure to be taken and unfortunately, does not always lead to the restoration of spontaneous circulation (ROSC). We shared a rare successful case of extracorporeal cardiopulmonary oxygenation-assisted resuscitation (ECPR) in a patient with CA for up to 5.5 hours due to PPCM.

**Case Description:** A previously healthy 31-year-old woman at 34 weeks of gestation was admitted to the emergency department with fever and arrhythmia. Two days later, the patient had postpartum CA. She underwent CPR for up to 5 hours before receiving V-A extracorporeal membrane oxygenation (ECMO) support and eventually regained spontaneous circulation after half an hour. Based on the clinical manifestations, the patient was diagnosed with PPCM and received treatment. The patient was successfully removed from ECMO after 9 days. The patient experienced ECMO-related complications, including thrombocytopenia and intracranial hemorrhage (ICH). Although treatment was difficult, the patient was discharged after 2 months without any neurological complications. We followed up for 1 year and the patient was able to work normally as a teacher. In our mini-review, we found that the success rate of ECPR in perinatal CA was high, and ECPR is worthy of promotion and application.

**Conclusions:** As an advanced life support method, ECPR can save patients undergoing postpartum CA. However, effective CPR and avoidance of ICH are necessary for the recovery of brain function.

**Keywords:** Cardiopulmonary resuscitation (CPR); extracorporeal membrane oxygenation; intracranial hemorrhage (ICH); peripartum cardiomyopathy (PPCM); case report

Submitted Dec 08, 2022. Accepted for publication Jan 11, 2023. Published online Jan 31, 2023.

doi: 10.21037/atm-22-6468

View this article at: <https://dx.doi.org/10.21037/atm-22-6468>

## Introduction

Peripartum cardiomyopathy (PPCM) is a disease that occurs naturally during pregnancy, with the majority of cases occurring within 3 months of delivery and 6 months

after delivery. PPCM is characterized by cardiomyopathy and congestive heart failure, and symptoms include chest pain, dyspnea, nocturnal paroxysmal dyspnea, and cough (1). These symptoms may be confused with normal symptoms

in the third trimester of pregnancy, thereby delaying the diagnosis of PPCM (2).

Cardiac arrest (CA) caused by PPCM is a catastrophic disease that can lead to a high mortality rate in young women and a problem that needs to be addressed urgently (3). When CA occurs, rapid intervention and high-quality cardiopulmonary resuscitation (CPR) are the basic rescue measures. Sometimes, however, CPR is not effective. Extracorporeal cardiopulmonary oxygenation-assisted resuscitation (ECPR), an advanced artificial cardiopulmonary support technology, may be considered when conventional CPR efforts fail, as written in guidelines. Although a few cases of PPCM successfully treated with extracorporeal membrane oxygenation (ECMO) have been reported, we are not aware of any cases published in the literature of ECPR successfully used in a 5.5-hour CA caused by PPCM. In this paper, we present a very rare, successful ECPR case involving a 5.5-hour CA caused by perinatal cardiomyopathy. We present the following article in accordance with the CARE reporting checklist (available at <https://atm.amegroups.com/article/view/10.21037/atm-22-6468/rc>).

## Case presentation

A previously healthy 31-year-old pregnant woman was admitted at 34 weeks as an emergency at a local hospital due to fever and sinus tachycardia on September 25, 2021. Two days later, the patient developed shortness of breath,

cough with sputum, and hypoxemia (oxygen saturation was 88.0%). The patient's oxygenation did not improve after oxygen therapy and instead developed symptoms similar to heart failure, including pink foaming sputum and cyanosis. Blood pressure (BP) remained within the normal range during this period. However, the patient underwent emergency cesarean section and a healthy fetus was delivered due to slowed fetal heart rate. Subsequently, the patient was transferred to the intensive care unit (ICU) for further treatment due to the exacerbation of heart failure. The ultrasound showed left heart enlargement, left ventricular systolic insufficiency, moderate mitral valve insufficiency, and an ejection fraction (EF) of 43% but showed no right heart dilation or pulmonary artery blood clots. After excluding myocarditis, pulmonary embolism, eclampsia, aortic dissection, and other diseases, the patient was diagnosed with fulminant PPCM based on ultrasound, clinical experience, and the 2019 European Society of Cardiology (ESC) guidelines on PPCM (4). In accordance with the 2018 ESC guidelines for the management of cardiovascular diseases during pregnancy, essential therapies for patients with acute PPCM are based on the "BOARD" method (bromocriptine, oral heart failure therapies, anticoagulants, vasorelaxant agents, and diuretics) (5,6).

However, 6 hours later, the patient's condition deteriorated and she suffered CA. External cardiac compression was given immediately. The patient received CPR for 5 hours but did not regain spontaneous circulation until the ECMO team arrived.

Access was established for venoarterial ECMO with a right arteriotomy femoral venous cannula (19 Fr Medtronic) and femoral arterial cannula (17 Fr Medtronic), and a 7 Fr cannula was inserted to provide perfusion distally within the femoral artery. With the establishment of flow at 3.5 L/min in the extracorporeal circuit, the patient resumed spontaneous circulation after 30 minutes.

At this time, the patient's BP was 79/77 mmHg, lactate >15 mmol/L, and anuria had occurred. Venoarterial ECMO continued supported by middle-dose infusions of dobutamine ( $8 \mu\text{g}\cdot\text{kg}^{-1}\cdot\text{min}^{-1}$ ) and milrinone ( $1 \mu\text{g}\cdot\text{kg}^{-1}\cdot\text{min}^{-1}$ ).

Ultrasound showed only 16% EF with heavy left ventricular posterior load and limited aortic valve opening. Therefore, an intra-aortic balloon pump (IABP) was placed to reduce left ventricular afterload and improve myocardial perfusion. Continuous renal replacement therapy (CRRT) was connected to the ECMO circuit in order to maintain a constant internal environment and protect kidney function. The activated clotting time (ACT) was between 160 and

### Highlight box

#### Key findings

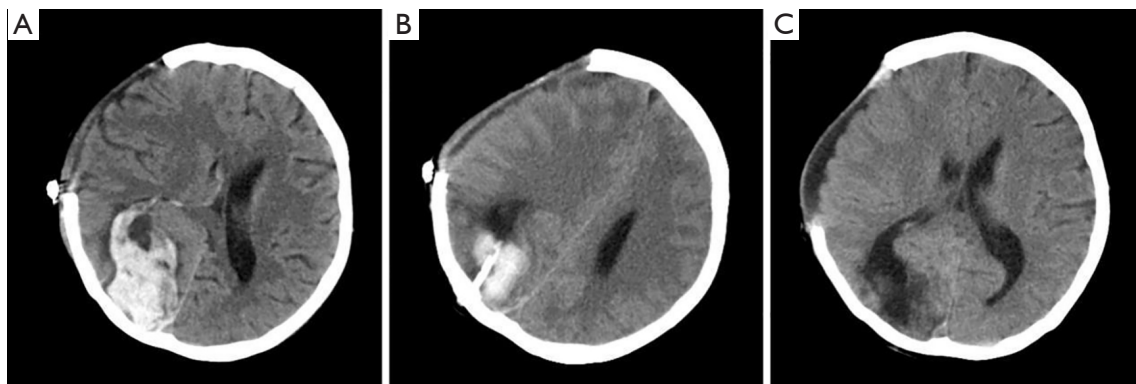
- Extracorporeal cardiopulmonary oxygenation-assisted resuscitation (ECPR) was successfully used in a 5.5-hour cardiac arrest caused by perinatal cardiomyopathy. This case highlights the reasons for the success of ECPR and how to manage the complications of intracranial hemorrhage.

#### What is known and what is new?

- High-quality cardiopulmonary resuscitation (CPR) is very important for brain protection, and mechanical CPR devices are very useful for improving the quality of CPR.
- Extracorporeal membrane oxygenation (ECMO)-related thrombocytopenia can cause intracranial hemorrhage. This dangerous complication needs more attention.

#### What is the implication, and what should change now?

- We need a clear understanding of the relationship between cardiac arrest and brain injury. In addition, standard procedures for the operation and management of CPR and ECMO are needed.



**Figure 1** CT images of the patient with recurrent intracerebral hemorrhage. (A) First cerebral hemorrhage. Cranial decompression was conducted, but intracranial hematoma removal was not performed due to technical limitations at the local hospital. Decompression surgery failed to relieve the patient's symptoms, and the patient was transferred to our hospital for further intracranial hematoma removal. (B) Recurrent intracerebral hemorrhage. CT showed that 2 days after surgery, the patient developed recurrent cerebral hemorrhage. (C) CT showed good absorption of the hematoma after reoperation. CT, computed tomography.

200 seconds, and neurological assessments were performed every day.

After a few days of treatment, the patient's cardiac function gradually improved, with EF value restored from 16% to 35%, vital signs stable, and lactic acid reduced to 3 mmol/L. However, the patient developed bleeding complications (nasal cavity, gastrointestinal, and incision) due to thrombocytopenia, and treatment with anticoagulant reduction and limiting allogeneic platelet (PLT) infusion did not result in a return to normal range, which forced us to eventually stop ECMO assistance on day 9.

Although we successfully removed the ECMO, we found that the patient's pupils began to differ in size. An urgent cranial computed tomography (CT) scan showed an intracranial hemorrhage (ICH) in the patient's right frontal lobe, occipitotemporal area, and temporal lobe (*Figure 1*). Without hesitation, cranial decompression was conducted, but intracranial hematoma removal was not performed due to technical limitations at the local hospital. Decompression surgery failed to relieve the patient's symptoms, and the patient was transferred to our hospital (The People's Hospital of Gaozhou) for further intracranial hematoma removal. The patient gradually became conscious after surgery.

However, 4 days later, the patient fell into a coma due to recurrent cerebral hemorrhage and had to undergo surgery again (*Figure 1*). Fortunately, the patient recovered from the surgery without further cerebral hemorrhage.

After more than 40 days of treatment, the patient recovered and was discharged without any sequelae and her

EF had restored to 50%. The patient was followed up for 1 year. She had a good recovery without any complications and returned to work as a teacher (*Figure 2*).

All procedures performed in this study were in accordance with the ethical standards of the institutional and/or national research committee(s) and with the Declaration of Helsinki (as revised in 2013). Written informed consent was obtained from the patient for publication of this case report and accompanying images. A copy of the written consent is available for review by the editorial office of this journal.

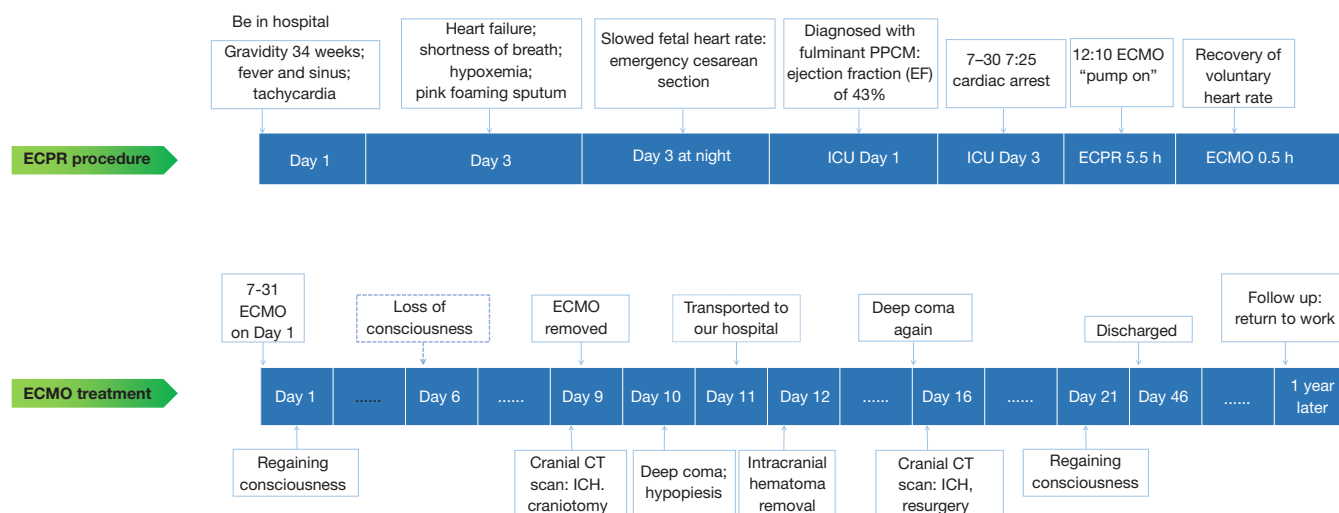
## Discussion

### *Record identification and data extraction*

A search of the PubMed database was conducted using the keywords "pregnant woman," "cardiogenic shock," "ECMO," "peripartum cardiomyopathy," "extracorporeal cardiopulmonary resuscitation," "cardiac arrest," and "postpartum," and 9 articles were retrieved. All of the patients underwent ECPR during pregnancy or in the perinatal period. Of the patients, 8 underwent ECPR at hospital, and 1 case underwent ECPR outside hospital.

### *General information and outcomes*

The average age of patients was  $27.25 \pm 5.19$  years (range, 19–36 years). Gestational age ranged from 18 to 39 weeks. All of the patients received ECMO support due to failed



**Figure 2** A timeline figure of the treatment process. ECPR, extracorporeal cardiopulmonary resuscitation; ECMO, extracorporeal membrane oxygenation; ICH, intracranial hemorrhage; PPCM, peripartum cardiomyopathy; CT, computed tomography; ICU, intensive care unit.

CPR treatment after CA. The mean interval time between CPR and ECMO was  $69.71 \pm 30.15$  minutes (range, 30–120 minutes), and the mean ECMO duration time was  $4.79 \pm 2.03$  days. Causes of CA included pulmonary embolism, amniotic fluid embolism, spontaneous coronary artery dissection, and PPCM, among others. All patients were successfully weaned off ECMO support. Eight patients were discharged, and 1 patient died of multiple organ dysfunction syndrome (MODS). Complications included Harlequin syndrome, but no other neurological complications occurred. Baseline data of the 9 cases are shown in *Table 1*.

By reviewing the literature, we found that ECPR can help patients with perinatal CA caused by different reasons and the success rate is very high. Pulmonary embolism (amniotic fluid embolism) was the most common cause, followed by PPCM, and massive hemorrhage and dissection were the least common causes. The longest CA case that has been retrieved is 2 hours in our mini-review. It was a miracle that CA up to 5.5 hours were successfully treated through ECPR in our case. We analyzed the possible factors that are beneficial to the survival of patients, which provides a good experience for clinicians to treat such patients.

### *Reasons for the success of ECPR*

According to registration data of the Extracorporeal

Life Support Organization, the overall survival rate of adult ECPR is only about 30%. A previous study had confirmed that the survival rate of ECPR is less than 10% if the initiation low-flow time is longer than 90 minutes (16). Therefore, it is recommended to start ECPR within 10 minutes. More than 60 minutes of ECPR is considered the “limit”, and patients rarely have a good clinical outcome beyond this time (17). In our literature review, the longest duration of CA was 2 hours, whereas our case regained spontaneous circulation after 5.5 hours, and although she experienced severe neurological complications, she ultimately survived. Such a case has never been reported, and we wanted to know the factors for survival, other than luck.

Generally, brain tissue has poor tolerance to hypoxia. When cerebral blood supply is interrupted, brain cells will stop electrical activity in 2 minutes, and irreversible damage will occur in brain tissue after 5 minutes. Thus, when CA occurs, CPR should be taken immediately to reduce the ischemic time of the brain (18).

In CA, high-quality CPR is a key determinant of patient survival, especially in cerebral perfusion and cerebral protection. International guidelines highlight the importance of high-quality chest compressions, which are defined as compressions at a depth of 5–6 cm and a rate of 100–120 per minute, allowing full chest recoil between compressions and minimization of interruptions (19).

**Table 1** Baseline data of 9 cases of CA with ECPR

No. Study	Year/Journal	Age, year	GP	GA, week	Cause	ECPR	CPR to ECMO (min)	ECMO mode	ECMO duration, day	Length of hospital stay, day	Neurological complications	Weaned off	Discharged	When event happened
1	McKechnie 2001/ <i>Obstetrics &amp; Gynecology</i>	NA	NA	36	Spontaneous coronary artery dissection	Y	NA	N	3	14	NA	Y	Y	During emergent cesarean delivery
2	Reiss (8) 2006/ <i>Obstetrics &amp; Gynecology</i>	36	G2P1	37	Postpartum hemorrhage	Y	120	N	6	NA	N	Y	Y	Postpartum
3	Smith (9) 2009/ <i>International Journal of Obstetric Anesthesia</i>	19	G2P0	38	Peripartum cardiomyopathy	Y	45	N	3	19	N	Y	Y	24 hours after natural delivery
4	Fernandes 2015/ <i>Perfusion</i>	30	NA	37	Pulmonary embolism	Y	84	Y	5	46	N	Y	Y	During emergent cesarean delivery
5	McDonald 2017/ <i>International Journal of Obstetric Anesthesia</i>	22	NA	36	Pulmonary embolism	Y	100	N	5	NA	Right foot drop	Y	Y	During emergent cesarean delivery
6	Goto (12) 2017/ <i>Acute Medicine &amp; Surgery</i>	29	G1P0	36	Unexplained ventricular fibrillation (out of hospital)	Y	49	N	9	NA	N	Y	Y	During pregnancy
7	Seong (13) 2018/ <i>Journal of Thoracic Disease</i>	32	NA	39	Amniotic fluid embolism	Y	60	N	2	NA	N	Y	Y	24 hours after natural delivery
8	Djordjevic 2020/ <i>Journal of Cardiac Surgery</i>	25	G1P0	20	Peripartum cardiomyopathy	Y	NA	N	4, 3, 3	NA	NA	Y	N	During pregnancy
9	Creel-Bulos (15) 2020/ <i>Critical Care Explorations</i>	25	NA	18	Amniotic fluid embolism in early pregnancy	Y	30	Y	6	19	N	Y	Y	During pregnancy

Case 8 underwent ECMO support 3 times (for 4 days, 3 days, and 3 days), CA, cardiac arrest; ECPR, extracorporeal cardiopulmonary oxygenation-assisted resuscitation; GP, gestation and parturition; GA, gestational age; CPR, cardiopulmonary resuscitation; ECMO, extracorporeal membrane oxygenation; NA, not mentioned in the literature; N, no; Y, yes.



The most important clinical significance of standard CPR procedure is to maintain uninterrupted cerebral blood flow to promote the recovery of brain function. This is a key factor in the absence of neurological sequelae in the patient.

However, delivery of effective chest compressions is often inconsistent, subject to fatigue, and practically challenging (20). Mechanical CPR devices provide an automated way to deliver high-quality CPR (21).

Our patient had CA in the ICU, which was immediately recognized, and she was resuscitated without prolonged ischemic hypoxia to the brain. After 10 minutes of CPR, the physician realized that it might be difficult to restore spontaneous circulation, and he contacted the ECMO team and activated the mechanical CPR device simultaneously. This case demonstrated that in situations in which high-quality manual chest compressions cannot be performed safely, the use of mechanical devices may be a reasonable clinical approach. More importantly, the patient had no significant interruption during CPR. Systolic blood pressure was maintained at about 60–80 mmHg, there was no obvious skin cyanosis, and pupillary reflex had not disappeared.

It is worth noting that this patient had a CA in the ICU, which has the best rescue conditions and facilities, and is another important reason for the survival of the patient. If the CA occurred outside the hospital, it would be difficult to ensure that the patient received continuous effective CPR or effective support of mechanical CPR equipment. If transport is involved, a portable mechanical CPR device should be used as it provides continuous and effective cardiac compression. In addition, the patient was very young, there was no concomitant underlying disease, the patient was not obese, and the CPR resuscitation process was of high quality, all factors contributing to the success.

It was very commendable that the doctor in charge predicted that the ECMO team would not arrive immediately, and he did not abandon treatment. In addition to CPR, the doctor put an ice cap on the patient for brain protection, which may have also helped the patient to reduce cerebral oxygen consumption. We adopted a management strategy of mild hypothermia cerebral protection during ECMO support (rectal temperature was 34–35 °C for 3 days). According to the guidelines, patients who regain spontaneous circulation but are unconscious should be treated with mild hypothermia at 32–34 °C for 12–24 hours (22–24). At the same time, with the support of

vasoactive drugs, hemodynamic stability was maintained for effective organ perfusion pressure.

### *How can ECMO ICH complications be recognized and prevented*

ICH is a serious complication of ECMO and has a high mortality rate. Major risk factors include thrombocytopenia, ECMO duration, anticoagulation, ECPR, sepsis, and renal failure, among others (25). A study had shown that thrombocytopenia is an independent risk factor for ICH (20). Our patient was very lucky. When we found that the patient had symptomatic intracerebral hemorrhage, the patient's heart function had recovered somewhat. Although the patient received PLT infusion, the PLT value of the patient never reached more than  $50 \times 10^9/L$  because there was not enough PLT to use. We removed ECMO after discussion because the patient had a large intracerebral hemorrhage that required surgery. If the patient could not be removed from ECMO due to poor cardiac function, then we would have had to discontinue anticoagulation. In this situation, if the brain hemorrhage cannot be treated, it is difficult for the patient to survive.

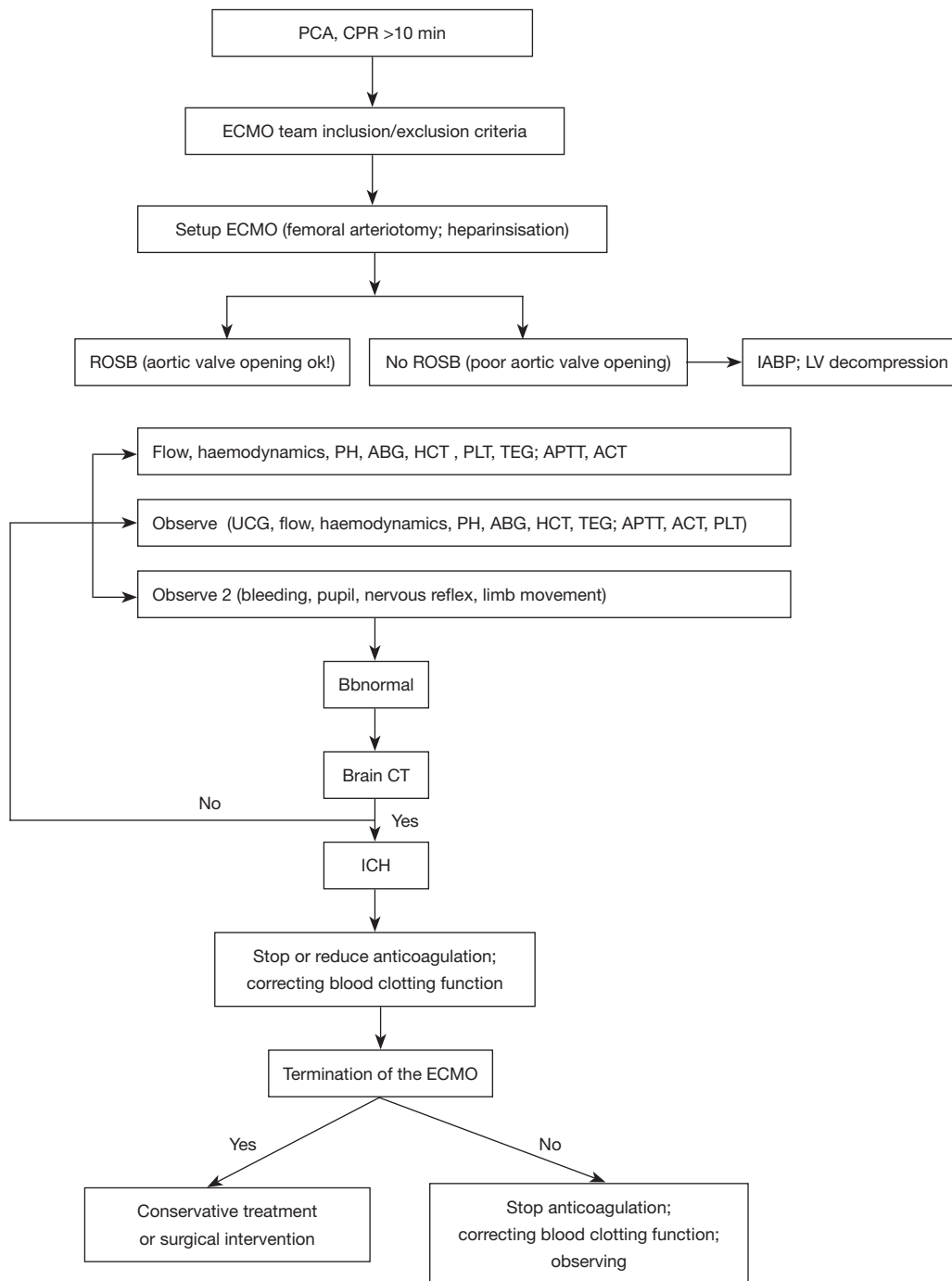
There were no cases of ICH in the literature review that we summarized, but our patient had 2 episodes of cerebral hemorrhage, and we hope that our experience can help ICU physicians to better deal with this special situation. We developed a flow chart to help physicians identify and manage ICH (*Figure 3*).

### *Warning*

Because there is no local ECMO team, local doctors spend a lot of time looking for ECMO support, resulting in the patient not receiving timely ECMO support. This suggests that ICU departments should have a professional ECMO team or can be supported by a rapid regional ECMO collaboration network, which is very important for the treatment of critically ill patients.

### **Conclusions**

ECPR is an effective advanced extracorporeal life support technique that can be used to treat critically ill perinatal and CA patients. Mechanical CPR devices could deliver high-quality CPR. ECMO-related complications such as



**Figure 3** A flow chart to help physicians identify and manage ICH. PCA, peripartum cardiac arrest; CPR, cardiopulmonary resuscitation; ECMO, extracorporeal membrane oxygenation; ROSB, return of spontaneous beating; IABP, intra-aortic ballon pump; ABG, arterial blood gas; HCT, hematocrit; PLT, platelets; TEG, thrombelastography; APTT, activated partial thromboplastin time; ACT, activated clotting time; LV, left ventricle; UCG, ultrasonic cardiography; CT, computerized tomography; ICH, intracranial hemorrhage.

thrombocytopenia and ICH must be treated with caution.

## Acknowledgments

*Funding:* This study was supported by the Foundation of Science and Technology Program of Maoming City (No. 2021184), Precision and Comfortable Medical Clinical Research of Guangdong Province Hospital Association (No. 2020-16), and Medical Science and Technology Innovation in Maoming city (Nos. 2021KJZZXZYX008, 2022S003).

## Footnote

*Reporting Checklist:* The authors have completed the CARE reporting checklist. Available at <https://atm.amegroups.com/article/view/10.21037/atm-22-6468/rc>

*Conflicts of Interest:* All authors have completed the ICMJE uniform disclosure form (available at <https://atm.amegroups.com/article/view/10.21037/atm-22-6468/coif>). The authors have no conflicts of interest to declare.

*Ethical Statement:* The authors are accountable for all aspects of the work in ensuring that questions related to the accuracy or integrity of any part of the work are appropriately investigated and resolved. All procedures performed in this study were in accordance with the ethical standards of the institutional and/or national research committee(s) and with the Declaration of Helsinki (as revised in 2013). Written informed consent was obtained from the patient for publication of this case report and accompanying images. A copy of the written consent is available for review by the editorial office of this journal.

*Open Access Statement:* This is an Open Access article distributed in accordance with the Creative Commons Attribution-NonCommercial-NoDerivs 4.0 International License (CC BY-NC-ND 4.0), which permits the non-commercial replication and distribution of the article with the strict proviso that no changes or edits are made and the original work is properly cited (including links to both the formal publication through the relevant DOI and the license). See: <https://creativecommons.org/licenses/by-nc-nd/4.0/>.

## References

- Shrikhande L, Shrikhande A, Shrikhande B. Peripartum Cardiomyopathy. J Obstet Gynaecol India 2022;72:377-81.
- Honigberg MC, Givertz MM. Peripartum cardiomyopathy. BMJ 2019;364:k5287.
- Kikuchi J, Deering S. Cardiac arrest in pregnancy. Semin Perinatol 2018;42:33-8.
- Bauersachs J, König T, van der Meer P, et al. Pathophysiology, diagnosis and management of peripartum cardiomyopathy: a position statement from the Heart Failure Association of the European Society of Cardiology Study Group on peripartum cardiomyopathy. Eur J Heart Fail 2019;21:827-43.
- Regitz-Zagrosek V, Roos-Hesselink JW, Bauersachs J, et al. 2018 ESC Guidelines for the management of cardiovascular diseases during pregnancy. Eur Heart J 2018;39:3165-241.
- Hilfiker-Kleiner D, Haghikia A, Berliner D, et al. Bromocriptine for the treatment of peripartum cardiomyopathy: a multicentre randomized study. Eur Heart J 2017;38:2671-9.
- McKechnie RS, Patel D, Eitzman DT, et al. Spontaneous coronary artery dissection in a pregnant woman. Obstet Gynecol 2001;98:899-902.
- Reiss A, Lowenstein L, Solt I, et al. Recurrent ascites due to oral contraceptives and pregnancy. Obstet Gynecol 2006;107:499-501.
- Smith IJ, Gillham MJ. Fulminant peripartum cardiomyopathy rescue with extracorporeal membranous oxygenation. Int J Obstet Anesth 2009;18:186-8.
- Fernandes P, Allen P, Valdis M, et al. Successful use of extracorporeal membrane oxygenation for pulmonary embolism, prolonged cardiac arrest, post-partum: a cannulation dilemma. Perfusion 2015;30:106-10.
- McDonald C, Laurie J, Janssens S, et al. Successful provision of inter-hospital extracorporeal cardiopulmonary resuscitation for acute post-partum pulmonary embolism. Int J Obstet Anesth 2017;30:65-8.
- Goto M, Watanabe H, Ogita K, et al. Perimortem cesarean delivery and subsequent emergency hysterectomy: new strategy for maternal cardiac arrest. Acute Med Surg 2017;4:467-71.
- Seong GM, Kim SW, Kang HS, et al. Successful extracorporeal cardiopulmonary resuscitation in a postpartum patient with amniotic fluid embolism. J Thorac Dis 2018;10:E189-93.
- Djordjevic I, Rahmanian P, Zeriouh M, et al. Treatment of cardiogenic shock in peripartum cardiomyopathy: Case series from a tertiary ECMO center. J Card Surg 2020;35:254-7.



15. Creel-Bulos C, Hassani B, Stentz MJ, et al. Extracorporeal Membrane Oxygenation for Amniotic Fluid Embolism-Induced Cardiac Arrest in the First Trimester of Pregnancy: A Case Report. *Crit Care Explor* 2020;2:e0162.
  16. Abrams D, MacLaren G, Lorusso R, et al. Extracorporeal cardiopulmonary resuscitation in adults: evidence and implications. *Intensive Care Med* 2022;48:1-15.
  17. Guglin M, Zucker MJ, Bazan VM, et al. Venoarterial ECMO for Adults: JACC Scientific Expert Panel. *J Am Coll Cardiol* 2019;73:698-716.
  18. Andersen LW, Holmberg MJ, Berg KM, et al. In-Hospital Cardiac Arrest: A Review. *JAMA* 2019;321:1200-10.
  19. Panchal AR, Berg KM, Hirsch KG, et al. 2019 American Heart Association Focused Update on Advanced Cardiovascular Life Support: Use of Advanced Airways, Vasopressors, and Extracorporeal Cardiopulmonary Resuscitation During Cardiac Arrest: An Update to the American Heart Association Guidelines for Cardiopulmonary Resuscitation and Emergency Cardiovascular Care. *Circulation* 2019;140:e881-94.
  20. Poole K, Couper K, Smyth MA, et al. Mechanical CPR: Who? When? How? *Crit Care* 2018;22:140.
  21. Şan İ, Bekgöz B, Ergin M, et al. Manual cardiopulmonary resuscitation versus mechanical cardiopulmonary resuscitation: Which one is more effective during ambulance transport. *Turk J Emerg Med* 2021;21:69-74.
  22. Perkins GD, Jacobs IG, Nadkarni VM, et al. Cardiac arrest and cardiopulmonary resuscitation outcome reports: update of the Utstein Resuscitation Registry Templates for Out-of-Hospital Cardiac Arrest: a statement for healthcare professionals from a task force of the International Liaison Committee on Resuscitation (American Heart Association, European Resuscitation Council, Australian and New Zealand Council on Resuscitation, Heart and Stroke Foundation of Canada, InterAmerican Heart Foundation, Resuscitation Council of Southern Africa, Resuscitation Council of Asia); and the American Heart Association Emergency Cardiovascular Care Committee and the Council on Cardiopulmonary, Critical Care, Perioperative and Resuscitation. *Circulation* 2015;132:1286-300.
  23. 2005 American Heart Association (AHA) guidelines for cardiopulmonary resuscitation (CPR) and emergency cardiovascular care (ECC) of pediatric and neonatal patients: pediatric basic life support. *Pediatrics* 2006;117:e989-1004.
  24. Nolan JP, Neumar RW, Adrie C, et al. Post-cardiac arrest syndrome: epidemiology, pathophysiology, treatment, and prognostication: a scientific statement from the International Liaison Committee on Resuscitation; the American Heart Association Emergency Cardiovascular Care Committee; the Council on Cardiovascular Surgery and Anesthesia; the Council on Cardiopulmonary, Perioperative, and Critical Care; the Council on Clinical Cardiology; the Council on Stroke (Part II). *Int Emerg Nurs* 2010;18:8-28.
  25. Cavayas YA, Del Sorbo L, Fan E. Intracranial hemorrhage in adults on ECMO. *Perfusion* 2018;33:42-50.
- (English Language Editor: A. Muijlwijk)

**Cite this article as:** Lin F, Cao Y, Xian M, He Y, Xia Q, Deng L. ECPR successfully used in 5.5-hour cardiac arrest caused by peripartum cardiomyopathy: a case report and minireview. *Ann Transl Med* 2023;11(2):136. doi: 10.21037/atm-22-6468