

Radiographic Risk Factors of Reoperation Following Minimally Invasive Decompression for Lumbar Canal Stenosis Associated With Degenerative Scoliosis and Spondylolisthesis

Minori Kato, MD, PhD¹, Takashi Namikawa, MD, PhD¹, Akira Matsumura, MD, PhD¹, Sadahiko Konishi, MD, PhD², and Hiroaki Nakamura, MD, PhD³

Global Spine Journal
2017, Vol. 7(6) 498-505
© The Author(s) 2017
Reprints and permission:
sagepub.com/journalsPermissions.nav
DOI: 10.1177/2192568217699192
journals.sagepub.com/home/gsj


Abstract

Study Design: Prospective cohort study.

Objective: Microsurgical bilateral decompression via a unilateral approach (MBDU), a minimally invasive surgical (MIS) decompression method, has been performed for numerous degenerative lumbar diseases, including degenerative lumbar scoliosis (DLS) or degenerative spondylolisthesis (DS), at our institution. In this study, we evaluated the appropriateness of MBDU for DLS or DS patients.

Methods: A total of 207 patients treated by MBDU were included (88 women and 119 men; mean age, 70 [40-86] years). Thirty-seven cases were diagnosed as DLS (group A), 51 as DS (group B), and 119 as lumbar canal stenosis (group C). Patient clinical status assessed by JOA score was evaluated preoperatively and 2 years postoperatively. We evaluated the prevalence of cases that required reoperation among the groups and the radiographic risk factors related to reoperation.

Results: There was no significant difference in recovery ratios of JOA scores among the groups. Reoperation after MBDU was needed in 13 cases (6.3%); the revision rate did not significantly differ among the groups. Reoperation was associated with poor clinical status, low visual analog scale score for low back pain, and low SF-36 mental component summary score. Reoperation was significantly associated with preoperative scoliotic disc wedging with Cobb's angle $\geq 3^\circ$ in L4-5 (odds ratio = 9.88) and lateral listhesis (odds ratio = 5.22 [total], 12.9 [L4-5]).

Conclusions: When we are careful to indicate decompression for patients with these risk factors related to reoperation, MIS decompression alone can successfully improve DLS patients with a Cobb's angle of $\leq 20^\circ$ or DS patients.

Keywords

degenerative lumbar scoliosis, degenerative spondylolisthesis, lateral listhesis, lumbar spine, minimally invasive surgery, health-related quality of life

Introduction

Degenerative lumbar scoliosis (DLS) represents a challenge for spine surgeons owing to the high complications rates of correction and fusion surgery. Therefore, it is reasonable to choose decompression alone when the primary DLS symptom is neurogenic claudication due to spinal canal stenosis. However, the surgical treatment of these conditions remains controversial.¹⁻¹³

Various minimally invasive surgical (MIS) decompressions involving the use of microscopes and endoscopes have been developed to treat degenerative lumbar spine disease.

These techniques focus on the preservation of posterior elements such as the paraspinal muscles, supraspinatus and

¹ Osaka City General Hospital, Osaka, Japan

² Osaka General Hospital of West Japan Railway Company, Osaka, Japan

³ Osaka City University, Osaka, Japan

Corresponding Author:

Minori Kato, Department of Orthopaedic Surgery, Osaka City General Hospital, 2-13-22, Miyakojimahondori, Miyakojima-ku, Osaka, Japan.
Email: minorikato@med.osaka-cu.ac.jp



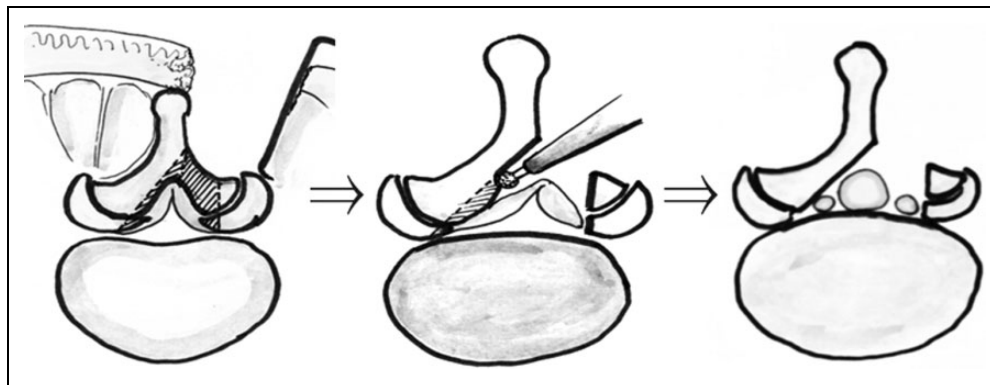


Figure 1. Schema showing our modified microsurgical bilateral decompression via a unilateral approach (MBDU) method.

intraspinous ligaments, and intervertebral joints, for which favorable clinical outcomes have been reported in lumbar canal stenosis (LCS) patients.^{2,6,7,8,10,11,14,15} Because impairment of scoliosis or instability after decompression can be minimized by posterior element preservation, MIS decompression indications have expanded to lumbar disease, including DLS or degenerative lumbar spondylolisthesis (DS). However, no consensus has yet been reached regarding these indications.

Microsurgical bilateral decompression via a unilateral approach (MBDU) has been performed for numerous degenerative lumbar diseases, including DLS or DS, at our institution.^{10,14} The MIS decompression method was previously reported by McCulloch and Young for complete decompression on the contralateral side to treat degenerative lumbar spine disease (Figure 1).¹⁶ Although we achieved satisfactory results in several patients, we experienced some unfavorable postoperative outcomes that required revision postoperatively because of degenerative changes in the decompressed disc. Therefore, we examined the prevalence of patients requiring reoperation after MBDU, their clinical characteristics, and radiographic risk factors related to reoperation. This study evaluated the appropriateness of MBDU for lumbar disease, particularly focusing on the indication of MIS decompression alone for DLS or DS.

Methods

This study protocol was approved by the Institutional Review Board of Osaka City General Hospital. Written informed consent was obtained from the patients for the publication of current research and any accompanying images.

This was a prospective cohort study of 255 consecutive patients treated at a single institution from 2007 to 2011 who received surgical treatment (MBDU) for degenerative lumbar disease. The follow-up duration was 24.2 months (range = 24-26). Clinical indications for MBDU were leg pain and/or leg numbness inducing intermittent claudication (rather than back pain), which were mainly derived from canal stenosis. The radiological indications were lumbar spinal stenosis, DLS with a Cobb's angle $\geq 10^\circ$ or $\leq 20^\circ$, and DS with Meyerding grade

≤ 1 and posterior opening $\leq 5^\circ$ during anterior flexion of the affected intervertebral level. Patients were divided into 3 groups according to their diagnosis: DLS (group A), DS (group B), or LCS (group C). Clinical outcomes were evaluated using the Japanese Orthopaedic Association (JOA) score, and the recovery was calculated using Hirabayashi's method. A patient-oriented evaluation of the health-related quality of life (HRQOL) scale was assessed using the visual analog scale (VAS) for low back pain, leg pain, and leg numbness (VAS = 0-100), and Short Form-36 (SF-36). On SF-36, the Physical Component Summary (PCS), Mental Component Summary (MCS), and Physical Functioning Subscale (PF) were checked.¹⁷ Slippage ratio was measured from lateral radiographs. The scoliosis angle was measured as the Cobb's angle of L1-5 from anteroposterior radiographs in the supine position. The clinical status and radiographic data were evaluated preoperatively and 2 years postoperatively. We compared the clinical outcomes and prevalence of cases that required reoperation among the groups. Additionally, we evaluated materials according to whether operation was required or not, and allocated cases into revision cases (group R) or nonrevision cases (group NR). We compared the clinical characteristics of 2 groups. Furthermore, we examined preoperative radiographic factors related to reoperation, including anteroposterior instability, scoliosis, lateral listhesis, scoliotic disc wedging, and radiographic instability from the supine position value to standing position value. Anteroposterior instability was defined as an anteroposterior translation of ≥ 3 mm between vertebral bodies on lateral lumbar spine radiographs. Scoliosis was defined as having a Cobb's angle $\geq 10^\circ$ at L1-5, lateral listhesis was defined as a ≥ 3 -mm distance between vertebral bodies, and scoliotic disc wedging was defined as wedging of $\geq 3^\circ$ (Figure 2). The instability of scoliosis, lateral listhesis, and scoliotic disc wedging were defined as $\geq 5^\circ$, ≥ 3 mm, and $\geq 3^\circ$ of change from the supine to standing position values, respectively.

Statistical Analysis

Statistical correlations were examined using the Mann-Whitney *U* test, one-way analysis of variance (ANOVA),

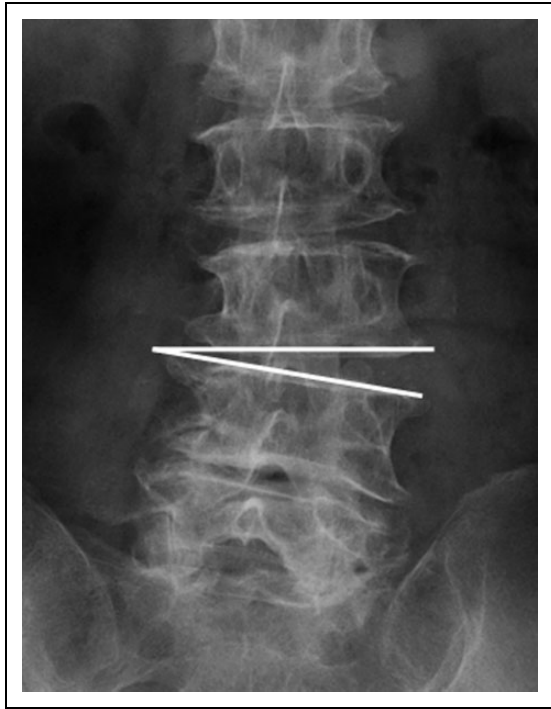


Figure 2. Schema showing scoliotic disc wedging (represented by the line). Preoperative scoliotic disc wedging was defined as wedging of $\geq 3^\circ$ on anteroposterior radiographs taken in supine position.

Pearson's χ^2 test, and Fisher's exact test. All analyses were performed using JMP 7.0 software (SAS Institute, Inc, Cary, NC). $P < .05$ was considered statistically significant.

Results

Discontinuations and Baseline Characteristics

Of 255 patients, 48 were lost to follow-up; thus, 207 patients (309 discs; 88 women and 119 men; age range = 40-86 years; mean age = 70 years) were included (follow-up ratio = 81.2%). Level of surgery was L2-3 in 19 discs; L3-4, 101 discs; L4-5, 181 discs; and L5-S1, 8 discs. Thirty-seven cases were diagnosed as DLS (group A), 51 as DS (group B), and 119 as LCS (group C). The Cobb's angle of scoliosis in group A was 13.8° (range = 10° to 18°). Patient demographics and preoperative clinical data are shown in Table 1.

Revision Rate/Clinical Outcome According to Diagnostic Groups

None of the patients experienced any major complications, including pulmonary embolism, deep vein thrombosis, cardiovascular disease, and brain infarction. Two patients had superficial infection that resolved with conservative treatment. We did not experience neurological deterioration during surgeries. Until final follow-up, 13 cases needed reoperation at the same decompression level after MBDU (reoperation incidence, 6.3%; 14 discs, 4.5%). We performed a second fusion operation

for all of these cases. The level required for reoperation was 1 in L2-3, 4 in L3-4, and 9 in L4-5. The most common site of reoperation in all groups was L4-5. The cause of reoperation was radicular pain in 6 cases due to intraforaminal stenosis by the impairment of scoliosis or scoliotic disc wedging; development of disc herniation, 3 cases; exacerbation of disc degeneration, 3 cases; and low back pain due to an intraspinal facet cyst, 1 case. The duration from the initial operation to reoperations for radicular pain due to intraforaminal stenosis was 6 (3-9) months and for disc herniation 6 (3-7) months. The duration for reoperation due to the exacerbation of disc degeneration or an intraspinal facet cyst was ≥ 14 months. Reoperation was performed in 3 cases from group A (8.1%), 2 cases from group B (3.9%), and 8 cases from group C (6.8%). Reoperation was most often required for cases in group A, though these frequencies did not significantly differ among the groups (Table 2). In group A, postoperative foraminal stenosis was the major cause of reoperation, with foraminal stenosis at L4-5 (representative case; Figure 3). Reoperation at the other decompression levels was needed in 4 cases, all in group C. Among the 3 groups, there were no significant differences in the JOA score, VAS score, and each parameter of SF-36 at the preoperative baseline. The recovery ratios of the JOA score 2 years after the first operation was 54.9% in group A, 59.9% in group B, and 55.1% in group C, but they were insignificant. The trend was toward a smaller improvement on VAS scores for low back pain in group A (8.7 mm) compared with groups B (18.6 mm) and C (16.8 mm), but these differences were not statistically significant. The other decreases of VAS score (leg pain, leg numbness) and the postoperative increase of SF-36 points (PCS, MCS, and PF) was similar among the groups (Table 2).

Clinical Characteristics of Patients That Required Reoperation After MBDU

Based on whether reoperation was required, 13 cases were allocated to group R and 194 to group NR. The JOA score of group R cases was 10.9 points preoperatively, which worsened to 9.3 points before the second operation and was 15.2 points at the final follow-up. Therefore, the recovery ratio of group R cases at the final follow-up was 24.4%, which was lower than that of cases without reoperation (58.4%; Figure 4). In group R, VAS for low back pain at the final follow-up was significantly larger than preoperative VAS for low back pain. VAS for low back pain of group NR cases was mitigated at 2 years postoperatively, and these postoperative changes differed significantly between both groups. The postoperative changes in both groups of VAS for leg pain and numbness did not differ significantly (Figure 5). Regarding SF-36, the PCS, MCS, and PF in group R deteriorated at the 2-year follow-up, particularly MCS score, which worsened from 47.1 points preoperatively to 31.5 points. Meanwhile, PCS, MCS, and PF in group NR improved at the final follow-up. These postoperative changes differed significantly between both groups (Figure 6).

Table 1. Patient's Demographics and Preoperative Clinical Data.

	Total (207 Cases)	Group A (37 Cases)	Group B (51 Cases)	Group C (119 Cases)
Age (years)	70.0 ± 8.3	70.7 ± 7.7	70.8 ± 7.9	69.4 ± 8.9
Male/female	119/88	19/18	20/31	80/39
Level of decompression				
L2-3	3	—	—	3
L3-4	12	1	3	8
L4-5	97	17	29	51
L5-S	1	1	—	—
L2-3-4	11	3	2	6
L3-4-5	71	15	14	42
L4-5-S	4	—	2	2
L2-3-4-5	5	—	1	4
L3-4-5-S	3	—	—	3
JOA score (point)	10.7 ± 4.7	10.4 ± 5.5	9.9 ± 4.5	11.1 ± 4.5
VAS for low back pain (mm)	50.1 ± 24.7	45.6 ± 28.7	52.9 ± 24.7	50.4 ± 23.3
VAS for leg pain (mm)	69.5 ± 26.2	69.4 ± 27.5	70.5 ± 27.4	69.1 ± 25.4
VAS for leg numbness (mm)	72.8 ± 24.2	71.7 ± 27.6	71.3 ± 26.6	73.7 ± 22
SF-36				
PCS score (point)	13.7 ± 13.9	9.3 ± 14.6	13.9 ± 12.5	15 ± 14.1
MCS score (point)	47 ± 9.8	48.1 ± 10.6	45.9 ± 11.6	47.1 ± 8.6
Physical functioning (point)	15.2 ± 15.1	12.1 ± 14.9	15.9 ± 14.6	15.9 ± 15.4

Abbreviations: JOA, Japanese Orthopaedic Association score; VAS, visual analog scale; SF-36, Short Form-36; PCS, Physical Component Summary; MCS, Mental Component Summary.

Table 2. Clinical Outcomes According to Diagnostic Groups.

	Group A (37 Cases)	Group B (51 Cases)	Group C (119 Cases)	P Value ^a
Number of reoperative cases (revision rate)	3 (8.1%)	2 (3.9%)	8 (6.8%)	NS
Cause of reoperation	RI: 3	ED: 2	RI: 3, DH: 3, ED: 1, LI: 1	
Level of reoperation	L4-5: 3	L3-4-5: 1, L4-5: 1	L2-3: 1, L3-4: 3, L4-5: 4	
Recovery of JOA score (%)	54.9 ± 22.6	59.9 ± 24.6	55.1 ± 27.6	NS
Change of VAS score (mm)				
VAS for low back pain	-8.7 ± 23.2	-18.6 ± 31.8	-16.8 ± 25.9	NS
VAS for leg pain	-46.6 ± 29.7	-49 ± 36.2	-42.8 ± 30.6	NS
VAS for leg numbness	-40.4 ± 31.1	-43.6 ± 33.5	-41.9 ± 29	NS
Change of SF-36 (point)				
PCS score	10.9 ± 14.7	13.4 ± 14.6	13.7 ± 16.5	NS
MCS score	2.1 ± 9.6	2.1 ± 11.3	0.4 ± 10.4	NS
Physical functioning	10.8 ± 17.4	11.8 ± 17.1	13.1 ± 16.9	NS

Abbreviations: RI, radicular pain due to intraforaminal stenosis; DH, development of disc herniation; ED, exacerbation of disc degeneration; LI, low back pain due to an intraspinal facet cyst; JOA, Japanese Orthopaedic Association score; VAS, visual analog scale; SF-36, Short Form-36; PCS, Physical Component Summary; MCS, Mental Component Summary.

^aP value is based on statistical analyses among 3 groups using ANOVA.

Radiographic Risk Factors Related to Reoperation

In 309 discs, radiographic risk factors related to reoperation were evaluated. Lateral listhesis was significantly associated with reoperation (odds ratio = 5.22). Nine L4-5 discs that needed reoperation were significantly associated with lateral listhesis and scoliotic disc wedging (odds ratios = 9.88 and 12.6, respectively). Anteroposterior instability and scoliosis were not associated with reoperation (Table 3). Four of the L3-4 discs that involved reoperations did not present radiographic risk factors significantly related to the second operation (data not shown).

Discussion

It has become increasingly important to perform more MIS. Decompression alone is less invasive than fusion surgery as a surgical treatment for patients with degenerative lumbar spine disease. However, there are concerns regarding post-operative scoliosis or instability when this approach alone is applied to treat degenerative lumbar spine disease associated with scoliosis and instability. Therefore, we investigated whether MBDU alone is appropriate for DLS or DS by examining patients who required reoperation after decompression.

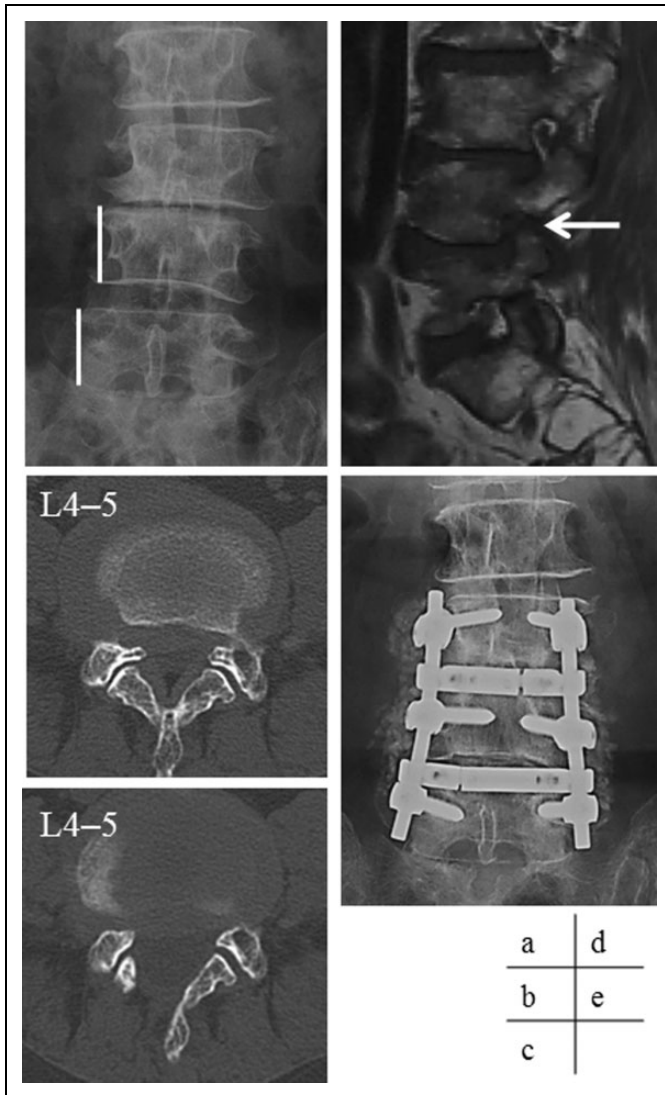


Figure 3. Representative case: A 68-year-old woman with L4-5 lumbar lateral listhesis and scoliotic disc wedging reported intermittent claudication owing to sciatica. We performed L4-5 MBDU. After this MBDU, her sciatica disappeared, but anterior thigh pain appeared 1 month postoperatively. We diagnosed radicular pain secondary to L4-5 right side intraforaminal stenosis. We therefore performed a fusion operation 5 months after the initial operation. Nevertheless, the patient's severe leg pain and low back pain persisted. (a) Preoperative radiographs of the lumbar spine. (b) Preoperative computed tomography imaging at L4-5. (c) Postoperative computed tomography imaging at L4-5. (d) Sagittal T1-weighted magnetic resonance imaging of the right foramen at L4-5 (arrow indicates foraminal stenosis). (e) Anteroposterior view radiographs of the lumbar spine at final follow-up.

During discussions regarding decompression for DLS, numerous reports have not supported the use of decompression alone for DLS.^{1,3,12} However, some articles have affirmed that decompression alone can improve DLS in certain cases. Aebi suggested that decompression may be performed in central or lateral stenosis cases, if symptoms are limited to the legs and back pain is not relevant; however, decompression procedures

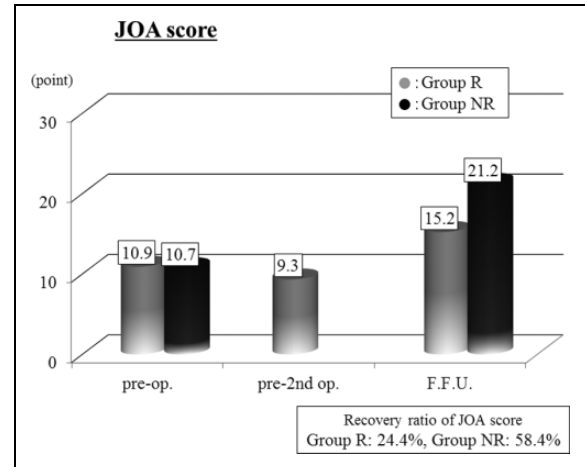


Figure 4. Graph showing clinical outcomes according to the Japanese Orthopedic Association scoring system (JOA score). The recovery ratio of JOA score in group R was significantly lower than that in group NR.

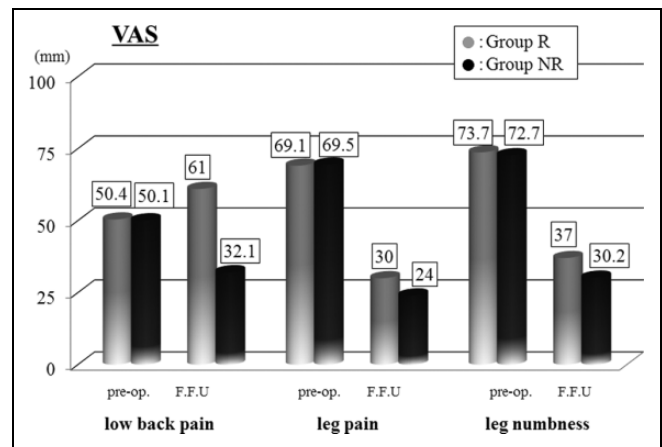


Figure 5. Graph showing Visual Analog Scale (VAS) score.

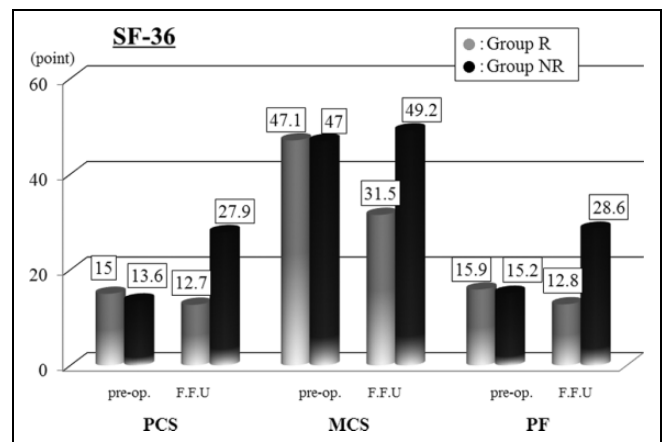


Figure 6. Graph showing Short Form-36 (SF-36) score.

in deformities are rarely indicated.¹ Hansraj et al reported that decompression could be indicated for patients with typical stenosis and $\leq 20^\circ$ of curvature.⁵ Postacchini suggested that

Table 3. Preoperative Radiographic Factors Related to Reoperation.

	Odds Ratio	P Value
Total disc: 309 discs		
Anteroposterior instability	1.63	.3
L1-5 scoliosis	1.3	.46
Instability of scoliosis	1.03	.63
Lateral listhesis	5.22*	.02
Instability of lateral listhesis	0	.42
Scoliotic disc wedging	2.78	.1
Instability of disc wedging	1.3	.46
L4-5: 181 discs		
Anteroposterior instability	1.14	.44
L1-5 scoliosis	2.57	.18
Instability of scoliosis	0	.53
Lateral listhesis	12.9*	.003
Instability of lateral listhesis	0	.59
Scoliotic disc wedging	9.88*	.03
Instability of disc wedging	1.83	.47

*Statistically significant values ($P < .05$).

elderly scoliosis patients can be managed with decompression alone when scoliosis is mild and they have little or no back pain.⁹ Furthermore, there has been very little discussion as to whether MIS decompression can improve DLS patients. Berven et al recommended the indication of a unilateral approach MIS decompression for DLS patients, including a predominance of radicular pain without disabling axial pain, radicular symptoms on the convex side of the deformity, and an intact pars interarticularis and facet joint.² Hosogane et al treated DLS patients by MIS decompression by a mid-splitting procedure, they and concluded that conducting spinal fixation to halt the progression of deformity is not always necessary if the patient's pathological condition derives mainly from canal stenosis.⁶ Tsutsui et al reported that approximately 60% of DLS patients experienced relief of low back pain after endoscopic decompression alone, which was significantly associated with the degree of apical vertebral rotation on preoperative radiography. Fusion surgery should be recommended in patients with a higher degree of apical vertebral rotation.¹¹ Our result using MIS decompression indicated that postoperative clinical status and revision rate did not differ significantly among the 3 diagnostic groups; that is, the postoperative clinical conditions of DLS patients were equivalent to that of LCS patients after MBDU. Thus, MBDU alone could improve the condition of DLS patients. However, reoperation was most often required for DLS cases, though these frequencies did not significantly differ compared with LCS cases. At a longer follow-up, DLS patients can experience poor clinical status or reoperation. Brodke et al have reported that the revision rate in laminectomy alone for DLS is 8% at an average of 5-year follow-up and the rate is lowest in comparison with that of the fusion surgery or interspinous process spacer for DLS.¹³ Here, the revision rate of the DLS group is similar to the Brodke's rate. MIS decompression can be expected to maintain clinical results and prevent the impairment of postoperative scoliosis for long periods due to good preserving posterior elements.

Moreover, MIS decompression is advantageous, particularly in adapting to the elderly patients because of less invasiveness. Thus, considering the appropriate indication for DLS, we recommend MIS decompression for DLS, particularly for elderly patients. Further studies with longer follow-up periods should be conducted to confirm if DLS patients that undergo MIS decompression maintain a good clinical condition.

Here the incidence of reoperation at the same decompression level was 6.3%, and the recovery ratio of JOA score at the final examination in patients who underwent reoperation was 24.4%; the clinical outcome/HRQOL score of group R was very poor. Particularly, postoperative VAS for low back pain deteriorated. Although some articles report that reoperation is equivalent to the primary surgery,¹⁸ numerous studies have stated that reoperation adversely affects the postoperative clinical status. Radcliff et al investigated the clinical outcomes of patients who required reoperation after decompression surgery and the clinical outcomes of those requiring reoperation were unsatisfactory.¹⁹ Scheer et al reported that in patients who underwent adult deformity surgery, reoperation adversely affected the mental recovery and overall satisfaction.²⁰ Similarly, the mental state of our patients who underwent reoperation was affected, as evaluated by the SF-36 MCS score. Although the frequency of reoperation was low after MIS decompression, reoperation should be avoided as much as possible.

Despite multiple studies on the incidence of reoperation, few comparative studies have established risk factors for reoperation after spinal stenosis surgery. In this study, reoperation was significantly associated with preoperative scoliotic disc wedging with a $\geq 3^\circ$ Cobb's angle in L4-5 (odds ratio = 9.88) and lateral listhesis (odds ratio = 5.22 [total], 12.9 [L4-5]). Numerous patients suffered from refractory radicular pain owing to foraminal stenosis caused postoperatively by scoliotic disc wedging and lateral listhesis after decompression.²¹ To our knowledge, there has been little discussion regarding decompression for degenerative lumbar spine disease associated with scoliotic disc wedging and lateral listhesis among patients requiring reoperation. Kelleher et al evaluated 75 patients who underwent bilateral decompression via a unilateral approach and showed that the surgical outcomes and patient satisfaction were equivalent between those with and without mild deformity. However, scoliosis and lateral listhesis patients demonstrated a significantly higher revision rate than those with spondylolisthesis alone or no deformity.⁷ Gupta reported that decompression alone can be indicated in patients with less than minor curves or minimal rotatory or lateral listhesis, but fusion surgery should be considered for patients with rotatory scoliosis or lateral listhesis ≥ 6 mm.⁴ Our study affirms these conclusions. Discs with scoliotic wedging and lateral listhesis manifest asymmetrical degeneration (rotational facet joint incongruity). These radiographic factors are important predictors of degenerative scoliosis progression.^{22,23} This anatomical condition of the facet joint, which leads to postoperative asymmetrical or rotatory instability, is easily affected by operative damage.⁸ The lumbar spine of DLS patients has the tendency to involve an asymmetric disc, including lateral

listhesis and scoliotic wedging. Therefore, we should safeguard against indicating MIS decompression for lumbar degenerative disease, especially DLS with these radiographic factors.

Here MBDU for DS (case with anteroposterior instability) did not cause reoperation. During discussions involving the surgical indications for fusion surgery or decompression alone to treat DS, Gibson and Waddell performed a review based on articles reporting randomized controlled trials and quasi-randomized controlled trials and reported that there was little data supporting the treatment of DS with fusion surgery.²⁴ Meanwhile, Resnick et al recommended fusion and decompression to treat DS according to guidelines for treating DS.²⁵ However, the discussions in these articles compared conventional decompression (laminectomy or medial facetectomy) and fusion surgery, and there was no comparative investigation of MIS decompression and fused operation. Chang et al reported that MBDU was useful for treating DS during a prospective study lasting ≥ 5 years.¹⁵ Here, there were few restenosis patients who suffered from anteroposterior instability (the frequency of revision was 3.9% in group B). MIS decompression minimizes the impairment by postoperative anteroposterior instability (DS). Some biomechanical studies advocated that MIS decompression could maintain postoperative spinal anteroposterior stability.^{26,27} Hasegawa et al performed mechanical studies and used frozen porcine functional spinal units to compare MIS decompression with conventional decompression (laminectomy, medial facetectomy) and reported that during MIS decompression, stability was maintained during flexion.²⁷ Thus, in taking precautions against indicating MIS decompression for cases with discs having the radiographic factors as aforementioned, we presume this can expand the surgical indications for MIS decompression to include DS.

Thus, radiographic factors for revision were elucidated. Decompression is contraindication for cases with the disc having scoliotic disc wedging and lateral listhesis especially in L4-5 discs, and therefore, surgeons should indicate fusion surgery. However, we did not verify whether fusion is appropriate compared with decompression for cases with risk factors. Further comparative studies are warranted to clarify which surgery is most appropriate for DLS or DS patients with the disc having the wedging and lateral listhesis.

Our study has numerous limitations. The spinal balance in the sagittal plane was not investigated. We cannot clarify the advantages of MIS decompression for severe scoliosis and DS cases because our patients' scoliosis and listhesis is mild. Additionally, even minimally invasive fusion surgeries, such as minimally invasive spine stabilization and minimally invasive lateral lumbar interbody fusion, are becoming more widespread. Furthermore, during the discussion of surgical options for degenerative lumbar spine disease treatment, it will be essential to perform a prospective and comparative investigation; this should deal with MIS decompression versus minimally invasive fusion surgery to treat degenerative lumbar disease. However, our results could provide valuable data for

further studies on the effect of MIS decompression on DLS or DS patients. Future prospective studies on the indication of MIS decompression should be conducted considering a wide variety of factors.

Conclusions

The clinical outcome/HRQOL score and revision rate of DLS patients were equivalent to that of LCS patients after MIS decompression, which implied that MIS decompression alone could improve the condition of DLS patients if the patient's pathological conditions derived mainly from canal stenosis. Our result for DS was similar to that of LCS. However, out of 207 patients, 13 patients (6.3%) underwent reoperation at the same decompression level after MBDU, and the clinical outcome/HRQOL score of the revision cases was poor. Patients with scoliotic disc wedging in L4-5 and lateral listhesis had a significantly higher revision rate. When we are careful to indicate decompression for patients with these risk factors related to reoperation, MIS decompression alone can successfully improve mild DLS patients with a Cobb's angle of $\leq 20^\circ$ or DS patients. Thus, these conditions should be considered during the operative decision making for DLS or DS treatment. Further discussion is needed in the future regarding the establishment of definite indications of MIS decompression for several lumbar diseases.

Declaration of Conflicting Interests

The author(s) declared no potential conflicts of interest with respect to the research, authorship, and/or publication of this article.

Funding

The author(s) received no financial support for the research, authorship, and/or publication of this article.

References

1. Aebi M. The adult scoliosis. *Eur Spine J*. 2005;14:925-948.
2. Berven SH, Deviren V, Mitchell B, Wahba G, Hu SS, Bradford DS. Operative management of degenerative scoliosis: an evidence-based approach to surgical strategies based on clinical and radiographic outcomes. *Neurosurg Clin N Am*. 2007;18:261-272.
3. Frazier DD, Lipson SJ, Fossel AH, Katz JN. Associations between spinal deformity and outcomes after decompression for spinal stenosis. *Spine (Phila Pa 1976)*. 1997;22:2025-2029.
4. Gupta MC. Degenerative scoliosis. Options for surgical management. *Orthop Clin North Am*. 2003;34:269-279.
5. Hansraj KK, O'Leary PF, Cammisa FP Jr, Hall JC, Fras CI, Cohen MS, Dorey FJ. Decompression, fusion, and instrumentation surgery for complex lumbar spinal stenosis. *Clin Orthop Relat Res*. 2001;(384):18-25.
6. Hosogane N, Watanabe K, Kono H, Saito M, Toyama Y, Matsumoto M. Curve progression after decompression surgery in patients with mild degenerative scoliosis. *J Neurosurg Spine*. 2013;18:321-326.

7. Kelleher MO, Timlin M, Persaud O, Rampersaud YR. Success and failure of minimally invasive decompression for focal lumbar spinal stenosis in patients with and without deformity. *Spine (Phila Pa 1976)*. 2010;35:E981-E987.
8. Matsumura A, Namikawa T, Terai H, et al. The influence of approach side on facet preservation in microscopic bilateral decompression via a unilateral approach for degenerative lumbar scoliosis. *J Neurosurg Spine*. 2010;13:758-765.
9. Postacchini F. Surgical management of lumbar spinal stenosis. *Spine (Phila Pa 1976)*. 1999;24:1043-1047.
10. Toyoda H, Nakamura H, Konishi S, Dohzono S, Kato M, Matsuda H. Clinical outcome of microsurgical bilateral decompression via unilateral approach for lumbar canal stenosis: minimum five-year follow-up. *Spine (Phila Pa 1976)*. 2011;36:410-415.
11. Tsutsui S, Kagotani R, Yamada H, et al. Can decompression surgery relieve low back pain in patients with lumbar spinal stenosis combined with degenerative lumbar scoliosis? *Eur Spine J*. 2013;22:2010-2014.
12. Vaccaro AR, Ball ST. Indications for instrumentation in degenerative lumbar spinal disorders. *Orthopedics*. 2000;23:260-271.
13. Brodke DS, Annis P, Lawrence BD, Woodbury AM, Daubs MD. Reoperation and revision rates of 3 surgical treatment methods for lumbar stenosis associated with degenerative scoliosis and spondylolisthesis. *Spine (Phila Pa 1976)*. 2013;38:2287-2294.
14. Kato M, Konishi S, Matsumura A, et al. Clinical characteristics of intraspinal facet cysts following microsurgical bilateral decompression via a unilateral approach for treatment of degenerative lumbar disease. *Eur Spine J*. 2013;22:1750-1757.
15. Chang HS, Fujisawa N, Tsuchiya T, Oya S, Matsui T. Degenerative spondylolisthesis does not affect the outcome of unilateral laminotomy with bilateral decompression in patients with lumbar stenosis. *Spine (Phila Pa 1976)*. 2014;39:400-408.
16. McCulloch JA, Young PA. *Essentials of Spinal Microsurgery*. Philadelphia, PA: Lippincott-Raven; 1998.
17. Fukuhara S, Bito S, Green J, Hsiao A, Kurokawa K. Translation, adaptation, and validation of the SF-36 Health Survey for use in Japan. *J Clin Epidemiol*. 1998;51:1037-1044.
18. Fu L, Chang MS, Crandall DG, Revella J. Comparative analysis of clinical outcomes and complications in patients with degenerative scoliosis undergoing primary versus revision surgery. *Spine (Phila Pa 1976)*. 2014;39:805-811.
19. Radcliff K, Curry P, Hilibrand A, et al. Risk for adjacent segment and same segment reoperation after surgery for lumbar stenosis: a subgroup analysis of the Spine Patient Outcomes Research Trial (SPORT). *Spine (Phila Pa 1976)*. 2013;38:531-539.
20. Scheer JK, Mundis GM, Klineberg E, et al. Recovery following adult spinal deformity surgery: the effect of complications and reoperation in 149 patients with 2-year follow-up. *Eur Spine J*. 2016;25:2612-2621.
21. Liu H, Ishihara H, Kanamori M, Kawaguchi Y, Ohmori K, Kimura T. Characteristics of nerve root compression caused by degenerative lumbar spinal stenosis with scoliosis. *Spine J*. 2003;3:524-529.
22. Murata Y, Takahashi K, Hanaoka E, Utsumi T, Yamagata M, Moriya H. Changes in scoliotic curvature and lordotic angle during the early phase of degenerative lumbar scoliosis. *Spine (Phila Pa 1976)*. 2002;27:2268-2273.
23. Seo JY, Ha KY, Hwang TH, Kim KW, Kim YH. Risk of progression of degenerative lumbar scoliosis. *J Neurosurg Spine*. 2011;15:558-566.
24. Gibson JN, Waddell G. Surgery for degenerative lumbar spondylolisthesis: updated Cochrane Review. *Spine (Phila Pa 1976)*. 2005;30:2312-2320.
25. Resnick DK, Watters WC 3rd, Sharan A, et al. Guideline update for the performance of fusion procedures for degenerative disease of the lumbar spine. Part 9: lumbar fusion for stenosis with spondylolisthesis. *J Neurosurg Spine*. 2014;21:54-61.
26. Hamasaki T, Tanaka N, Kim J, Okada M, Ochi M, Hutton WC. Biomechanical assessment of minimally invasive decompression for lumbar spinal canal stenosis: a cadaver study. *J Spinal Disord Tech*. 2009;22:486-491.
27. Hasegawa K, Kitahara K, Shimoda H, Hara T. Biomechanical evaluation of destabilization following minimally invasive decompression for lumbar spinal canal stenosis. *J Neurosurg Spine*. 2013;18:504-510.