

Decitabine Induced Transient Cardiomyopathy: A Case Report

Chitradeep De², Jaya Phookan¹, Valay Parikh¹, Tarun Nagrani², Mayur Lakhani², Frank Forte³
and James Lafferty²

¹Department of Internal Medicine, Staten Island University Hospital, New York. ²Department of Cardiology, Staten Island University Hospital, New York. ³Department of Hematology-Oncology, Staten Island University Hospital, New York.
Corresponding author email: jayaphookan@gmail.com

Abstract

Case report: A 75-yr-old gentleman, with a past medical history of diabetes mellitus and Acute Myeloid Leukemia presented to our emergency department with a chief complaint of exertional dyspnea and chest pain. A week prior to this visit, he had received a cycle of decitabine chemotherapy at 20 mg/metered square for ten days. This was his second cycle of decitabine. His out patient medications included megestrol, omeprazole, morphine sulfate and insulin glargine. The patient was admitted to the Coronary Care Unit for Acute Coronary Syndrome. His cardiac enzymes were elevated (peak troponin 30 ng/mL, CKMB 67.4 ng/mL). His 12 lead EKG revealed sinus tachycardia with a ventricular rate of 113, but without acute ST-T wave changes. The BNP was 259 pg/mL. A 2D echo revealed moderate diffuse hypokinesis with an EF of 35%. He subsequently underwent a left heart catheterization, which showed non-obstructive CAD. In our patient, the elevated troponins (peak troponin 30 ng/mL) and BNP were seen concomitant with the onset of cardiogenic shock. Two months ago, his 2 D echocardiogram revealed an ejection fraction of about 55%–65% with slightly increased left ventricular (LV) wall thickness.

Discussion: The most common adverse effects of decitabine include cytopenia, nausea, pain and erythema/nodules at the injection site. To date, there has been only one reported case of a hypomethylating agent inducing acute myocarditis. We present a case of reversible, non-ischemic cardiomyopathy secondary to decitabine chemotherapy, which resolved after the drug was discontinued.

Trials involving decitabine for the treatment of MDS reported no myocarditis. In our case, the diagnosis of transient cardiomyopathy was highly probable since the patient's troponins and echocardiogram returned to baseline after discontinuation of treatment. Also, the patient never had any further chest pain at his 6 month follow up. In this case, we believe that the elevated Troponin I levels, along with a cardiac catheterization revealing patent coronary vessels, favor our hypothesis that our patient suffered from acute myocarditis as a result of direct toxicity from decitabine chemotherapy. We doubt that there was an underlying infectious etiology, since the patient had three negative blood cultures, two negative urine cultures and a negative viral serology. Our case demonstrates that chest pains in a patient treated with hypomethylating agents should be further explored in order to rule out acute myocarditis.

Keywords: decitabine, cardiomyopathy, myocarditis, chemotherapy, hypomethylating agent

Clinical Medicine Insights: Oncology 2012;6 325–329

doi: [10.4137/CMO.S8598](https://doi.org/10.4137/CMO.S8598)

This article is available from <http://www.la-press.com>.

© the author(s), publisher and licensee Libertas Academica Ltd.

This is an open access article. Unrestricted non-commercial use is permitted provided the original work is properly cited.

Introduction

Decitabine, a DNA methylation inhibitor, is indicated for the treatment of Myelodysplastic Syndrome (MDS). Due to its significant role in reversing epigenetic silencing in cancer cells, it is also used in other hematologic malignancies, such as acute myelogenous leukemia (AML) and chronic myelogenous leukemia (CML). Here, we are presenting a case of reversible non-ischemic cardiomyopathy in a 75-year-old man who was being treated with decitabine for de novo AML.

Case Report

A 75 year old male with a past medical history significant for Diabetes mellitus type 2, Acute Myeloid Leukemia, Deep Vein Thrombosis of upper extremity with a past surgical history of inguinal hernia repair presented to the emergency department with a chief complaint of shortness of breath (SOB) for 2 days. SOB worsened with routine activity and was associated with intermittent retrosternal chest discomfort which was 8/10 in intensity and which the patient described as a “chest tightness” on mild exertion. There is no history of any cardiac disease or similar symptoms prior to this admission. He denied fever, cough, sick contacts, recent travel, and pain on deep inspiration, orthopnea or paroxysmal nocturnal dyspnea. A week prior to this visit, he had completed his second cycle of Decitabine chemotherapy at 20 mg/meter square for 10 days. In this particular ER visit, routine blood work had revealed that he was anemic and he also had a low platelet count. So he was admitted for packed red blood cells (PRBC) and Single Donor Platelet (SDP) transfusion and work up of his chest discomfort/SOB.

One year prior to admission, the patient had been diagnosed with Acute Myeloid Leukemia de novo and had already received two cycles of decitabine and was doing well so far. His out patient medications included megestrol, omeprazole, morphine sulfate as needed and insulin glargine. He was regularly following up with his oncologist and was a very compliant patient.

On examination, the patient was a well appearing white gentleman who was fully alert and oriented, afebrile with blood pressure of 105/51 and a pulse of 126 bpm. He was however unable to complete full sentences and his respiratory rate was 22 per minute

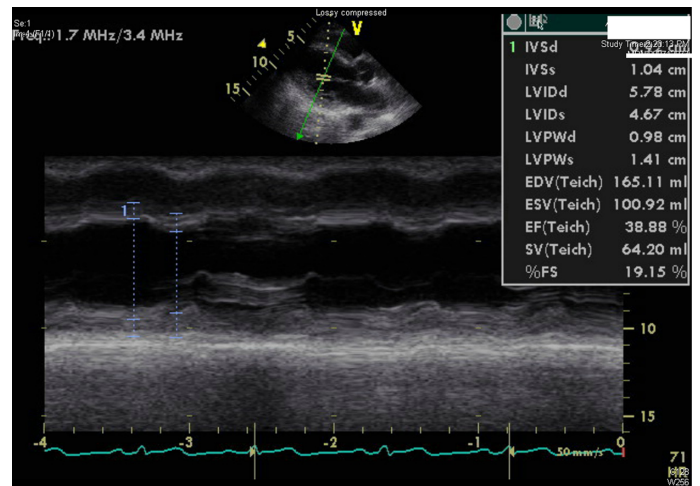


Figure 1. M-mode Echocardiogram through mid Left Ventricle (LV) showing hypokinesia of antero-septal and infero-lateral walls and depressed LV function.

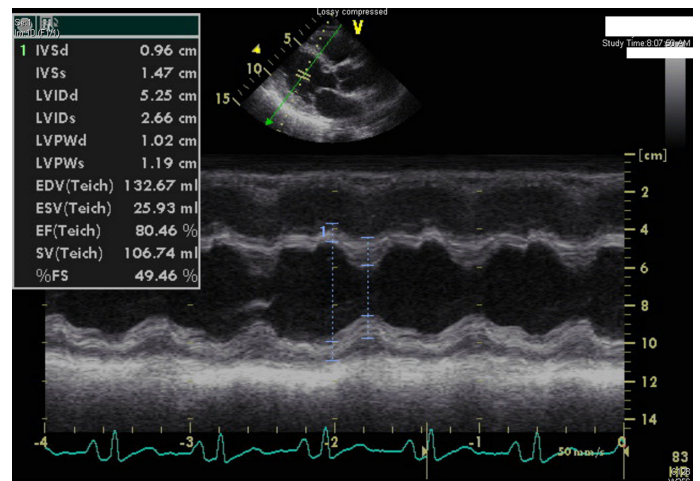


Figure 2. M-mode Echocardiogram through LV showing recovery of LV and normal wall motion.

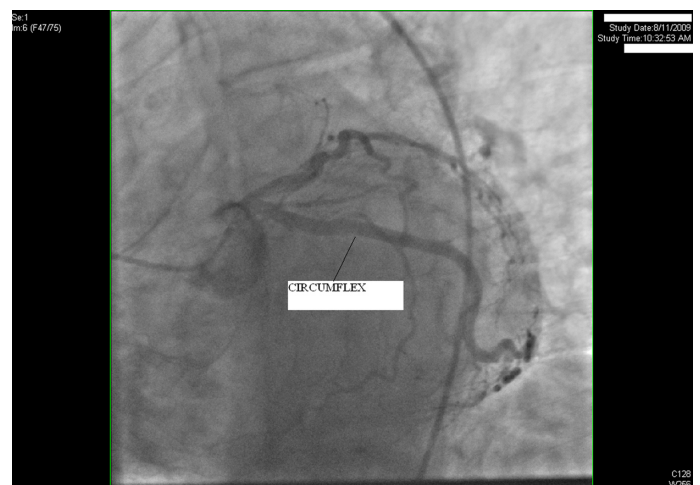

Figure 3. Left Anterior Descending (LAD) coronary artery caudal view during cardiac catheterization showing no significant coronary artery disease in LAD and Circumflex arteries.

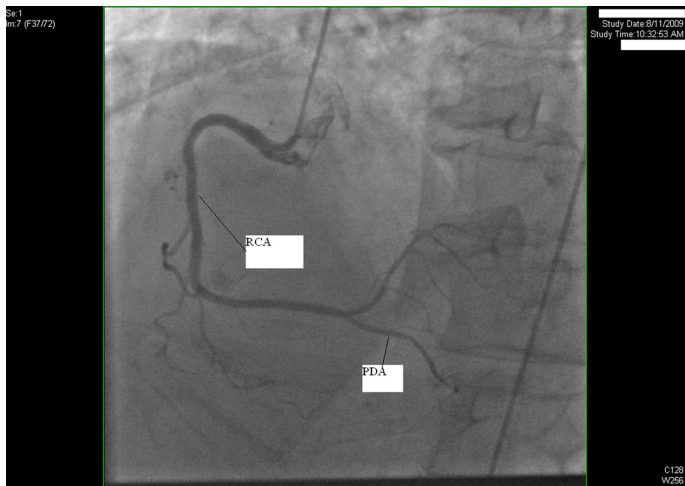


Figure 4. LAD view during cardiac catheterization showing no significant disease in Right Coronary Artery (RCA).

with a SaO₂ of 96%–98% on 2L NC. The chest examination revealed mild bilateral rales, he was tachycardic but the rest of the physical examination was unremarkable. No petechiae or active bleeding was noted.

Admitting laboratory results revealed hemoglobin of 7.2 g/dL (MCV 85.3, RDW 14.5) white cell count of 1000/mm³ with an absolute neutrophil count (ANC) of 500/mm³ and a platelet count of 96,000/mm³. Troponin I was elevated at 2.8 ng/mL. His 12 lead EKG revealed sinus tachycardia with a ventricular rate of 113, but without acute ST–T wave changes. Urine analysis was normal. His Chest X-ray was unremarkable. The BNP was 259.

Shortly after admission, the patient developed a low-grade temperature (100.5F). Blood cultures and urine cultures were sent, and broad-spectrum antibiotics were begun.

The patient was admitted to the Coronary Care Unit (CCU) with a working diagnosis of suspected Acute Coronary Syndrome and Neutropenic sepsis. Two units of packed red cells were transfused. In the CCU, the patient became hypotensive, responded poorly to fluid resuscitation and was started on vaso-pressors. His troponin I peaked at 30 ng/mL and trended downwards over the next week. Cardiac catheterization was delayed secondary to the pancytopenia and suspected neutropenic sepsis. A cortisol level of 33 suggested an appropriate response of the adrenal gland. A 2D echo revealed moderate diffuse hypokinesis with an EF of 35%. The patient was eventually weaned off pressors after 5 days. Two months prior to this admission,

a 2 D echocardiogram revealed an ejection fraction of about 55%–65% with slightly increased left ventricular (LV) wall thickness.

Three sets of blood cultures and two sets of urine cultures were negative. The patient continued to be neutropenic and received 3 doses of G-CSF. Antibiotics were continued until the patient's ANC was greater than 1000/mm³. On day seven, the patient was transferred to the medical floor and a repeat 2D echo, showed recovery of the LV function, with an EF of 50%, in the absence of any regional wall motion abnormalities. Viral cultures for coxsackie and echo viruses were negative. On day 12, his ANC had improved and oral antibiotics were stopped. A bone marrow biopsy revealed a hypocellular bone marrow without evidence of acute leukemia. He subsequently underwent a left heart catheterization which showed non-obstructive CAD with normal LV function. He was discharged on Hospital day # 20 in stable condition. His treatment for AML continued as an out patient; he had a repeat bone marrow biopsy 2 months after his discharge which revealed less than 5% CD34 positive blasts. Flow cytometry revealed less than 1% blasts. He went on to receive two more cycles of Decitabine at 20 mg per metered square per day, but his dose was reduced from 10 days for each cycle to 5 days for each cycle for the next 2 cycles on account of his recent cardiac complications. No further cardiac symptoms were reported after he was administered the reduced doses of Decitabine. A year after his initial cardiac complications, he expired from sepsis as a complication of Health Care Associated Pneumonia.

Discussion

Decitabine is a cytosine analogue that was synthesized in the 1960s. It is a hypomethylating agent that inhibits DNA methyltransferase. Since hypomethylation was thought to play a major role in oncogenesis, decitabine was thought to hasten or induce neoplasia. However more recently, the views on methylation have changed. A localized pattern of hypermethylation affecting epigenetic dysregulation in cancer was also discovered.¹ This increased methylation was shown to inhibit the tumor suppressor gene expression permanently, thereby providing cancers with an alternative to mutations or deletions for inactivation of tumor suppressor and other critical genes.² This observation revived the interest in hypomethylat-



ing agents as antineoplastic agents. Decitabine, an analogue of 5-azacytidine, which has a wide range of activity in MDS, and other hematologic malignancies such as previously treated and untreated de novo AML of all French-American-British (FAB) subtypes, CML, in sickle cell anemia, in which hypermethylation and tumor suppressor gene silencing play a major role was approved by the FDA in 2006 for its role in inhibiting DNA methyltransferase and thereby causing cell death in the S-phase of the cell cycle.

The most common side effects associated with Decitabine include neutropenia, thrombocytopenia, anemia, fatigue, nausea, cough, fever, constipation, and diarrhea. Significant cardiovascular adverse reactions with this drug are peripheral edema (25%), pallor (23%), cardiac murmurs (16%), chest discomfort (7%), and hypotension (6%). Two multicenter phase II trials were conducted in Europe recently to study the safety and efficacy of this drug and the only cardiovascular side effect reported was pulmonary edema in 6% of the study population. In general, the cardiovascular side effects of decitabine are mild and rare. However a recent case report suggested that chest pains in patients treated with hypomethylating agents needs further exploration to rule out acute myocarditis.³

Cardiac toxicity is a limiting factor for many of the chemotherapeutic drugs and has been classically described for anthracyclines,⁴ thought to be the result of free radicals production. The early prediction of chemotherapy induced cardiotoxicity is of utmost importance to prevent dismal outcomes.⁵ EKG changes are non-specific and include ST segment and T-wave changes, which may represent acute toxicity. In our patient, there were no significant EKG changes except for the presence of sinus tachycardia which was thought to be the result of cardiogenic shock.

The role of various biomarkers as early predictors of cardiotoxicity has been studied often with anthracyclines.⁶ Several studies suggest that elevated troponins I and T after chemotherapy (anthracyclines) were associated with development of future LV dysfunction. However, results have been inconsistent. Also the rising BNP and NT pro (N-terminal prohormone) BNP levels may suggest future development of cardiomyopathy.⁷ In our patient, the elevated troponins and BNP were seen concomitant with the

onset of cardiogenic shock, but their levels prior to admission were unknown. Routine evaluation of cardiac function by MUGA Scan or 2-D echo is a standard practice during treatment with adriamycin.⁸ Whether such routine surveillance is helpful in cases of decitabine therapy, is unknown.

It has been established in clinical trials that the incidence of chemotherapy induced cardiomyopathy increases with advancing age. In one trial, patients older than 65 years were 2.25 times more likely to develop myocardial dysfunction secondary to anthracyclines than those less than 65.⁹ Similarly, trastuzumab associated cardiomyopathy was also higher in the older age group.¹⁰ Thus the geriatric population undergoing treatment for MDS with Decitabine, should be closely followed for signs and symptoms of LV dysfunction.

At present more trials are needed to formulate a surveillance strategy for LV dysfunction in these patients.

In this case, we believe that the elevated Troponin I levels along with a cardiac catheterization revealing patent coronary vessels, favor our hypothesis that our patient suffered from acute myocarditis as a result of direct toxicity from decitabine chemotherapy. Although our patient did not undergo cardiac magnetic resonance imaging (Cardiac MRI) to demonstrate the signs of Myocarditis (Lake Louise criteria¹¹) we strongly doubt that there was an underlying infectious etiology, since the patient had three negative blood cultures, two negative urine cultures and a negative set of viral cultures. Many studies have shown mild elevations of Troponin I in cases of septic shock usually with a peak of 10 ng/mL.¹² In our case there was a significant elevation of Troponin I, which peaked at 30 ng/mL. The troponin levels later normalized, the chest pains disappeared and the patient was stable to be discharged home.

Conclusion

Decitabine has been increasingly used in management of hematologic malignancies. Cardiotoxicity is relatively rare, the main side effect being peripheral edema. After a review of the literature, we conclude that this is the second case of transient cardiomyopathy secondary to decitabine-induced myocarditis that has been reported, with resolution after the drug was discontinued.



Author Contributions

Conceived and designed the experiments: CD. Analysed the data: JP, VP. Wrote the first draft of the manuscript: CD. Contributed to the writing of the manuscript: JP. Agree with manuscript results and conclusions: JL, ML, CD, FF, TN, VP, JP. Jointly developed the structure and arguments for the paper: ML, VP. Made critical revisions and approved final version: JL, FF. All authors reviewed and approved of the final manuscript.

Funding

Author(s) disclose no funding sources.

Competing Interests

Author(s) disclose no potential conflicts of interest.

Disclosures

Author(s) have provided signed confirmations to the publisher of their compliance with all applicable legal and ethical obligations in respect to declaration of conflicts of interest, funding, authorship and contributorship, and compliance with ethical requirements in respect to treatment of human and animal test subjects. If this article contains identifiable human subject(s) author(s) were required to supply signed patient consent prior to publication. Author(s) have confirmed that the published article is unique and not under consideration nor published

by any other publication and that they have consent to reproduce any copyrighted material. The peer reviewers declared no conflicts of interest.

References

1. Baylin SB, Herman JG, Graff JR, Vertino PM, Issa JP. Alterations in DNA methylation: a fundamental aspect of neoplasia. *Adv Cancer Res.* 1998;72:141–96.
2. Jones PA, Takai D. The role of DNA methylation in mammalian epigenetics. *Science.* Aug 10, 2001;293(5532):1068–70.
3. Bibault JE, Cambier N, Lemahieu JM, Quensel B, Auffret M, Rose C. Acute Myocarditis induced by hypomethylating agents. *Journal of Clinical Oncology.* May 10, 2001;29(14):e411–2. Epub February 28, 2001.
4. Von Hoff DD, Layard MW, Basa P, et al. Risk factors for doxorubicin-induced congestive heart failure. *Ann Intern Med.* Nov 1979;91(5):710–7.
5. Meinardi MT, van Veldhuisen DJ, Gietema JA, et al. Prospective evaluation of early cardiac damage induced by epirubicin-containing adjuvant chemotherapy and locoregional radiotherapy in breast cancer patients. *J Clin Oncol.* May 15, 2001;19(10):2746–53.
6. Herman EH, Zhang J, Lipschutz SE, et al. Correlation between serum levels of cardiac troponin-T and the severity of the chronic cardiomyopathy induced by doxorubicin. *J Clin Oncol.* Jul 1999;17(7):2237–43.
7. Nousiainen T, Jantunen E, Vanninen E, Remes J, Vuolteenaho O, Hartikainen J. Natriuretic peptides as markers of cardiotoxicity during doxorubicin treatment for non-Hodgkin's lymphoma. *Eur J Haematol.* Feb 1999;62(2):135–41.
8. Meinardi MT, van Veldhuisen DJ, Gietema JA, et al. Prospective evaluation of early cardiac damage induced by epirubicin-containing adjuvant chemotherapy and locoregional radiotherapy in breast cancer patients. *J Clin Oncol.* May 15, 2001;19(10):2746–53.
9. Swain SM, Whaley FS, Ewer MS. Congestive heart failure in patients treated with doxorubicin: a retrospective analysis of three trials. *Cancer.* Jun 1, 2003;97(11):2869–79.
10. Seidman A, Hudis C, Pierri MK, et al. Cardiac dysfunction in the trastuzumab clinical trials experience. *J Clin Oncol.* Mar 1, 2002;20(5):1215–21.
11. Friedrich MG, Sechtem U, Schulz-Menger J, et al. Cardiovascular Magnetic Resonance in Myocarditis: A JACC White Paper. *J Am Coll Cardiol.* 2009;53:1475–87.
12. Favory R, Neviere R. Significance and interpretation of elevated troponin in septic patients. *Crit Care.* 2006;10(4):224.