

Comparison of the effect of cycloplegic versus NSAID eye drops on pain after photorefractive keratectomy

Kaveh Abri Aghdam^{a,b}, Hossein Aghaei^{a,*}, Siamak Shokrollahi^a, Mahmoud Joshaghani^a,
Hossein Nazari^c, Masih Hashemi^a, Mohammad Jafar Ghaempanah^a

^a Eye Research Center, Department of Ophthalmology, Rassoul Akram Hospital, Iran University of Medical Sciences, Tehran, Iran

^b Brain and Spinal Cord Injury Research Center, Neuroscience Institute, Tehran University of Medical Sciences, Tehran, Iran

^c Doheny Eye Institute, University of Southern California (USC), Los Angeles, USA

Received 7 October 2015; revised 13 November 2015; accepted 13 November 2015

Available online 8 January 2016

Abstract

Purpose: To compare the effect of Homatropine and Diclofenac eye drops for reducing pain after photorefractive keratectomy (PRK).

Methods: This randomized, double-masked, interventional study included 32 patients (64 eyes) who underwent bilateral PRK. After operation, patients received Homatropine eye drops in one eye and Diclofenac eye drops in the fellow eye for 48 h. The level of pain was evaluated using visual analogue scale (VAS), verbal rating scale (VRS), and pain rating index (PRI) at 0.5, 24, and 48 h after operation.

Results: The level of pain was statistically similar between the two eyes half an hour after operation; however, Diclofenac eyes had significantly less pain 24 h after operation (1.7 ± 1.4 vs 5.8 ± 2.1 , $P < 0.001$ for VAS, 0.6 ± 0.6 vs 2.4 ± 1.1 , $P < 0.001$ for VRS, and 3.4 ± 3.4 vs 12.0 ± 6.9 , $P < 0.001$ for PRI, respectively). Also, 48 h after surgery, the pain scores were less in the Diclofenac eyes (1.6 ± 1.8 vs 3.4 ± 2.8 , $P < 0.001$ for VAS, 0.6 ± 0.6 vs 1.2 ± 0.9 , $P < 0.001$ for VRS, and 3.3 ± 3.7 vs 6.5 ± 6.2 , $P < 0.001$ for PRI). No case with delayed epithelial healing in both groups was observed.

Conclusion: The effect of Homatropine seems to be lower compared to Diclofenac for reducing pain after photorefractive keratectomy.

Copyright © 2015, Iranian Society of Ophthalmology. Production and hosting by Elsevier B.V. This is an open access article under the CC BY-NC-ND license (<http://creativecommons.org/licenses/by-nc-nd/4.0/>).

Keywords: Cycloplegic; Pain; Photorefractive keratectomy; Nonsteroidal anti-inflammatory drug

Introduction

Photorefractive keratectomy (PRK) is a safe and effective procedure for correction of mild to moderate refractive error. One of the main drawbacks of this operation is significant postoperative pain secondary to removal of epithelium and exposure of the nerve endings.¹ Pain is especially severe in the first 24 h after surgery, and despite using therapeutic contact lens, the discomfort may be intolerable.¹ Several medications with different success rates and complications have been

reported to be useful for reducing post-PRK pain. These include systemic analgesics and topical nepafenac, Diclofenac, tetracaine, ketorolac, proparacaine, and morphine.^{2–9}

Cycloplegics are medications that are usually used for inducing mydriasis as well as pain relief in ophthalmology. The long ciliary nerves are given off from the nasociliary nerve which is a branch of the ophthalmic division of trigeminal nerve.¹⁰ Acetylcholine is a common neurotransmitter in this pathway which affects muscarinic receptors in iris-ciliary body.¹¹ Considering the effect of cycloplegics on aborting ciliary body spasm, they are widely used to smooth the pain secondary to ocular surface abrasions and uveitis.^{12,13}

In a recent study, we assessed the effect of a topical cycloplegic drug, Homatropine, after PRK.¹⁴ The pain was significantly less in Homatropine-used eyes compared with

* Corresponding author. Rassoul Akram Hospital, Iran University of Medical Sciences, Tehran, Iran.

E-mail address: Aghaee.h1376@yahoo.com (H. Aghaei).

Peer review under responsibility of the Iranian Society of Ophthalmology.

control fellow eyes. Postoperative medications for control fellow eyes were topical Betamethasone, four times daily, topical Chloramphenicol, four times daily, and oral Acetaminophen, as needed by patient's discretion. In the present study, the effect of topical Homatropine on relieving pain after PRK was compared with a topical nonsteroidal anti-inflammatory drop, Diclofenac, which has been approved by the FDA for reducing pain after refractive surface ablation.

Methods

In this double-masked contralateral clinical trial, 32 patients (64 eyes) who were candidates for bilateral PRK surgery between January and April 2011 were included. The study was conducted in accordance with the ethical standards stated in the 1964 Declaration of Helsinki and approved by the Eye Research Center Ethics Committee with informed consent obtained from patients. All patients underwent initial complete ocular examinations including manifest and cycloplegic refraction, slit-lamp examination, intraocular pressure measurement, and dilated fundus examinations. Patients with hyperopia, anisometropia, previous ocular surgeries, and history of neurosensory pain disorders were excluded.

Epithelium was removed by 20% alcohol over the cornea for 20 s in an 8.5–9 mm ring and using golf headed spatula. Laser ablation was performed using a Technolas 217 instrument (Bausch & Lomb).

After corneal ablation, sterile surgical sponge soaked in Mitomycin C was placed over the cornea, and then the cornea surface was washed with 100 ml of balanced salt solution. After surgery, a plano bandage contact lens was placed on the cornea, and the contact lenses were removed at the third postoperative day. Postoperative medications were topical betamethasone, four times daily, topical ciprofloxacin, four times daily, and oral acetaminophen, as needed by patient's discretion. Topical Homatropine (Sina Darou, Tehran, Iran), four times daily, was added to the postoperative medications for one eye (Homatropine eye). For the fellow eye, topical Diclofenac eye drop (Sina Darou, Tehran, Iran), 4 times daily, was prescribed. The envelope of the Homatropine and Diclofenac bottles were removed by one of the authors (KA) and replaced by a sign indicating the type of the drop which was known only for the same researcher. The patients were instructed to use the drops for the same scheduled eye, and those who reported mistakes were excluded from the study. All patients were evaluated daily for epithelial wound healing. Randomization of the eyes was performed by one of the authors (KA). The surgeon, patients, and researcher evaluating patients' pain were all unaware of the randomization process and the eye which was receiving Homatropine drops.

All the procedures and medications were similar for both eyes except for Homatropine and Diclofenac eye drops. Before surgery, patients were oriented to a pain questionnaire by one of the authors. Pain rating scales were explained to the patients

and reevaluated to confirm their understanding. Patients were asked about pain and discomfort in each eye and requested to express their pain experience with three different subjective pain scoring questionnaires: visual analogue scale (VAS), verbal rating scale (VRS), and Mac-Gill pain questionnaire. For visual analogue scale, the patients were asked to indicate their pain sensation severity in a linear line marked from 0 for "no pain" to 10 for "the most severe intolerable pain I have ever experienced."¹⁵ For recording verbal rating scale (VRS), patients were asked to rate their experience of pain on the Keele's verbal pain chart.^{16,17} This scale allowed them to score pain in a semiquantitative way: 0 = no pain, 1 = minimal pain, 2 = moderate pain, 3 = severe pain, and 4 = agonizing pain. McGill Pain Questionnaire measures pain score as a sum of the sensory and affective pain rating index (S-PRI and A-PRI).^{18,19}

Data were entered using SPSS software (SPSS 15.0, SPSS Inc., Chicago, IL). Kolmogorov–Smirnov and Q–Q plots were used for testing the distribution of variables and Wilcoxon signed rank test was used for analysis. P value less than 0.05 was considered significant.

Results

Thirty-three patients entered in this study. One patient was excluded due to using the drops for both eyes; therefore, the data from 32 patients were analyzed. Mean corrected refractive error was not different between Homatropine and Diclofenac groups (-3.3 ± 1.3 and -3.4 ± 1.4 , respectively, $P = 0.4$).

Table 1 shows the pain scores of the patients. Since the Kolmogorov–Smirnov test showed a non-normal distribution of some variables, we repeated the analysis using a nonparametric test (Wilcoxon signed rank test). VAS, VRS, and PRI scores, 0.5 h after operation, was not significantly different between Homatropine and control eyes ($P = 0.3$, $P = 0.2$, and $P = 0.6$, respectively). Figs. 1–3 represent overlay scatterplots showing pain scores in terms of VAS, VRS, and PRI, respectively. Twenty-four and 48 h after surgery, pain scores on VAS, VRS, and PRI were all significantly lower in Diclofenac eyes. The contact lenses were removed at the third

Table 1

Means \pm standard deviations of pain scores on visual analogue scale (VAS), verbal rating scale (VRS), and pain rating index (PRI) at different time points after photorefractive keratectomy.

	Homatropine group	Diclofenac group	P value
VAS at 0.5 h	2.2 \pm 2.3	2.4 \pm 2.6	0.37
VAS at 24 h	1.7 \pm 1.4	5.8 \pm 2.1	<0.001
VAS at 48 h	1.6 \pm 1.8	3.4 \pm 2.8	<0.001
VRS at 0.5 h	0.8 \pm 0.8	0.9 \pm 0.9	0.26
VRS at 24 h	0.6 \pm 0.6	2.4 \pm 1.1	<0.001
VRS at 48 h	0.6 \pm 0.6	1.2 \pm 0.9	<0.001
PRI at 0.5 h	3.5 \pm 3.1	3.8 \pm 3.7	0.64
PRI at 24 h	3.4 \pm 3.4	12.0 \pm 6.9	<0.001
PRI at 48 h	3.3 \pm 3.7	6.5 \pm 6.2	<0.001

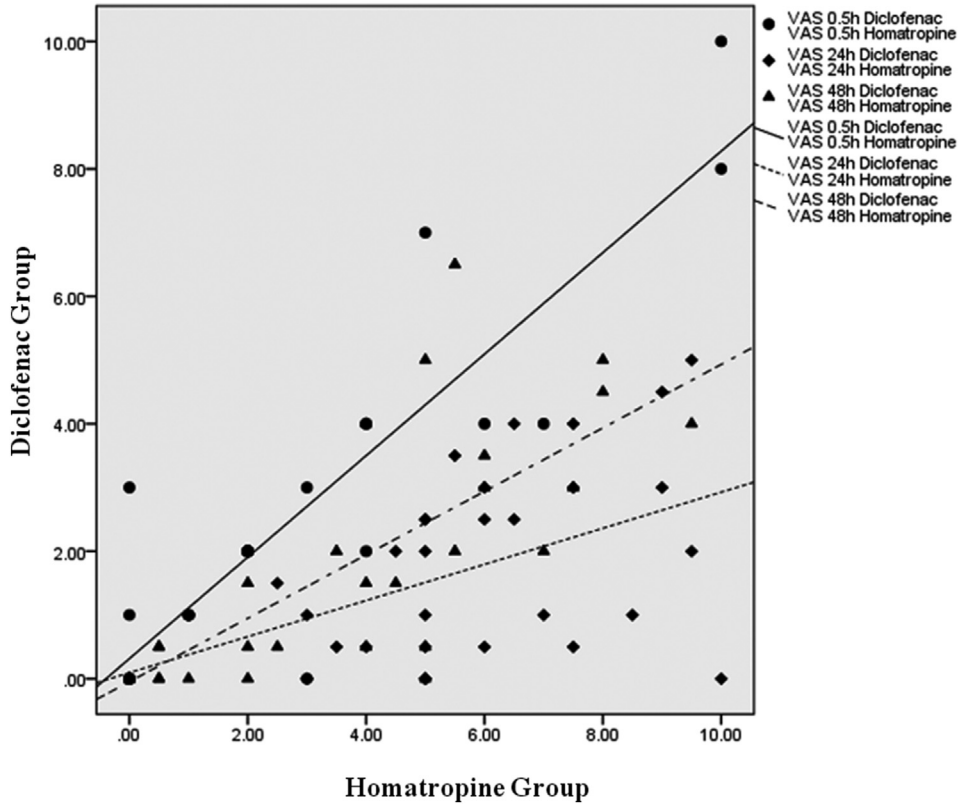


Fig. 1. Overlay scatterplot showing pain scores in terms of visual analogue scale (VAS) in Homatropine group versus Diclofenac group.

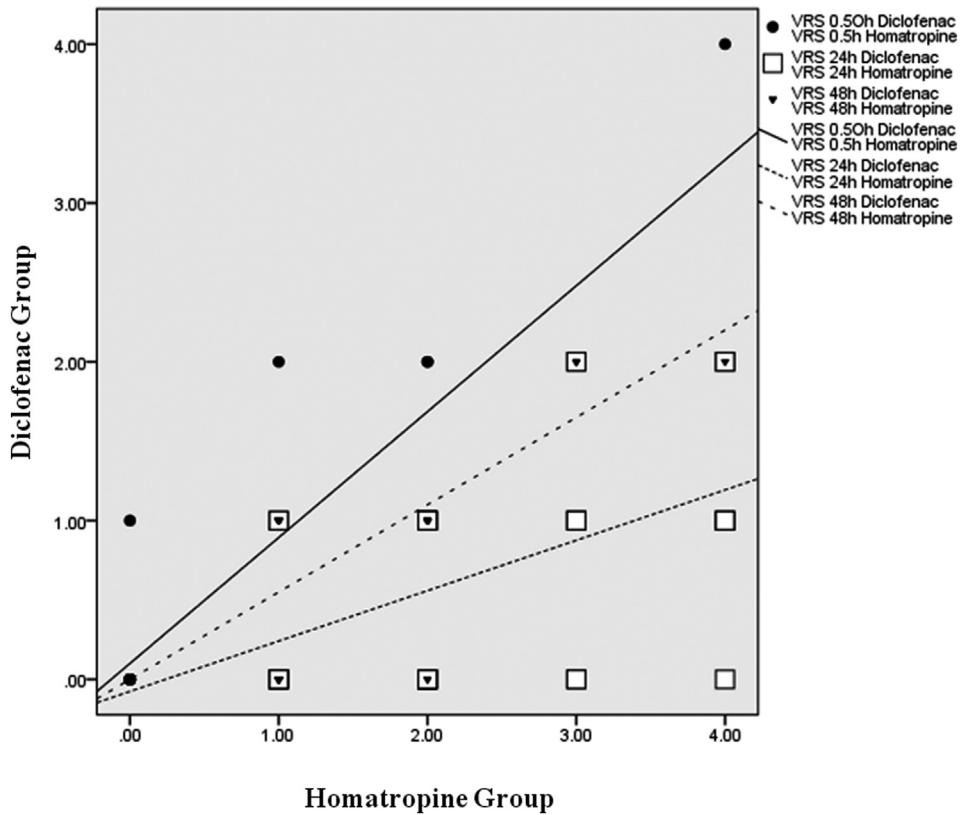


Fig. 2. Overlay scatterplot showing pain scores in terms of verbal rating scale (VRS) in Homatropine group versus Diclofenac group.

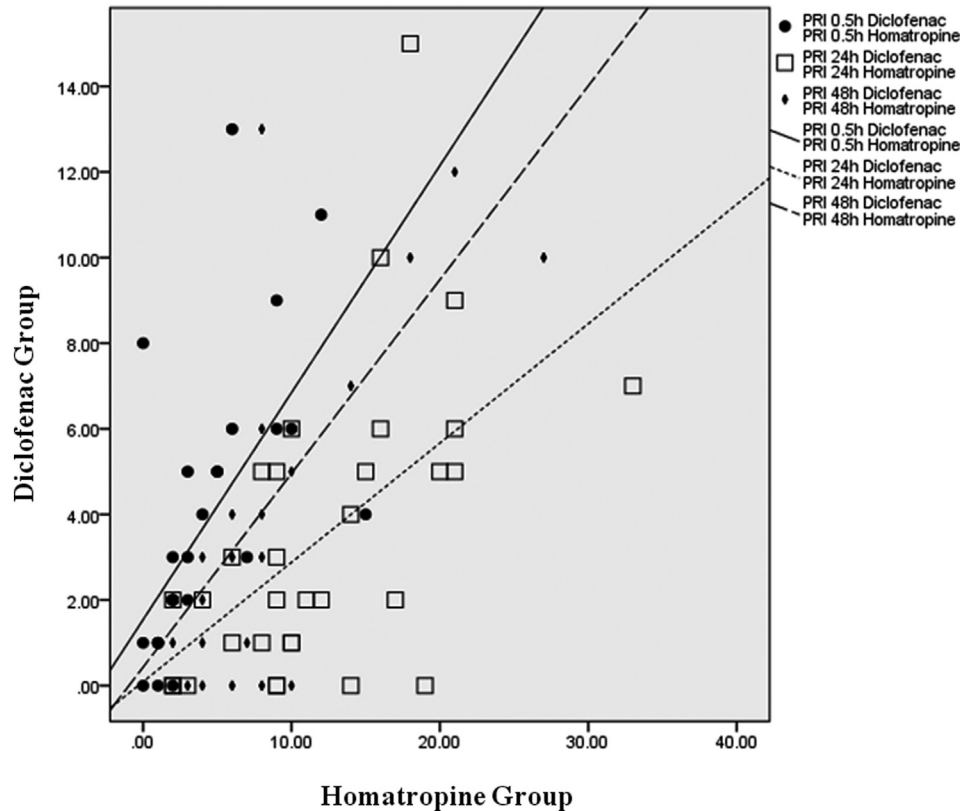


Fig. 3. Overlay scatterplot showing pain scores in terms of pain rating index (PRI) in Homatropine group versus Diclofenac group.

postoperative day, and corneal epithelium was healed at the 4th day after surgery in all eyes.

Discussion

Postoperative pain is one of the most significant disadvantages of PRK.^{20–23} Exposure of traumatized nerve endings causes severe postoperative pain which usually lasts for the first 3–4 days until corneal surface re-epithelialization occurs. There is not a general agreement on the best approach to manage postoperative pain in these patients. A variety of systemic and topical medications have been used for pain reduction after PRK. Oral nonsteroidal anti-inflammatory drugs (NSAIDs), Gabapentin, and opiates are among oral medications being used with different success and complication rates.^{22–24} Topical NSAID drugs are among the most popular medications to control post-PRK pain. Diclofenac and Ketorolac have been approved by the FDA for pain control after surface ablations. Bromfenac, a recently approved topical NSAID for the treatment of post cataract surgery inflammation and pain, has been found to be effective in controlling pain following PRK.³ The pain-relieving effects, re-epithelialization, and complications may vary between topical NSAIDs.²⁵ Corneal melting has been reported after topical NSAID therapy, especially with Diclofenac drops.^{26,27} This issue usually occurs in cases treated without corticosteroid eye drops. No case of delayed

epithelial healing or corneal melting was observed in our series.

The cycloplegics, by relieving ciliary spasm, have a well-established effect on decreasing pain and discomfort in corneal lesions.^{12,13,28} Although our pilot study showed less pain and discomfort with Homatropine, results of the current study showed that Diclofenac is significantly superior to Homatropine for reducing pain after PRK.

Visual analogue score, verbal pain rating scale, and McGill pain rating index were used to evaluate subjective pain experience. Although VAS and PRI have been used frequently in studies to evaluate pain discomfort severity, Keele's verbal rating scale for pain has scarcely been used, and this enhances the quality of measurements.^{16,17} In our study, each eye was compared with the fellow eye. Evaluation of the pain severity in either eye might be influenced by the pain experience in the other eye. Therefore, the pain scores in this study might be different if Homatropine and Diclofenac eyes were selected from different individuals.

In conclusion, this study showed that Diclofenac is more effective than Homatropine for reducing post-PRK pain and discomfort. Although cycloplegics are cheap and safe without known deleterious effects on wound healing, their pain-relieving effects should be studied further. Other cycloplegic drugs with different cycloplegic durations might be more effective and convenient to use.

Funding

None of the authors has any financial interest in the subject matter of this paper.

References

- Cherry PM, Turtoo MK, Adhikary H, et al. The treatment of pain following photorefractive keratectomy. *J Refract Corneal Surg.* 1994;10:S222–S225.
- Arshinoff SA, Mills MD, Haber S. Pharmacotherapy of photorefractive keratectomy. *J Cataract Refractive Surg.* 1996;22:1037–1044.
- Sher NA, Golben MR, Bond W, Trattler WB, Tauber S, Voirin TG. Topical bromfenac 0.09% vs. ketorolac 0.4% for the control of pain, photophobia, and discomfort following PRK. *J Refract Surg.* 2009;25:214–220.
- Assoaline M, Renard G, Arne JL, et al. Prospective randomized trial of topical soluble 0.1% diclofenac versus placebo for the control of pain following excimer laser photorefractive keratectomy. *Ophthalmic Surg Lasers.* 1998;29:365–374.
- Trattler W, McDonald M. Double-masked comparison of ketorolac tromethamine 0.4% versus nepafenac sodium 0.1% for postoperative healing rates and pain control in eyes undergoing surface ablation. *Cornea.* 2007;26:665–669.
- Colin J, Paquette B. Comparison of the analgesic efficacy and safety of nepafenac ophthalmic suspension compared with diclofenac ophthalmic solution for ocular pain and photophobia after excimer laser surgery: a phase II, randomized, double-masked trial. *Clin Ther.* 2006;28:527–536.
- Verma S, Corbett MC, Patmore A, Heacock G, Marsha II J. A comparative-study of the duration and efficacy of tetracaine 1% and bupivacaine 0.75% in controlling pain following photo refractive keratectomy (PRK). *Eur J Ophthalmol.* 1997;7:327–333.
- Shahinian Jr L, Jain S, Jager RD, Lin DT, Sanislo SS, Miller JF. Dilute topical proparacaine for pain relief after photorefractive keratectomy. *Ophthalmology.* 1997;104:1327–1332.
- Faktorovich EG, Basbaum AI. Effect of topical 0.5% morphine on postoperative pain after photorefractive keratectomy. *J Refract Surg.* 2010;25:1–8.
- Brown JH. Atropine, scopolamine and related antimuscarinic drugs. In: Gilman AG, Rall TW, Nie AS, et al., eds. *Goodman and Gilman's the Pharmacological Basis of Therapeutics.* New York: McGraw and Hill; 1993 [chapter 8].
- Snell Richard S, Lemp Michel A. *Clinical Anatomy of the Eye.* 2nd ed. Wiley; 1997:182.
- Janda AM. Ocular trauma. Triage and treatment. *Postgrad Med.* 1991;90:51–52, 55–60.
- Nishimoto JY. Iritis. How to recognize and manage a potentially sight-threatening disease. *Postgrad Med.* 1996;99:255–257, 261–2.
- Joshaghani M, Nazari H, Ghasemi Falavarjani K, et al. Effect of homatropine eye drops on pain control after photorefractive keratectomy, a pilot study. *Saudi J Ophthalmol.* 2013;27:83–85.
- Grant S, Aitchison T, Henderson E, et al. A comparison of the reproducibility and the sensitivity to change of visual analogue scales, Borg scales, and Likert scales in normal subjects during submaximal exercise. *Chest.* 1999;116:1208–1217.
- Ponce de Leon S, Lara-Muñoz C, Feinstein AR, Wells CK. A comparison of three rating scales for measuring subjective phenomena in clinical research. II. Use of experimentally controlled visual stimuli. *Arch Med Res.* 2004;35:157–162.
- Malecaze FA, Deneuve SF, Julia BJ, et al. Pain relief with intracameral mepivacaine during phacoemulsification. *Br J Ophthalmol.* 2000;84:171–174.
- Vetrugoo M, Maineo A, Quaranta GM, Cardia L. A randomized, double-masked, clinical study of the efficacy of four nonsteroidal anti-inflammatory drugs in pain control after excimer laser photorefractive keratectomy. *Gin Ther.* 2000;22:719–731.
- Melzac KR. The McGill pain questionnaire: major properties and scoring methods. *Pain.* 1975;1:277–299.
- Ambrosio Jr R, Wilson S. LASIK vs LASEK vs PRK: advantages and indications. *Semin Ophthalmol.* 2003;18:2–10.
- Ghadhfan F, Al-Rajhi A, Wagoner MD. Laser in situ keratomileusis versus surface ablation: visual outcomes and complications. *J Cataract Refract Surg.* 2007;33:2041–2048.
- Trattler WB, Barnes SD. Current trends in advanced surface ablation. *Curr Opin Ophthalmol.* 2008;19:330–334.
- El-Maghraby A, Salah T, Waring 3rd GO, Klyce S, Ibrahim O. Randomized bilateral comparison of excimer laser in situ keratomileusis and photorefractive keratectomy for 2.50 to 8.00 diopters of myopia. *Ophthalmology.* 1999;106:447–457.
- Nissman SA, Tractenberg RE, Babbar-Goel A, Pasternak JF. Oral gabapentin for the treatment of postoperation pain after photorefractive keratectomy. *Am J Ophthalmol.* 2008;145:624–629.
- Durrie DS, Kennard MG, Boghossian AJ. Effects of nonsteroidal ophthalmic drops on epithelial healing and pain in patients undergoing bilateral photorefractive keratectomy (PRK). *Adv Ther.* 2007;24:1278–1285.
- Flach AJ. Corneal melts associated with topically applied nonsteroidal anti-inflammatory drugs. *Trans Am Ophthalmol Soc.* 2001;99:205–210.
- Gabison EE, Chastang P, Menashi S, et al. Late corneal perforation after photorefractive keratectomy associated with topical diclofenac: involvement of matrix metalloproteinases. *Ophthalmology.* 2003;110:1626–1631.
- Wilson SA, Last A. Management of corneal abrasions. *Am Fam Physician.* 2004;70:123–128.