

REVIEW

Open Access

# Spontaneous closure of macular holes secondary to posterior uveitis: case series and a literature review

Nicolas Bonnin<sup>1\*</sup>, Pierre-Loïc Cornut<sup>2</sup>, Florian Chaise<sup>2</sup>, Elodie Labeille<sup>2</sup>, Helene Janin Manificat<sup>2</sup>, Audrey Feldman<sup>2</sup>, Laurent Perard<sup>3</sup>, Franck Bacin<sup>1</sup>, Frédéric Chiambaretta<sup>1</sup> and Carole Burillon<sup>2</sup>

## Abstract

The occurrence of a macular hole due to posterior uveitis is infrequently reported. We report the evolution of three cases of macular holes secondary to posterior segment inflammation. A complete inflammatory and infectious assessment found one case of toxocarasis, one of sarcoidosis, and one of syphilis. After medical etiological treatment, macular hole closure was rapidly obtained in all the cases and confirmed by spectral domain optical coherence tomography, with visual acuity improvement. Fibrous scarring developed in two cases, and foveal photoreceptor complex normalization was observed in the sarcoidosis case. These observations demonstrate that macular holes secondary to posterior uveitis frequently resolve without surgical intervention and so could be underdiagnosed if the patient is not evaluated at the time of onset before spontaneous hole closure.

**Keywords:** Posterior uveitis, Macular hole, *Toxocara canis*, Sarcoidosis, Syphilis

## Review

### Introduction

Ocular inflammatory diseases can cause sight loss by macular impairment. Cystoid macular edema is the principal sight-threatening complication [1] in uveitis patients. Among possible macular inflammatory alterations, Nussenblatt describes macular hole occurrence as a very rare complication [2], being more often idiopathic or senile, postoperative or due to an epiretinal membrane, but rarely to posterior segment inflammation.

Here we report three cases of macular hole secondary to posterior uveitis that spontaneously resolved after etiological treatment, and present a review of relevant literature. Written informed consent was obtained from all patients for publication of this report.

### Case no. 1

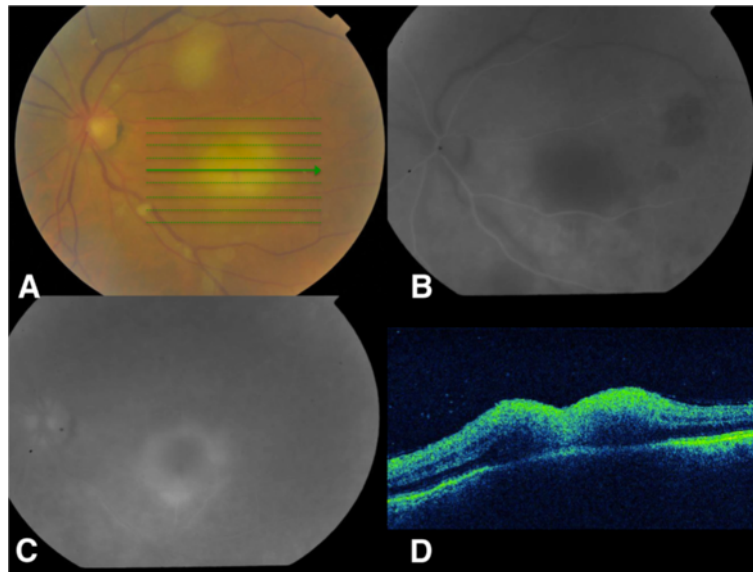
A 58-year-old farmer presented for a sudden deterioration of visual acuity in his left eye. His visual acuity was

20/40 in his right eye and counting fingers in his left eye. Full examination of the right eye showed cataract. In the left eye, slit-lamp examination showed a slight Tyndall effect with small keratic precipitates. Ocular pressure was normal, and fundus examination showed a mild diffuse hyalitis with numerous vitreous aggregates (at the top of the macula and along the vessels) overlying a yellowish macular lesion estimated at two papillary diameters. It was not pigmented (Figure 1A). Fluorescein angiography showed a centripetal impregnation of the macular lesion (Figure 1B,C) as seen in toxoplasmosis infections [3], and a subclinical temporal hypofluorescent area in addition to the macular retinochoroidal lesion. Indocyanine green (ICG) angiography showed a late impregnation of the margins of the lesion. Spectral domain optical coherence tomography (SD-OCT) assessment showed a thickened hyper-reflective retina and an inverted curvature of the posterior pole, showing probable concomitant impairment of the choroid and confirming the diagnosis of chorioretinitis (Figure 1D). The Goldmann-Witmer coefficient was positive for *Toxocara canis*, and albendazole was given to the patient for 2 weeks. At the end of the treatment, the OCT

\* Correspondence: nicoasmo@yahoo.fr

<sup>1</sup>Service d'Ophtalmologie, Pôle Médecine Interne-Ophtalmologie-ORL, CHU Clermont-Ferrand, Clermont-Ferrand 63003, France

Full list of author information is available at the end of the article

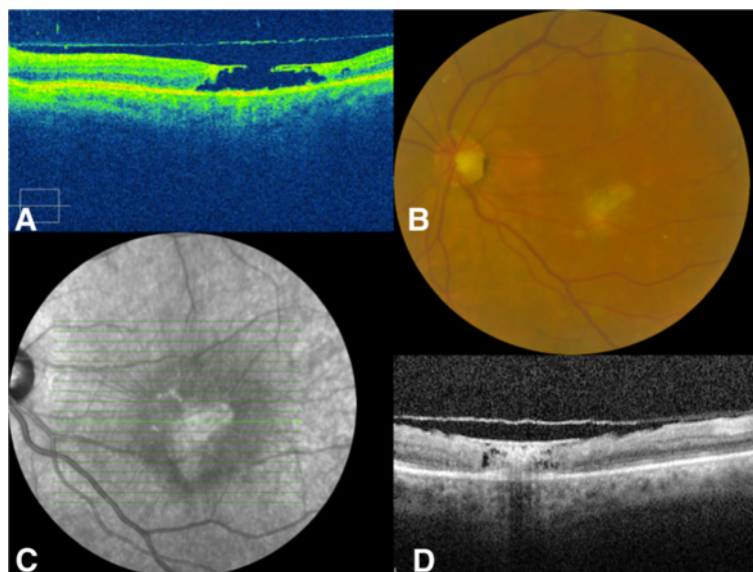


**Figure 1 Case 1, eye examination results before treatment.** (A) Retinophotography of the right eye: mild diffuse vitritis, vitreous aggregates (at the top of the macula and along the vessels), and macular chorioretinitis focus. (B, C) Fluorescein angiography of the right eye: centripetal impregnation of the macular lesion and temporal subclinical hypofluorescent area. (D) SD-OCT of the right eye: thickened hyper-reflective retina and inverted curvature of the posterior pole showing choroid impairment.

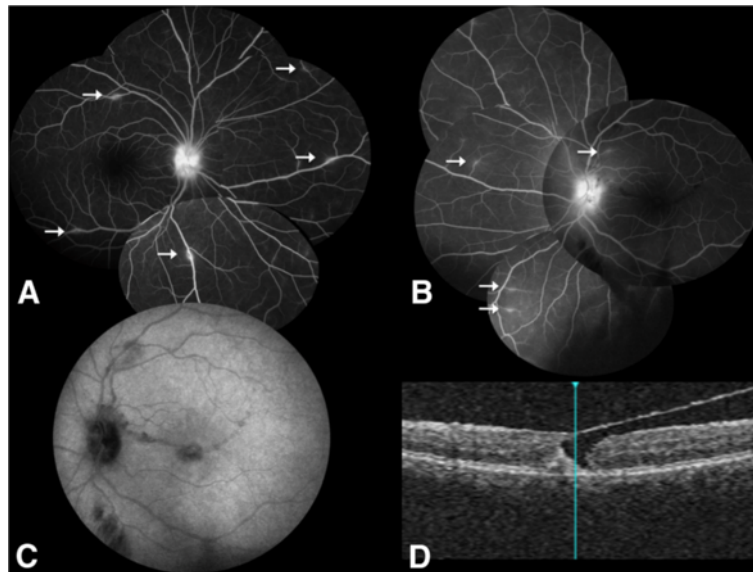
displayed the appearance of a stage III macular hole (also evident at fundus examination), as the posterior hyaloid was detached from the fovea (Figure 2A). After a 6-month follow-up, the macular hole had spontaneously resolved, filled by fibrous scar tissue associated with an epiretinal membrane (Figure 2B,C,D). The final visual acuity in the left eye was 20/100 after a 3-year follow-up.

#### Case no. 2

A 28-year-old woman presented for sight loss in her left eye. Her visual acuity was 20/20 in her right eye and 20/100 in her left eye. Anterior chamber examination showed granulomatous keratic precipitates in the left eye but no Tyndall effect. Fundus examination showed bilateral optic disc edema and a macular hole on the left.



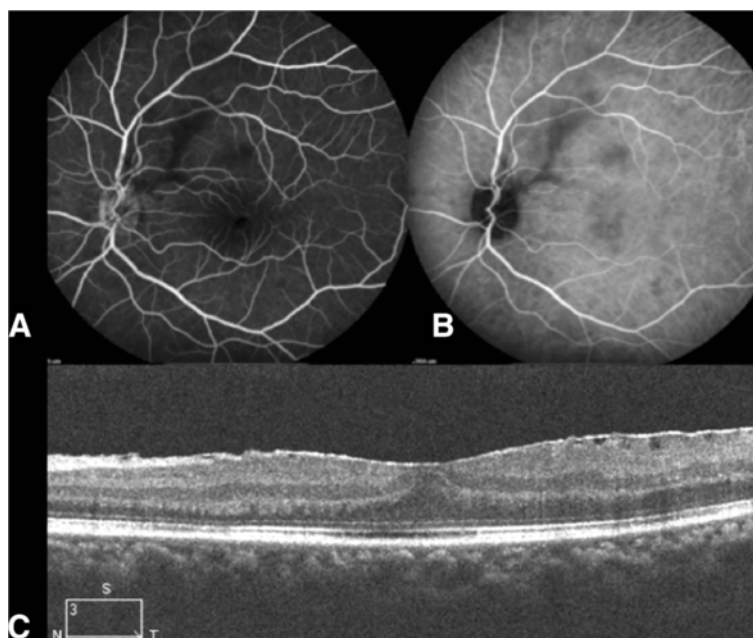
**Figure 2 Case 1, eye examination results after treatment.** (A) SD-OCT of the right eye: stage III macular hole. (B) Retinophotography of the right eye: a fibrous closure associated with an epiretinal membrane, spontaneously developed. (C) Red-free photography showing large macular fold due to fibrosis. (D) SD-OCT of the right eye: closure of the macular hole, filled with fibrosis.



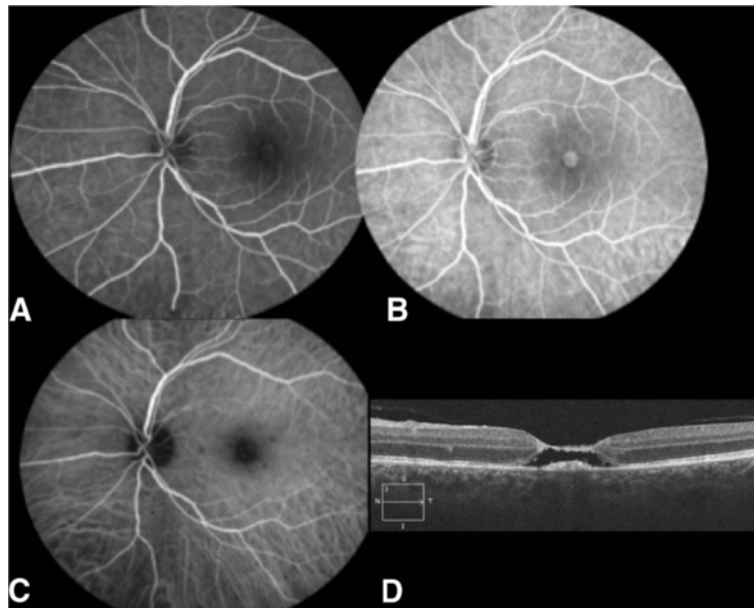
**Figure 3 Case 2, eye examination results before treatment.** (A, B) Fluorescein angiography of both eyes: bilateral optic disc edema and phlebitis (arrows). (C) Both fluorescein angiography and ICG angiography show hypofluorescent linear lesions in the macular area. (D) Macular SD-OCT of the left eye: pseudo hole.

Fluorescein angiography confirmed the bilateral optic nerve head diffusion and showed bilateral phlebitis (Figure 3A,B). Both fluorescein angiography and ICG angiography show hypofluorescent linear lesions in the macular area (Figure 3C). SD-OCT confirmed the presence of a pseudo macular hole (Figure 3D). The

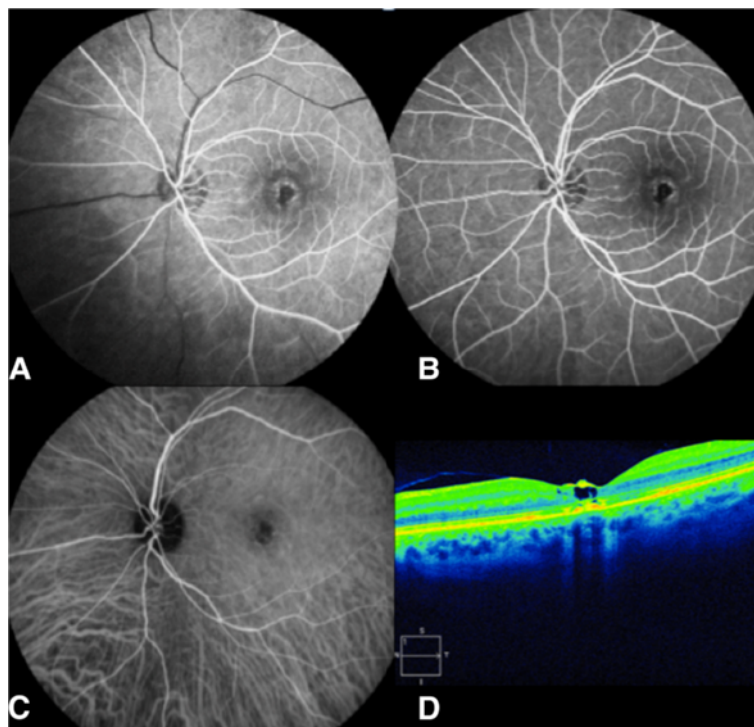
diagnosis workup was positive for sarcoidosis: increase in the angiotensin-converting enzyme to 160 U/L, mediastinal adenopathies on the computed tomography, increased rate of CD4/CD8 lymphocyte level in broncho-alveolar lavage, and multiple epithelioid and gigantocellular granuloma without caseous necrosis in



**Figure 4 Case 2, eye examination results after treatment.** (A, B) Fluorescein angiography of the left eye: healing of the optic disc edema and vascularitis. (C) Macular SD-OCT of the left fundus: closure of the macular hole promoted by the posterior hyaloid release and development of an epiretinal membrane.



**Figure 5 Case 3, eye examination results before treatment.** (A, B) Fluorescein angiography of the left eye: macular window effect. (C) Indocyanine green angiography of the left eye: multiple hypofluorescent parafoveal chorioretinitis foci. (D) Macular SD-OCT of the left eye: macular hole.



**Figure 6 Case 3, eye examination results after treatment.** (A, B) Fluorescein angiography of the left eye: macular RPE alterations. (C) Indocyanine green angiography of the left eye: healing of the chorioretinitis foci. (D) Macular SD-OCT of the left fundus: closure of hole with some cystoid alterations remaining.

**Table 1 Review of the literature of macular holes in a context of intraocular inflammation**

Etiology	Number of cases	Study
Behcet's disease	35	[5-11]
Idiopathic intermediate uveitis	4	[9,12]
Idiopathic posterior uveitis	2	[9]
<i>Bartonella henselae</i>	2	[13,14]
Toxoplasmosis	2	[15,16]
Vogt-Koyanagi-Harada	2	[17]
CMV retinitis	1	[9]
HLA B27	1	[18]
Bilateral idiopathic anterior uveitis of unknown etiology	1	[19]
Serpiginous choroiditis	1	[20]
Fungal endophthalmitis	1	[21]
T/NK lymphoma	1	[22]
Presumed histoplasmosis	1	[23]
Immune recovery uveitis in AIDS patients with CMV retinitis	1	[24]

analysis of bronchial biopsies. A prednisolone treatment at 1 mg/kg was given. After a 3-month follow-up, the visual acuity had increased to 20/25 in the left eye. Fundus examination and fluorescein angiography showed bilateral healing of the optic disc edema and vascularitis (Figure 4A,B). SD-OCT showed closure of the macular hole with normalization of the foveal photoreceptor layer and the development of an epiretinal membrane (Figure 4C). Examination remained stable after a 3-year follow-up.

**Case no. 3**

A 39-year-old man was referred for a 2-day loss of visual acuity in his left eye. This patient had a medical history of hepatitis C infection, human immunodeficiency infection with normal T lymphocyte count and undetectable

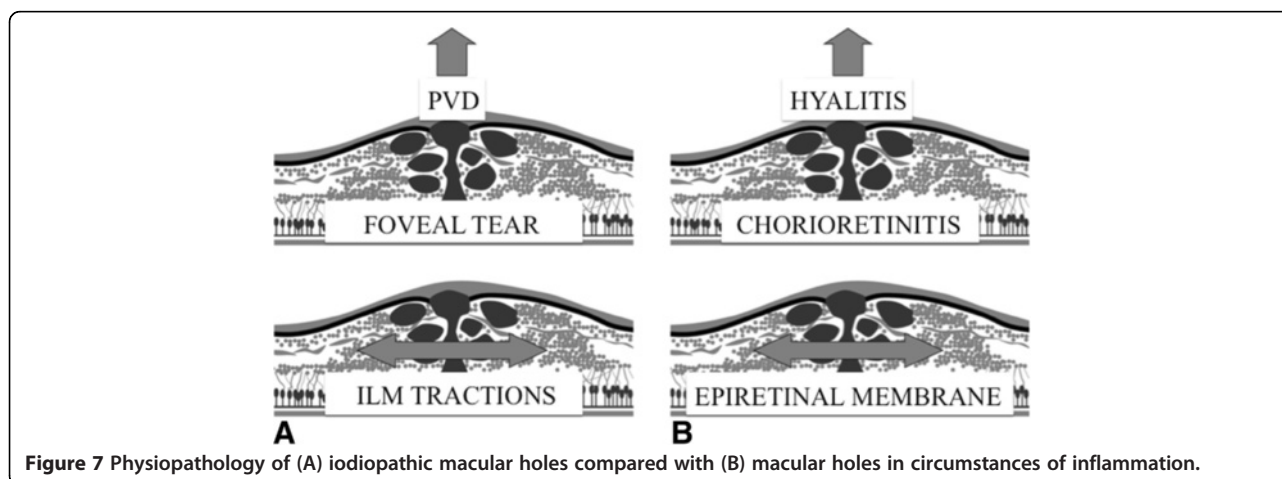
viral load, and a known evolutive syphilis infection. Being allergic to penicillin, he had been treated using oral tetracycline for several months with no decrease in serum *Treponema pallidum* hemagglutination assay-Venereal Disease Research Laboratory (TPHA-VDRL). His visual acuity was 20/20 in his right eye and counting fingers in his left eye. Slit-lamp examination showed a mild Tyndall effect in the anterior chamber and a macular hole (Figure 5A,B). Fluorescein angiography showed the macular hole; indocyanine green angiography revealed multiple hypofluorescent parafoveal chorioretinitis foci (Figure 5C), and SD-OCT confirmed the hole (Figure 5D). A complete inflammatory and infectious assessment found only increased serum TPHA-VDRL. The patient was treated by intravenous ceftriaxone at 2 g/day for 1 week and then at 1 g/day for a further week. One month after treatment, the angiography showed healing of the chorioretinitis foci (Figure 6A,B,C). After a 2-year follow-up, visual acuity had increased to 20/40, and the OCT showed a subtotal closure of the macular hole with some cystoid alterations remaining (Figure 6D).

**Discussion**

Intraocular inflammatory diseases have long been described as a major cause of blindness [1]. In all kinds of uveitis, bilateral legal blindness develops in 4% of patients, unilateral blindness in 14%, bilateral visual impairment in 6%, unilateral impairment in 11%, and unilateral impairment with blindness of the other eye in 4% to 5%.

The occurrence of a macular hole in a context of uveitis is an unusual, little-described complication.

In 1986, Nussenblatt [2] studying macular alterations in uveitic patients described this evolution as 'uncommon'. Later, in a retrospective study of 582 patients with uveitis [1], no macular hole was described. Neither prevalence nor incidence of macular holes linked to posterior segment inflammation can be established from the literature, cases or short series being too scant.



**Figure 7 Physiopathology of (A) idiopathic macular holes compared with (B) macular holes in circumstances of inflammation.**

On the other hand, in a histopathological study of 17 lamellar and 18 full-thickness macular holes [4], mild to moderate choroiditis was present in six eyes in the macular area. One of these cases was suspected of being an incidental finding because the choriocapillaris, Bruch's membrane, and the retinal pigment epithelium (RPE) were intact. This study gives us an approximate figure for the proportion of macular holes linked to posterior uveitis in all macular holes. However, there is a selection bias: the eyes of this study were obtained from enucleations or post-mortem, so the results do not reflect the general epidemiology of the disease.

The literature reports 55 cases of macular hole secondary to posterior uveitis (Table 1): 35 Behcet's disease [5-11], 3 idiopathic intermediate uveitis [9], 2 idiopathic posterior uveitis [9], 1 bilateral intermediate uveitis [12], 2 *Bartonella henselae* [13,14], 2 toxoplasmosis [15,16], 2 Vogt-Koyanagi-Harada [17], 1 cytomegalovirus (CMV) retinitis [9], 1 HLA B27 uveitis [18], 1 bilateral anterior uveitis [19], 1 serpiginous choroiditis [20], 1 fungal endophthalmitis [21], 1 T/natural killer (NK) lymphoma [22], 1 presumed histoplasmosis [23], and 1 immune recovery uveitis in an AIDS patient after CMV retinitis [24].

Idiopathic macular holes can be explained by a triple constraint [25]: (1) an antero-posterior traction, often effected by the posterior vitreous detachment; (2) a tangential traction especially when there is an epiretinal membrane or a lateral shifting of vitreoretinal adherence; and (3) an intraretinal constraint that weakens the inner retinal surface by inducing cystic changes and contributes to the macular hole (Figure 7A). A parallel can be done in circumstances of posterior segment inflammation: the inflammation often induces changes or liquefaction of the vitreous body and contributes to the posterior vitreous detachment which realizes the first constraint. The development of an epiretinal membrane is classical in uveitis [26], responsible of a tangential traction, as seen in the cases 1 and 2. Finally, chorioretinitis foci or cystoid macular edema cause the third constraint, fragilizing the retinal tissue (Figure 7B). This explains why treating the inflammation can relieve these constraints or tractions and produce spontaneous healing of the macular hole. The report of Halkiadakis et al. [18] on a spontaneous macular hole closure after peribulbar steroid injection in the case of a HLA B27 uveitis demonstrates this well.

The relatively old references on the low prevalence of macular hole in uveitic patients could be explained by the fact that OCT is a recent tool. Our cases also show the importance of the SD-OCT in uveitis to confirm cystoid macular edema, the principal sight-threatening effect in uveitis [1]. OCT can also be a diagnostic criterion in some etiologies such as intermediate uveitis or a poor-prognosis marker as in Birdshot retinochoroidopathy, indicating a

specific care requirement. OCT is necessary during follow-up after resolution of active inflammation to seek the cause of any unexplained sight loss and may reveal a closed macular hole filled by fibrosis.

SD-OCT is useful for the preoperative evaluation of the inflammatory secondary epiretinal membrane to evaluate the benefits of the procedure: in our first case, in which an epiretinal membrane developed, there was a partial posterior vitreous detachment, and so there is a persistent risk of macular hole recurrence in a such damaged and weakened retina, with very small hope of visual improvement.

## Conclusion

The occurrence of a macular hole linked to posterior uveitis is an uncommon but possibly underestimated cause of sight loss. Etiological treatment seems to lead to macular hole closure in most such cases. SD-OCT is very useful for assessing the evolution of these cases and should be performed whenever there is a posterior involvement or unexplained sight loss in uveitis patients.

## Competing interest

The authors declare that they have no competing interests.

## Authors' contributions

NB wrote the manuscript, synthesized the cases, and made the literature review. PLC was the co-author; he corrected and directed the redaction of the manuscript and followed the cases. FC, EL, HJM, AF, and LP participated to the management of the cases and the diagnosis. FC, FB, and CB participated in the design of the study and its coordination. All authors read and approved the final manuscript.

## Acknowledgments

This paper was presented at the SFO (Société Française d'Ophtalmologie) 2011 Congress. We are grateful to ATT Medical Society for proofreading the manuscript.

## Author details

<sup>1</sup>Service d'Ophtalmologie, Pôle Médecine Interne-Ophtalmologie-ORL, CHU Clermont-Ferrand, Clermont-Ferrand 63003, France. <sup>2</sup>Department of Ophthalmology, Hospices Civils de Lyon, University Hospital, Claude Bernard Lyon I University, Lyon 69008, France. <sup>3</sup>Department of Internal Medicine, Edouard-Herriot Hospital, place d'Arsonval, Lyon 69008, France.

Received: 31 August 2012 Accepted: 25 January 2013

Published: 11 February 2013

## References

1. Rothova A, Suttorp-van Schulten MS, Frits Treffers W, Kijlstra A (1996) Causes and frequency of blindness in patients with intraocular inflammatory disease. *Br J Ophthalmol* 80:332-336
2. Nussenblatt RB (1986) Macular alterations secondary to intraocular inflammatory disease. *Ophthalmology* 93:984-988
3. Delair E, Brezin AP (2010) Ocular toxoplasmosis. Uveitis. Annual report of the French Ophthalmology Society. Paris, Elsevier Masson, In, pp 201-220
4. Frangieh GT, Green WR (1981) Engel HM (2005) A histopathologic study of macular cysts and holes. *Retina* 25:311-336
5. Angioi-Duprez K, Maalouf T, Gerin M, George JL (2001) A full thickness macular hole as an uncommon complication of Behcet disease. *J Fr Ophtalmol* 24:172-174
6. Benchekroun O, Lahbil D, Lamari H, Rachid R, El Belhadji M, Laouissi N, Zaghoul K, Benamour S, Amraoui A (2004) Macular damage in Behcet's disease. *J Fr Ophtalmol* 27:154-159

7. Georgalas I, Markomichelakis N, Ladas I (2008) Retinal detachment due to a macular hole in a patient with Behcet disease treated with vitrectomy and silicone oil tamponade. *Eur J Ophthalmol* 18:1023–1024
8. Sheu SJ, Yang CA (2004) Macular hole in Behcet's disease. *Kaohsiung J Med Sci* 20:558–562
9. Woo SJ, Yu HG, Chung H (2010) Surgical outcome of vitrectomy for macular hole secondary to uveitis. *Acta Ophthalmol* 88:e287–288
10. Kahloun R, Ben Yahia S, Mbarek S, Attia S, Zaouali S, Khairallah M (2012) Macular involvement in patients with Behcet's uveitis. *J Ophthalmic Inflamm Infect* 2:121–124
11. Al-Dhibi H, Abouammoh M, Al-Harhi E, Al-Gaeed A, Larsson J, Abboud E, Chaudhry I (2011) Macular hole in Behcet's disease. *Indian J Ophthalmol* 59:359–362
12. Shukla D, Dhawan A (2011) Pharmacotherapeutic closure of a uveitic macular hole persisting after vitrectomy. *Indian J Ophthalmol* 59:335–336
13. Donnio A, Jean-Charles A, Merle H (2008) Macular hole following *Bartonella henselae* neuroretinitis. *Eur J Ophthalmol* 18:456–458
14. Albin TA, Lakhanpal RR, Foroozan R, Holz ER (2005) Macular hole in cat scratch disease. *Am J Ophthalmol* 140:149–151
15. Atmaca LS, Simsek T, Batioglu F (2004) Clinical features and prognosis in ocular toxoplasmosis. *Jpn J Ophthalmol* 48:386–391
16. Blaise P, Comhaire Y, Rakic JM (2005) Giant macular hole as an atypical consequence of a toxoplasmic chorioretinitis. *Arch Ophthalmol* 123:863–864
17. Kobayashi I, Inoue M, Okada AA, Keino H, Wakabayashi T, Hirakata A (2008) Vitreous surgery for macular hole in patients with Vogt-Koyanagi-Harada disease. *Clin Experiment Ophthalmol* 36:861–864
18. Halkiadakis I, Pantelia E, Giannakopoulos N, Koutsandrea C, Markomichelakis NN (2003) Macular hole closure after peribulbar steroid injection. *Am J Ophthalmol* 136:1165–1167
19. Shukla D, Dhawan A (2010) Evolution and management of a post-uveitis macular hole. *Ophthalmic Surg Lasers Imaging* 9:1–3
20. Gregory ME, Bhatt U, Benskin S, Banerjee S (2009) Bilateral full thickness macular holes in association with serpiginous choroiditis. *Ocul Immunol Inflamm* 17:328–329
21. Kusaka S, Hayashi N, Ohji M, Ikuno Y, Gomi F, Tano Y (2003) Macular hole secondary to fungal endophthalmitis. *Arch Ophthalmol* 121:732–733
22. Hon C, Kwok AK, Shek TW, Chim JC, Au WY (2002) Vision-threatening complications of nasal T/NK lymphoma. *Am J Ophthalmol* 134:406–410
23. Baskin MA, Jampol LM, Huamonte FU, Rabb MF, Vygantas CM, Wyhinny G (1980) Macular lesions in blacks with the presumed ocular histoplasmosis syndrome. *Am J Ophthalmol* 89:77–83
24. Arevalo JF, Mendoza AJ, Ferretti Y (2003) Immune recovery uveitis in AIDS patients with cytomegalovirus retinitis treated with highly active antiretroviral therapy in Venezuela. *Retina* 23:495–502
25. Smiddy WE, Flynn HW Jr (2004) Pathogenesis of macular holes and therapeutic implications. *Am J Ophthalmol* 137:525–537
26. Nazari H, Dustin L, Heussen FM, Sadda S, Rao NA (2012) Morphometric spectral-domain optical coherence tomography features of epiretinal membrane correlate with visual acuity in patients with uveitis. *Am J Ophthalmol* 154(78–86):e71

doi:10.1186/1869-5760-3-34

**Cite this article as:** Bonnin et al.: Spontaneous closure of macular holes secondary to posterior uveitis: case series and a literature review. *Journal of Ophthalmic Inflammation and Infection* 2013 3:34.

**Submit your manuscript to a SpringerOpen<sup>®</sup> journal and benefit from:**

- Convenient online submission
- Rigorous peer review
- Immediate publication on acceptance
- Open access: articles freely available online
- High visibility within the field
- Retaining the copyright to your article

Submit your next manuscript at ► [springeropen.com](http://springeropen.com)