



## Traction-assisted endoscopic submucosal dissection for a previously tattooed colonic laterally spreading tumor

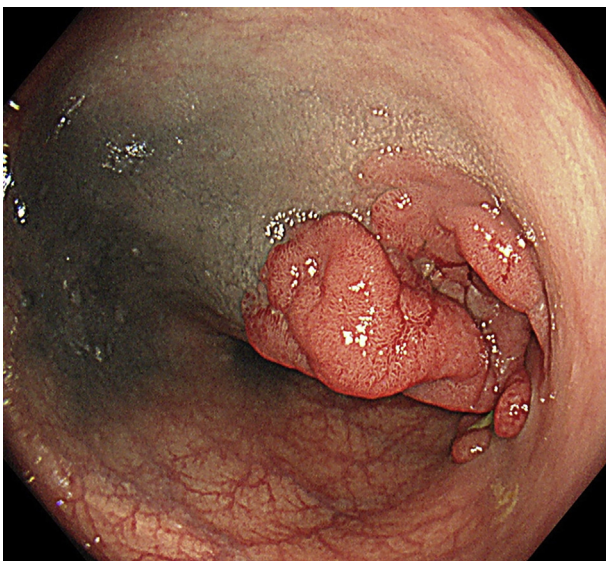
Gota Sudo, MD,<sup>1,2</sup> Tokuma Tanuma, MD, PhD,<sup>3</sup> Takashi Fujisawa, MD, PhD,<sup>4</sup> Yuji Hinoda, MD, PhD,<sup>1</sup> Hiroshi Nakase, MD, PhD<sup>2</sup>

Endoscopic tattooing is widely performed for preoperative marking; however, colorectal endoscopic submucosal dissection (ESD) after tattooing is challenging because of the dark endoscopic visual field and severe fibrosis at the submucosa.<sup>1-4</sup> Previous studies have demonstrated the efficacy of the traction method in colorectal ESD.<sup>5,6</sup> Moreover, recent reports have described traction-assisted ESD for technically challenging colorectal cases, such as those involving the appendiceal orifice or diverticulum.<sup>7,8</sup> We have developed the multiloop (M-loop) method, a traction technique using silk thread and clips, and reported its efficacy.<sup>9-11</sup> Compared with other traction methods, the M-loop has several advantages: (1) It is easy to make within a few minutes at any institution; (2) there is no need to reinsert the endoscope; (3) it is cost efficient; and (4) application can be made in segments with a large lumen by adjusting the number or size of loops. When the traction slackens during dissection, we can strengthen it by adding a new clip between the knot and reattaching to the contralateral wall. We herein present a case of colonic laterally spreading tumor (LST) after tattooing, which was successfully treated by traction-assisted ESD using M-loop.

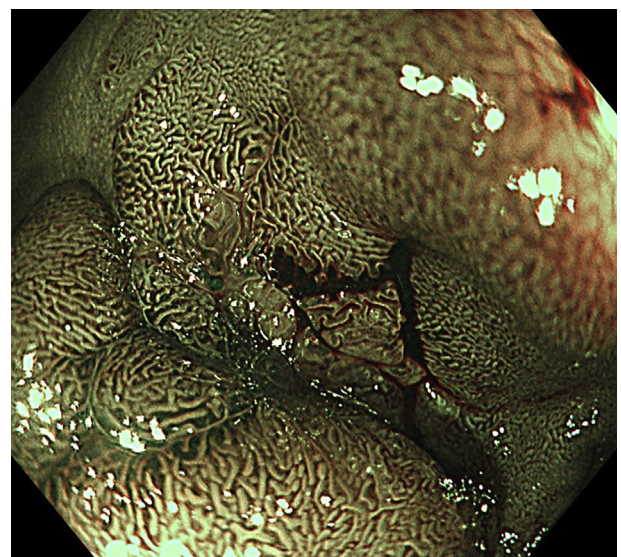
A 73-year-old man without any remarkable medical history was referred to our department for further investigation of a colonic LST. Colonoscopy revealed a 35-mm nongranular-type LST in the sigmoid colon, and the lesion had been tattooed for marking at the previous hospital (Fig. 1). Magnifying endoscopy with narrow-band imaging showed an irregular surface and vessel patterns at the center of the lesion, which suggested intramucosal or slightly invasive cancer (Fig. 2). He underwent ESD (Video 1, available online at [www.giejournal.org](http://www.giejournal.org)).

An M-loop was prepared in the same manner as previously reported.<sup>9-11</sup> Briefly, a 3-0 silk thread was tied to a 2.5-mL syringe (Fig. 3A). We then reeled the thread back around to tie a second knot, and the redundant thread was trimmed (Fig. 3B). The M-loop was attached to the base of a clip and housed in the delivery sheath (Fig. 3C and D). Using a transparent hood (DH-30CR; Fujifilm, Tokyo, Japan) and Hook Knife (KD-625QR; Olympus, Tokyo, Japan), we started mucosal incision and submucosal dissection from the nonpigmented site.

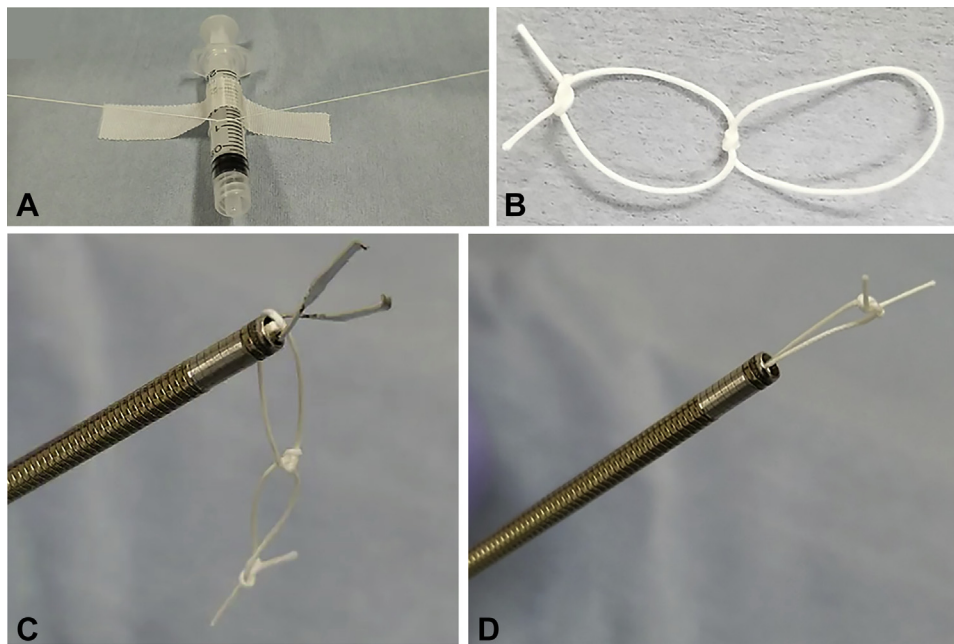
On the pigmented site, black discoloration of the submucosa induced by tattooing was observed, which made



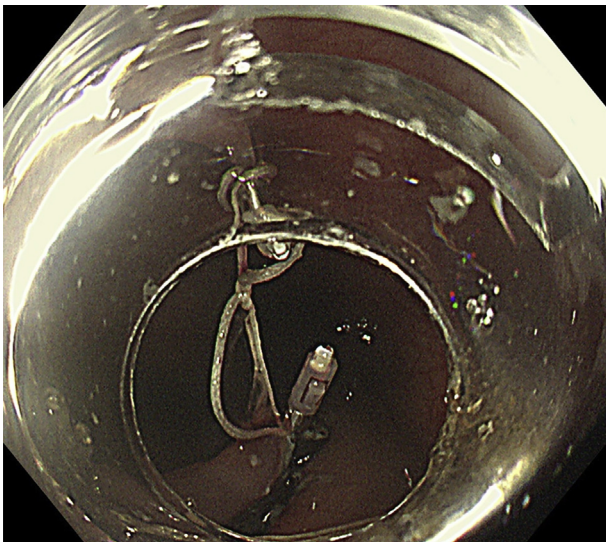
**Figure 1.** Endoscopic image of a nongranular-type laterally spreading tumor at the tattooed sigmoid colon.



**Figure 2.** Endoscopic image of the center of the lesion observed by magnifying endoscopy with narrow-band imaging.



**Figure 3.** The preparation of the M-loop. **A**, The thread is tied to a 2.5-mL syringe to make a loop. **B**, After repeating this process, M-loop with double loops is made. **C, D**, The M-loop is hooked onto a clip and housed in the delivery sheath.



**Figure 4.** Endoscopic image after the attachment of multiloop to the pigmented site.

identification of the appropriate dissection line difficult. Therefore, we used the traction technique with M-loop. The M-loop was introduced into the colorectal lumen through the working channel and attached to the edge of the lesion. We then clipped the free end of the loop to the contralateral wall using another clip (Fig. 4). This provided sufficient tension and a better visual field to perform the procedure safely (Fig. 5A and B). En bloc resection was successfully achieved (Fig. 6A and B), and we cut the M-loop with the same endosurgical knife used for dissection. The clip on the contralateral wall is usually

left and will not cause any adverse events. The patient was discharged uneventfully. Histopathologic examination revealed intramucosal cancer with tubulovillous adenoma, and lateral and vertical margins were negative (Fig. 7). Deposition of India ink was observed in the submucosa, but submucosal fibrosis was mild (Fig. 8).

In the current case, histopathologic examination did not show severe fibrosis, unlike in previous reports.<sup>1-4</sup> This suggested that fibrosis may not have significantly affected the procedure in our case. However, we were unable to confirm the depth of dissection planes at the pigmented site because black discoloration caused by tattooing extended to just above the muscularis propria. During submucosal dissection, endoscopists generally confirm the depth of dissection planes by identifying the muscularis propria through the injected submucosa. However, black discoloration of the submucosa prevents this, resulting in an increased risk of perforation or cutting into the lesion.

To overcome such a condition, previous reports have proposed several strategies. Chiba et al<sup>2</sup> reported that ESD should be initiated from the nonpigmented site and performed at a moderate distance from the muscle layer to image the accurate line of the muscle layer. Jawaid et al<sup>3</sup> reported a case of rectal LST after tattooing treated by ESD with a tissue retractor system. Another report by Ramos-Zabala et al<sup>4</sup> described a “trans-tattoo in immersion” method that provided clear vision by using a water immersion technique and improved the dissection process even in previously tattooed areas.

In our case, in addition to starting the procedure from the nonpigmented site, we used a traction technique using M-loop. Usage of the M-loop does not differ between

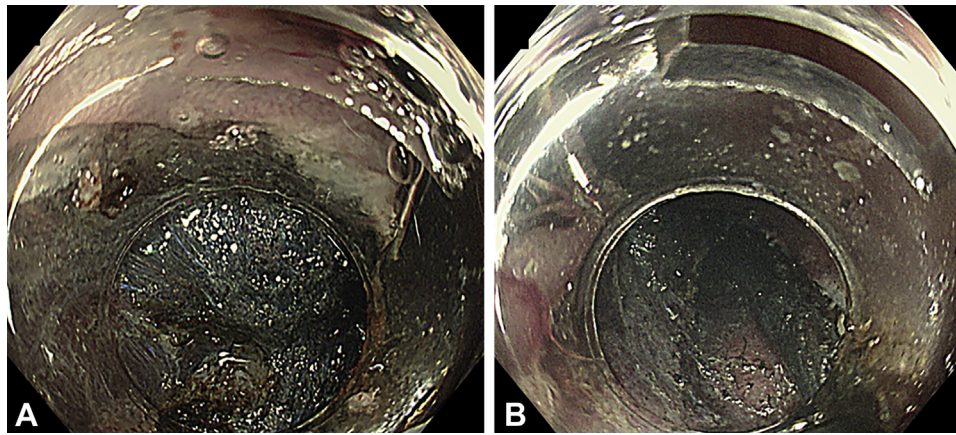


Figure 5. A, B, Endoscopic images during traction-assisted submucosal dissection of the tattooed site.

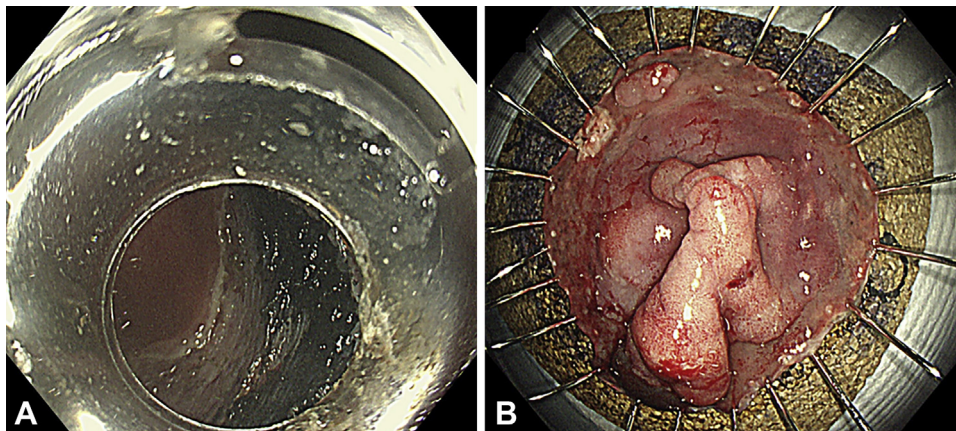


Figure 6. Postendoscopic submucosal dissection ulcer (A) and en bloc resection specimen (B) immediately after the procedure.

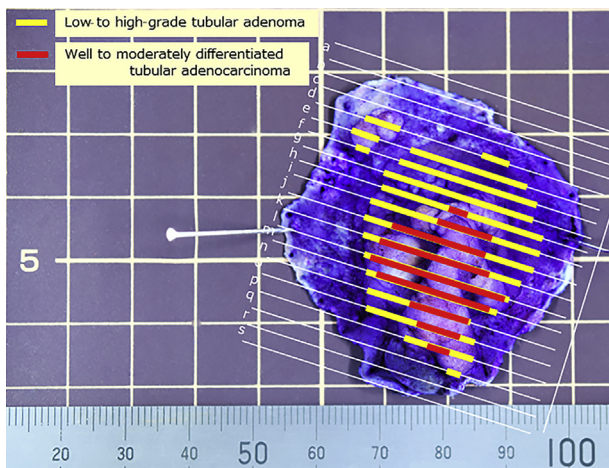


Figure 7. Macroscopic image of the resected specimen after formalin fixation.

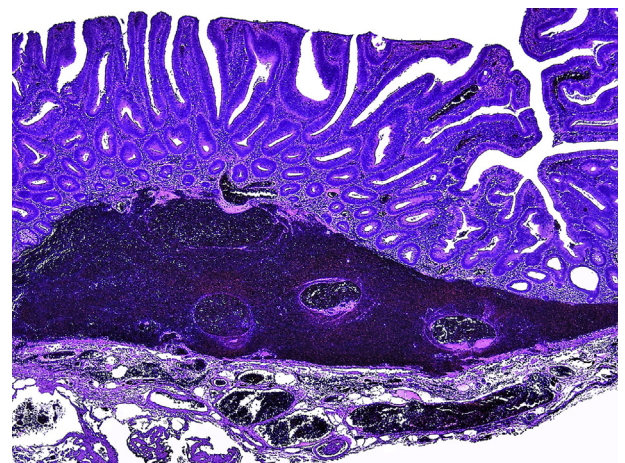


Figure 8. Histopathologic image of the colonic laterally spreading tumor accompanied by intramucosal hematoma and submucosal deposition of India ink with mild fibrosis.

tattooed and nontattooed lesions; however, it is important to manipulate the endoscope at a moderate distance in the tattooed lesion to allow identification of the dissection line

and safe en bloc resection. Traction-assisted colorectal ESD may be a useful option in difficult conditions after tattooing.

## DISCLOSURE

*All authors disclosed no financial relationships.*

Abbreviations: ESD, endoscopic submucosal dissection; LST, laterally spreading tumor; M-loop, multi-loop.

## ACKNOWLEDGMENTS

We would like to thank Editage ([www.editage.jp](http://www.editage.jp)) for English language editing. This study was supported in part by Grant-in-Aid for Young Investigators from Japan Society for Promotion of Science (JSPS KAKENHI 20K17057).

## REFERENCES

1. Ono S, Fujishiro M, Goto O, et al. Endoscopic submucosal dissection for colonic laterally spreading tumors is difficult after target tattooing. *Gastrointest Endosc* 2009;69:763-6.
2. Chiba H, Tachikawa J, Kurihara D, et al. Successful endoscopic submucosal dissection of colon cancer with severe fibrosis after tattooing. *Clin J Gastroenterol* 2017;10:426-30.
3. Jawaid S, Yang D, Draganov PV. Tissue retractor system-assisted endoscopic submucosal dissection of a large rectal tumor with significant fibrosis from direct tattooing. *VideoGIE* 2019;4:84-6.
4. Ramos-Zabala F, Gil-Páez C, Alzina-Pérez A, et al. "Trans-tattoo in immersion" method for the removal of a recurrent, previously tattooed adenoma using endoscopic submucosal hydrodissection. *Endoscopy* 2020;52:E408-10.
5. Ritsuno H, Sakamoto N, Osada T, et al. Prospective clinical trial of traction device-assisted endoscopic submucosal dissection of large superficial colorectal tumors using the S-O clip. *Surg Endosc* 2014;28:3143-9.
6. Yamasaki Y, Takeuchi Y, Uedo N, et al. Efficacy of traction-assisted colorectal endoscopic submucosal dissection using a clip-and-thread technique: a prospective randomized study. *Dig Endosc* 2018;30:467-76.
7. Chen HY, Yamada M, Saito Y. Successful removal of a serrated lesion involving the appendiceal orifice using a traction device. *Dig Endosc* 2019;31:333.
8. Iwatsubo T, Uedo N, Yamasaki Y, et al. Traction-assisted colorectal endoscopic submucosal dissection by use of clip and line for a neoplasm involving colonic diverticulum. *VideoGIE* 2017;2:337-8.
9. Sudo G, Tanuma T, Suzuki Y, et al. Multiloop method for traction during colorectal endoscopic submucosal dissection. *VideoGIE* 2018;4:11-3.
10. Suzuki Y, Tanuma T, Nojima M, et al. Multiloop as a novel traction method in accelerating colorectal endoscopic submucosal dissection. *Gastrointest Endosc* 2020;91:185-90.
11. Suzuki Y, Tanuma T, Nojima M, et al. Comparison of dissection speed during colorectal ESD between the novel multiloop (M-loop) traction method and ESD methods without traction. *Endosc Int Open* 2020;8:E840-7.

Department of Gastroenterology and Hepatology, Sapporo Teishinkai Hospital, Sapporo, Japan (1), Department of Gastroenterology and Hepatology, Sapporo Medical University School of Medicine, Sapporo, Japan (2), Department of Gastroenterology and Hepatology, Sapporo Central Hospital, Sapporo, Japan (3), Department of Pathology, Sapporo Teishinkai Hospital, Sapporo, Japan (4).

Copyright © 2021 American Society for Gastrointestinal Endoscopy. Published by Elsevier Inc. This is an open access article under the CC BY-NC-ND license (<http://creativecommons.org/licenses/by-nc-nd/4.0/>).

<https://doi.org/10.1016/j.vgie.2021.03.009>

### Twitter

Become a follower of *VideoGIE* on Twitter. Learn when new articles are posted and receive up-to-the-minute news as well as links to our latest videos. Search @VideoGIE on Twitter.