

3-Hydroxyisobutyryl-CoA Hydrolase (HIBCH) Deficiency Cases Diagnosed by Only HIBCH Gene Analysis and Novel Pathogenic Mutation

Nafiye Emel Çakar, Orhan Görükmez¹

University of Health Sciences, Okmeydanı Training and Research Hospital, Division of Pediatric Metabolism, Istanbul, ¹Bursa Yuksek Ihtisas Training and Research Hospital, Department of Genetics, Bursa, Turkey

Abstract

Objective: 3-Hydroxyisobutyryl-CoA hydrolase (HIBCH) deficiency is a rare metabolic disease of valine metabolism. Only 22 cases of HIBCH deficiency have been reported in the literature. Our algorithm could help in the diagnosis of this disease. **Methods:** HIBCH gene analysis was performed in all cases. **Results:** The common features of our five patients from the same family with a developmental delay, seizures, and neurological regression were the elevation of 3-hydroxy-isobutyryl-carnitine and Leigh-like abnormalities. Unlike other patients in the literature, our patients were diagnosed with HIBCH gene analysis, rather than whole exome sequencing (WES). In all our cases, a missense c.452C>T, p. Ser151Leu homozygous novel pathogenic mutation was detected in the HIBCH gene. **Conclusion:** In cases where HIBCH deficiency is considered in our differential diagnosis algorithm, HIBCH gene analysis, which is cost-effective, should be performed instead of WES, and the number of cases should be increased in the literature.

Keywords: HIBCH deficiency, hydroxy-C4 carnitine, Leigh-like disease, valine metabolism

INTRODUCTION

3-Hydroxyisobutyryl-Co-A hydrolase (HIBCH) deficiency (OMIM no. 250620) is an uncommon congenital metabolic disease caused by an HIBCH enzyme deficiency in valine catabolism [Figure 1].

It was first described in 1982 in a male infant with failure to thrive, hypotonia, and physical malformations (dysmorphic facial features, multiple vertebral anomalies, and tetralogy of Fallot).^[1] To date, 22 HIBCH deficiency cases from 13 families have been reported in the literature.^[2] In autosomal recessive inheritance, developmental delay, hypotonia, neurological regression, and seizures can be observed in early childhood. In the disease, a plasma lactate level increase, 3-hydroxy-isobutyryl-carnitine (hydroxy-C4 carnitine) elevation during acylcarnitine analysis, and a 3-hydroxy-isovaleric acid increase during urine organic acid analysis can be observed. On cranial MRI, Leigh-like signal abnormalities in the bilateral basal ganglia are remarkable. *HIBCH* gene analysis should be performed to confirm the diagnosis. However, the cases reported in the literature were diagnosed with whole exome sequencing (WES).

Our index case (case 1) was a 3.5-year-old female with developmental delay who was admitted to our institution due to status epilepticus. After the status epilepticus was controlled with antiepileptics, neurological and metabolic tests were planned. During metabolic examinations of the patient, hydroxy-C4 carnitine elevation and signal changes

in the basal ganglion (Leigh-like) were observed on cranial MRI. Her sister (case 2) also had developmental delay, and metabolic examinations and MRI were performed. Family screenings of the mother's siblings were performed, and MRI was performed with metabolic examinations (cases 3–5) [Table 1].

In these cases, hydroxy-C4 carnitine elevation in the acylcarnitine analysis and signal changes in the basal ganglia on MRI were observed.

With these findings, the cases were thought to be HIBCH deficiency. The index case was studied first, and then, *HIBCH* gene analysis of the other cases was performed. In the *HIBCH* gene, a novel pathogenic mutation compatible with missense c.452C>T, p.Ser151Leu homozygous HIBCH deficiency was detected.

Address for correspondence: Dr. Nafiye Emel Çakar, University of Health Sciences, Okmeydanı Training and Research Hospital, Division of Pediatric Metabolism, Istanbul, Turkey. E-mail: dremelyaman@gmail.com

Submitted: 19-Mar-2020 **Revised:** 30-Mar-2020 **Accepted:** 07-May-2020

Published: 14-Jul-2021

This is an open access journal, and articles are distributed under the terms of the Creative Commons Attribution-NonCommercial-ShareAlike 4.0 License, which allows others to remix, tweak, and build upon the work non-commercially, as long as appropriate credit is given and the new creations are licensed under the identical terms.

For reprints contact: reprints@medknow.com

DOI: 10.4103/aian.AIAN_192_20

In addition to the 22 HIBCH deficiency patients reported in the literature, we present 5 cases with a novel pathogenic mutation. HIBCH deficiency should be considered in the differential diagnosis of patients with similar clinical, laboratory, and radiological findings.

METHODS

Patients

Cases 1 and 2 were siblings, and their parents had a consanguineous marriage (cousins). Cases 3–5 were siblings, and their parents also had a consanguineous marriage (cousins) [Figure 2]. The ethnic origin of all cases was Syrian.

Acylcarnitine analysis

Acylcarnitine analysis was performed with electrospray ionization tandem mass spectrometry from dry blood spots from newborn screening cards.

Molecular analysis

To confirm the diagnosis, mutational analysis of the *HIBCH* gene was performed via direct DNA sequencing. Genomic DNA was isolated from peripheral blood of the probands and their family using a DNA isolation kit (QIAGEN, Ankara, Turkey). To identify any mutations the probands might carry, exons of the *HIBCH* gene, including exon/intron flanking regions, were amplified by polymerase

chain reaction (PCR) with specific primers that were designed using Primer 3 software (<http://ihg.gsf.de/ihg/ExonPrimer.html>) and H Taq polymerase (Zeydanlı, Ankara, Turkey). Standard PCR conditions with 35 cycles were used and performed with a 9700 Thermal Cycler (Applied Biosystems, Foster City, CA, USA). The amplified products were purified with a Zymo Research Sequencing Clean-up Kit (Epigenetic Companies, Irvine, CA, USA). Cycle sequencing was performed with the BigDye Terminator

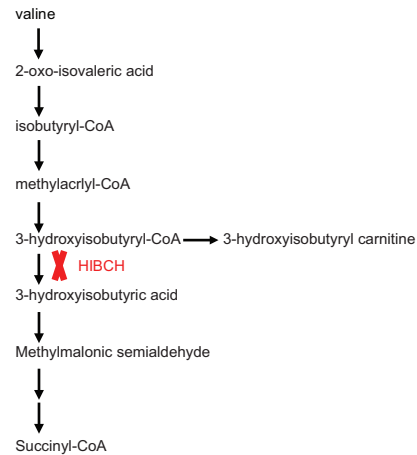


Figure 1: Valine degradation pathway

Table 1: Clinical, biochemical, cranial MRI findings and other features of patients

	Case 1 (index case)	Case 2 (sibling)	Case 3 (uncle)	Case 4 (aunt)	Case 5 (uncle)
Gender	Female	Female	Male	Female	Male
Birth type	NSD	NSD	NSD	NSD	NSD
Gestation week	38 + 4	39	38 + 6	39 + 1	39
Birth weight (g)	3300	3200	3500	4000	3600
Current age	4.5 years	2 years	8.5 years	4.5 years	6 months
Age at presentation	(1) Attack 2 years (2) Attack 3.5 years	-	1 years	10 months	-
Initial presentation	Developmental delay, seizures, lost off previously acquired milestones	Developmental delay	Developmental delay, lost off previously acquired milestones	Developmental delay, lost off previously acquired milestones	Asymptomatic
Other	-	-	Strabismus	Strabismus	-
Blood lactate level (mmol/l) (0.5-1.6)	1.8	1.5	1.3	1.2	1.1
Blood alanine level (µmol/l) (152-547)	196	306	253	202	170
Hydroxy-C4 carnitine (µmol/l) (<0.48)	1.58	1.33	0.65	0.89	0.75
Urine organic acid	Normal	Normal	Normal	Normal	Normal
Brain MRI	Bilateral symmetrical hyperintense signals of the caudate and lentiform nuclei	Bilateral symmetrical hyperintense signals of the globus pallidi	Bilateral symmetrical hyperintense signals of the globus pallidi	Bilateral symmetrical hyperintense signals of the globus pallidi	-
<i>HIBCH</i> gene analysis	c.452C > T, p.Ser151Leu homozygous	c.452C > T, p.Ser151Leu homozygous	c.452C > T, p.Ser151Leu homozygous	c.452C > T, p.Ser151Leu homozygous	c.452C > T, p.Ser151Leu homozygous

NSD: Normal spontaneous delivery

v3.1 Cycle Sequencing Kit (Applied Biosystems) on an Applied Biosystems® 3130 Genetic Analyzer. The sequence data were analyzed using the Applied Biosystems sequencing analysis v5.3.1 software program and were compared to the reference sequence (GenBank Accession Nos. NG_017062.1, NM_014362.4, NP_055177.2).

Sanger sequencing showed a homozygous variation (c. 452C>T, p.Ser151Leu) in exon 7 of the *HIBCH* (NM_014362) gene. The variant has not been previously reported in the Human Gene Mutation Database (<http://www.hgmd.cf.ac.uk/ac/index.php>) or in population studies (Exome Aggregation Consortium and 1000 Genomes Project). In-silico analysis programs showed that the variant may be pathogenic [Figure 3, Table 2].

Each amino acid has its own specific size, charge, and hydrophobicity value. The original wild-type residue and newly introduced mutant residue (*HIBCH*; c.452C>T, p.Ser151Leu) often differ in these properties. The mutant residue is bigger and more hydrophobic than the wild-type residue. The size difference between wild-type and mutant residue makes that the new residue is not in the correct position to make the same hydrogen bond as the original wild-type residue did. The difference in hydrophobicity will affect hydrogen bond formation and as a result disturb correct folding. The mutated residue is located in a domain that is important for the activity of the protein and in contact with another domain that is also important for the activity. The interaction between these domains could be disturbed by the mutation, which might

affect the function of the protein (HOPE: <https://www3.cmbi.umcn.nl/hope/>).

Ethics committee

The study was performed with adherence to the Helsinki Declaration and was approved by the University of Health Sciences, Okmeydanı Training and Research Hospital, Clinical Research Ethics Committee (Approval number: 48670771-514.10) date of the approval 14/11/2019.

RESULTS

Five cases reported from the same family were born at term after healthy pregnancies and normal deliveries. The genders, birth histories, and consanguineous marriages of the cases are presented in Table 1. There was no problem in any of the patients after delivery, and there were no hospitalizations in the neonatal intensive care unit.

There was no diagnosed neurological or metabolic disease in these families. However, our index patient had a family history of developmental delay and loss of previously acquired milestones in her sibling and mother’s siblings. Our cases were five patients from two families, all of whom were of Syrian ethnic origin.

Case 1 (index case) was presented at 3.5 years old with status epilepticus. The patient’s parents were cousins, and the patient started to sit at an age of 2 and to walk at an age of 3.5. The patient had a seizure at an age of 2.5 and was observed to

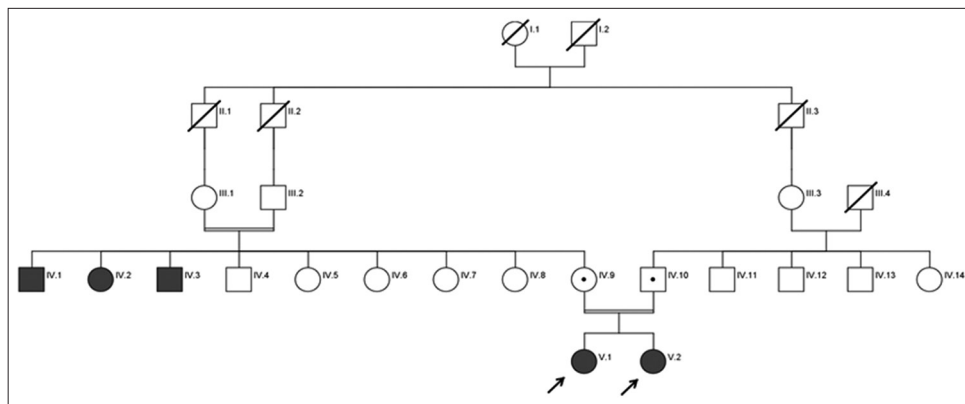


Figure 2: Pedigree analysis of the family. Pedigree of the family showing the identified *HIBCH* mutation (c.452C>T, p.Ser151Leu). The arrows indicate the probands. The probands IV.1, IV.2, and IV.3 are homozygous; IV.9 and IV.10 are heterozygous for the mutation

Table 2: Features of the variant identified in this study

Gene	Nucleotide change	Amino acid change	Type	Zygoty	ClinVar	ACMG criteria	DANN score	Mutation Taster	SIFT	PROVEAN	gnomAD	R/N
HIBCH (NM_014362)	c.452C>T	p.Ser151Leu	Missense	Homozygous	Likely pathogenic	UCS	0.9992	Disease causing	Damaging	Damaging	0	N

ACMG: American College of Medical Genetics, SIFT: Sorting Intolerant from Tolerant, UCS: Uncertain Significance, PROVEAN: Protein Variation Effect Analyzer, genomAD: Genome Aggregation Database (<https://gnomad.broadinstitute.org/>), R/N: Reported/Novel. ClinVar is a database which connects variants with clinical associated phenotypes, maintained by NCBI, the (US) National Center for Biotechnology Information. It also provides related supporting evidence and the name of the submitter (<https://www.ncbi.nlm.nih.gov/clinvar/>) DANN is a pathogenicity scoring methodology developed by Daniel Quang, Yifei Chen, and Xiaohui Xie at the University of California, Irvine. It is based on deep neural networks. The value range is 0-1, with 1 given to the variants predicted to be the most damaging (<https://varsome.com/>)

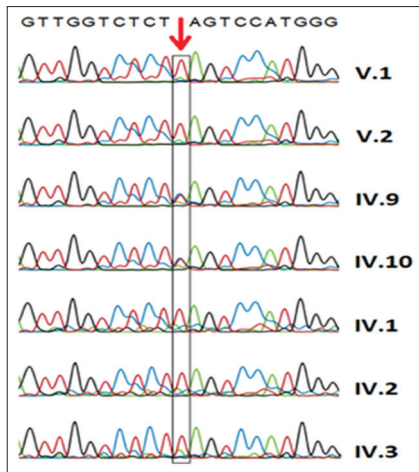


Figure 3: Molecular genetic analysis of the family. The results of DNA sequencing. The missense germ-line mutation, c.452C>T, p.Ser151Leu, on the *HIBCH* (NM_014362) gene of the family (red arrow)

have lost previously acquired milestones for a long period after the seizure, but then she regained her motor functions. Metabolic and radiological investigations were not performed in detail at that time. The patient was admitted to our institution with status epilepticus, was observed to have lost previously acquired milestones, and had hypotonicity after her seizures were controlled with antiepileptic treatments. Her complete blood count, biochemistry, blood gas, and ammonia levels were normal during follow-up. On metabolic examinations, the plasma lactate level was 1.6 mmol/l (0.5–1.6 mmol/l), and the plasma alanine level was 196 μ mol/l (152–547 μ mol/l). In the acylcarnitine analysis, a hydroxy-C4 carnitine level of 1.58 μ mol/l (0–0.48 μ mol/l) was detected. Urine organic acid analysis revealed a lactic acid level of 51 mg/g creatinine (0–104.3 mg/g creatinine) and a 3-hydroxy-isovaleric acid level of 37.2 mg/g creatinine (0–52.4 mg/g creatinine). During follow-up, the patient's eye contact and eye tracking started, truncal hypotonicity continued, and the tonus of the lower extremities and the deep tendon reflexes (DTRs) increased. The patient had no pathologies on her eye examination or echocardiography, but there were signal changes in the basal ganglia on cranial MRI [Figure 4]. Her cranial MRI had bilateral, symmetrical, and hyperintense signal changes in the caudate nucleus and lentiform nucleus. Differential diagnoses were reviewed based on the pathologies detected from metabolic examinations and Leigh-like syndrome detected from MRI.

Case 2 was the sister of case 1. She was 1.5 years old and had developmental delay: held her head up at 5 months, rolled over at 8 months, sat at 1 year, and after that began to crawl. There were no seizures or neurological regression in her history. On examination, there was an increase in the tonus of her lower extremities, and her DTRs were normoactive. She could not speak. The patient was examined due to the history of her sister's seizures and neurological regression. The patient's complete blood count,

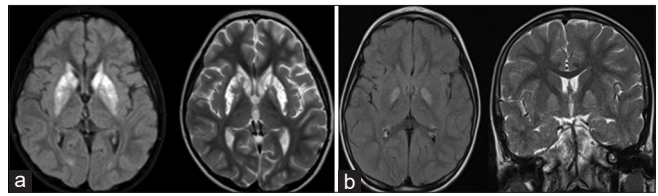


Figure 4: (a) Cranial MRI, case 1 (index case), pathological signal changes in bilateral caudate and lentiform nuclei. (b) Cranial MRI, case 3, pathological signal changes bilaterally globus pallidus

biochemistry, blood gas, and ammonia levels were normal. On her tests, the following results were observed: plasma lactate, 1.5 mmol/l (0.5–1.6 mmol/l); plasma alanine, 306 μ mol/l (152–547 μ mol/l); and hydroxy-C4 carnitine, 1.33 μ mol/l (0–0.48 μ mol/l) (in the acylcarnitine analysis). The urine organic acid analysis revealed a lactic acid level of 27.5 mg/g creatinine (0–104.3 mg/g creatinine) and a 3-hydroxy-isovaleric acid level of 14.2 mg/g creatinine (0–52.4 mg/g creatinine). Signal changes in the basal ganglia were detected on cranial MRI. The siblings were thought to have similar clinical, laboratory, and radiological findings and to have the same disease.

Cases 3 and 4 were the siblings of the mother of the index case (aunt and uncle of the index case) [Figure 2]. Both the history and physical examination findings in these two cases were similar. These patients were 8.5 and 4.5 years old and had lost previously acquired milestones after a febrile infection at 1 year and 10 months, respectively. In the examination of case 3, there were strabismus, hypertonicity in the lower extremities, and increased DTRs. The speech of the patient, who could walk with assistance, was slow and dysarthric. In the examination of case 4, strabismus was present, and after the attack she had at an age of 10 months, she regained her motor functions slowly and started to sit at an age of 4. The tone and DTRs of the lower extremities slightly increased, and there was no speech or walking. In both cases, the complete blood count, biochemistry, blood gas, and ammonia levels were normal. The plasma lactate levels were analyzed, and blood amino acid analysis, acylcarnitine analysis, and urine organic acid analysis were performed [Table 1]. Cranial MRI was performed.

Case 5 was the brother of cases 3 and 4 and was asymptomatic. He was 6 months old, and his neuromotor development was appropriate for his age. There were no seizures or neurological regression in his history. Upon detection of pathologies in the siblings' metabolic tests, screening tests were performed. Similar laboratory findings to those of his siblings were found.

When all cases were evaluated, there were differences in the history, physical examination, and clinical findings, but their common features were the pathologies present in the acylcarnitine analysis and cranial MRI. In light of the clinical and laboratory findings, a differential diagnosis of hydroxy-C4 carnitine elevation was performed with our algorithm. In our

cases, HIBCH deficiency was considered primarily because of the increased hydroxy-C4 carnitine and the Leigh-like syndrome on MRI.

The index case was first analyzed, and then, *HIBCH* gene analyses of the other cases were performed. In the *HIBCH* gene, a pathogenic mutation that was not previously reported in the literature, a missense c.452C>T, p.Ser151Leu homozygous mutation, was detected [Figure 3]. The analysis results of the mutation's databases (American College of Medical Genetics, ClinVar, A Deep Learning Approach for Annotating) are given in Table 2.

After the diagnosis was confirmed, all cases were started on carnitine therapy and valine-restricted diet therapy.

DISCUSSION

In addition to the 22 HIBCH deficiency cases reported in the literature [Table 3], we report 5 additional cases. There was developmental delay, hypotonia, neurological regression, seizures, and Leigh-like signal abnormalities on cranial MRI in our cases. There were no congenital malformations or anomalies in our cases. Common features of this serious metabolic disease include developmental delay or regression, hypotonia, seizures, and Leigh-like signal abnormalities on MRI. Congenital malformations were also mentioned in the first described case.^[1] Afterward, a syndromic HIBCH deficiency case report was described.^[3] In a case series of five Turkish HIBCH deficiency cases, Schottmann *et al.* reported one case with a hernia of the diaphragm.^[4] In addition, a case

Table 3: All HIBCH deficiency cases reported in the literature

References	Number of case	Gender	Ethnic origin	Consanguinity	HIBCH gene mutation	Clinic findings	Abnormal signals in brain MRI
Brown; 1982 ^[1]	1	Male	Egypt	(+)	Lys74Leufs*13	Hypotonia, dysmorphism, tetralogy of Fallot, vertebral abnormalities	ND
Loupatty; 2007 ^[10]	1	Male	ND	(-)	Tyr122Cys/IVS2-3C > G	Hypotonia, motor delay, neurological regression	Globi pallidi
Ferdinandusse; 2013 ^[11]	2	Male Male	Pakistan	(+)	c.950G < A (p.Gly317Glu)	Hypotonia, developmental regression, seizures, visual impairment	Dentate nuclei globi pallidi
Yamada; 2014 ^[12]	2	Female Female	Japanese	(-)	Ala96Asp	Hypotonia, development delay	Globi pallidi
Reuter; 2014 ^[6]	1	Male	Tunisia	(+)	p.Lys377	Hypotonia, psychomotor delay, seizures, optic atrophy	Globi pallidi
Zhu; 2015 ^[8]	1	Female	Chinese	(-)	c.1027C > G c.79-1G > T	Development delay, encephalopathy extrapyramidal symptoms	Basal ganglia
Soler-Alfonso; 2015 ^[9]	1	Female	Caucasian	(-)	c.517 + 1G > A c.410C > T (p.A137V) compound heterozygous	Hypotonia, developmental delay, nystagmus	Globi pallidi
Stiles; 2015 ^[7]	2	Male Female	Lebanese	(-)	c.196C > T (p.Arg66Trp)	Hypotonia, developmental delay optic atrophy	Globi pallidi
Schottmann; 2016 ^[4]	3	Male Female Male	Turkish	(+)	c.913A > G	Hypotonia, ataxia, developmental delay	Globi pallidi
Schottmann; 2016 ^[4]	2	Male Male	Turkish	(+)	c.913A > G	Dystonia, spasticity	Globi pallidi
Xu; 2017 ^[5]	1	Female	Chinese	(-)	c.1027C > G (p.H343D) c.383T > A (p.V128D)	Exercise-induced dystonia	Globi pallidi
Yang; 2018 ^[13]	1	Male	Chinese	(-)	c.439-2A > G c.958A > G (p.K320E)	Developmental regression, dystonia	Basal ganglia
Tan; 2018 ^[2]	1	Male	Chinese	(-)	c.304 + 3A > G c.1010_1011+3delTTGGTA	Hypotonia, psychomotor delay, bilateral syndactyly of toes, dysmorphic features	Widened cerebral sulcus and thinning of the corpus callosum
Karimzadeh; 2019 ^[14]	1	Male	Iran	(-)	c.641C > T (p.Thr214Ile) c.913A > G (p.Thr305Ala)	Hypotonia, ataxia, nystagmus	Basal ganglia
Candelo; 2019 ^[3]	2	Female Male	Colombian	(-)	c.808A > G (p.Ser270Gly)	Hypotonia, developmental delay	Basal ganglia

ND: No definition

of HIBCH deficiency with a presentation of exercise-induced dystonia has been reported in the literature.^[5]

In the literature, the increase in hydroxy-C4 carnitine in HIBCH deficiency in acylcarnitine analyses has been reported in almost all cases.^[6] Acylcarnitine analyses also showed increased hydroxy-C4 carnitine in our patients. The increased lactate level in the plasma and 3-hydroxy-isovaleric acid excretion in urine organic acid analysis have been observed in some cases in the literature but were not observed in our cases. In this disease, metabolic tests are helpful in diagnosis, and acylcarnitine analysis also suggests HIBCH deficiency in the differential diagnosis of increased hydroxy-C4 carnitine.

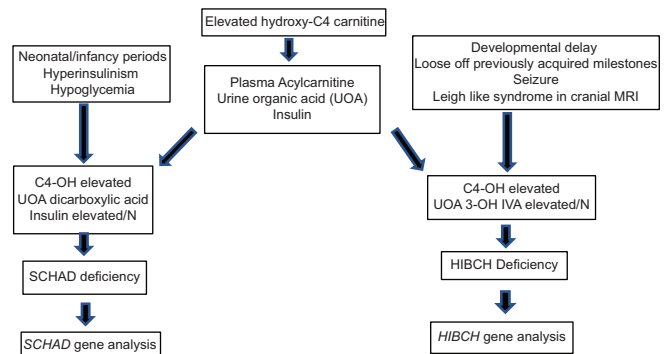
In almost all cases of HIBCH deficiency reported in the literature, as in our cases, progressive neurodegeneration and infantile-onset bilateral, symmetrical abnormalities in the basal ganglia have typical features of Leigh's syndrome.^[7,8]

With the presence of Leigh-like features on MRI, different diagnoses of mitochondrial disorders, pyruvate dehydrogenase complex deficiency, biotin–thiamine basal ganglia disease, or 3-methylglutaconic aciduria with deafness, encephalopathy, and Leigh-like syndrome (MEGDEL syndrome) may be one reason that extremely few cases of HIBCH deficiency have been reported in the literature. Therefore, it is important to report HIBCH deficiency cases, whose frequency may be higher.

Most patients with HIBCH deficiency that have been reported in the literature were diagnosed with WES. HIBCH deficiency was suspected due to clinical, laboratory, and MRI findings in our cases, and only *HIBCH* gene analysis was performed. *HIBCH* gene analysis alone instead of WES is cost-effective in the presence of the mentioned findings.

In the literature on the treatment of patients with HIBCH deficiency, it is reported that partial improvements in neurological findings have been observed with high carbohydrate intake in the diet, restriction of valine, and carnitine supplementation.^[2,9,10] Carnitine supplementation and a protein-restricted diet were also used in our cases. After carnitine treatment and a protein-restricted diet, our patients' clinical parameters were stable, but the follow-up times were short. Longer follow-up time is needed.

In this article, we want to emphasize two points. First, metabolic tests (acylcarnitine analysis) and cranial MRI should be performed in patients with neurological regression, seizures, and developmental delay. In cases with clinical, laboratory, and MRI findings similar to those in our cases, HIBCH deficiency should absolutely be considered in the differential diagnosis, and *HIBCH* gene analysis should be performed instead of WES. Our algorithm will help in the differential diagnosis of patients with these features [Figure 5].^[8] Second, the missense c.452C>T, p.Ser151Leu homozygous novel pathogenic mutation that we detected in the *HIBCH* gene in our cases will contribute to the literature [Figure 3, Table 2].



N: normal,
3-OH IVA: 3-hydroxy isovaleric acid,
SCHAD: short chain L-3-hydroxyacyl-CoA dehydrogenase deficiency

Figure 5: Algorithm for clinic and laboratory follow-up with isolated elevations of hydroxy-C4-carnitine in NBS

CONCLUSION

The reason HIBCH deficiency disease is so rare may be that most of these patients are followed up with misdiagnosed. In patients with neurological regression, seizures, and developmental delay, if the acylcarnitine analysis also has 3-hydroxy-isobutyryl-carnitine elevation and brain MRI with Leigh-like syndrome, HIBCH deficiency is likely to be a differential diagnosis. We can increase the number of patients in the literature with performing *HIBCH* gene analysis instead of WES.

Acknowledgments

The authors thank the patients for cooperation and also thank Murat Çakar for his contribution to translating the article.

Financial support and sponsorship

Nil.

Conflicts of interest

There are no conflicts of interest.

REFERENCES

1. Brown GK, Hunt SM, Scholem R, Fowler K, Grimes A, Mercer JF, *et al.* beta-hydroxyisobutyryl coenzyme A deacylase deficiency: A defect in valine metabolism associated with physical malformations. *Pediatrics* 1982;70:532-8.
2. Tan H, Chen X, Lv W, Linpeng S, Liang D, Wu L. Truncating mutations of HIBCH tend to cause severe phenotypes in cases with HIBCH deficiency: A case report and brief literature review. *J Hum Genet* 2018;63:851-5.
3. Candelo E, Cochard L, Caicedo-Herrera G, Granados AM, Gomez JF, Diaz-Ordoñez L, *et al.* Syndromic progressive neurodegenerative disease of infancy caused by novel variants in HIBCH: Report of two cases in Colombia. *Intractable Rare Dis Res* 2019;8:187-93.
4. Schottmann G, Sarpong A, Lorenz C, Weinhold N, Gill E, Teschner L, *et al.* A movement disorder with dystonia and ataxia caused by a mutation in the HIBCH gene. *Mov Disord* 2016;31:1733-9.
5. Xu Y, Zhang J, Yu K, Feng F, Sun X, Li C, *et al.* A therapeutic regimen for 3-hydroxyisobutyryl-CoA hydrolase deficiency with exercise-induced dystonia. *Eur J Paediatr Neurol* 2019;23:755-9.
6. Reuter MS, Sass JO, Leis T, Köhler J, Mayr JA, Feichtinger RG, *et al.* HIBCH deficiency in a patient with phenotypic characteristics of mitochondrial disorders. *Am J Med Genet A* 2014;164A: 3162-9.
7. Stiles AR, Ferdinandusse S, Besse A, Appadurai V, Leydiker KB,

- Cambray-Forker EJ, *et al.* Successful diagnosis of HIBCH deficiency from exome sequencing and positive retrospective analysis of newborn screening cards in two siblings presenting with Leigh's disease. *Mol Genet Metab* 2015;115:161-7.
8. Zhu H, Bao X, Zhang Y. [3-Hydroxy-isobutyryl-CoA hydrolase deficiency in a child with Leigh-like syndrome and literature review]. *Zhonghua Er Ke Za Zhi* 2015;53:626-30.
 9. Soler-Alfonso C, Enns GM, Koenig MK, Saavedra H, Bonfante-Mejia E, Northrup H. Identification of HIBCH gene mutations causing autosomal recessive Leigh syndrome: A gene involved in valine metabolism. *Pediatr Neurol* 2015;52:361-5.
 10. Loupaty FJ, Clayton PT, Ruitter JPN, Ofman R, Ijlst L, Brown GK, *et al.* Mutations in the gene encoding 3-hydroxyisobutyryl-CoA hydrolase results in progressive infantile neurodegeneration. *Am J Hum Genet* 2007;80:195-9.
 11. Ferdinandusse S, Waterham HR, Heales SJR, Brown GK, Hargreaves IP, Taanman J-W, *et al.* HIBCH mutations can cause Leigh-like disease with combined deficiency of multiple mitochondrial respiratory chain enzymes and pyruvate dehydrogenase. *Orphanet J Rare Dis* 2013;8:188.
 12. Yamada K, Naiki M, Hoshino S, Kitaura Y, Kondo Y, Nomura N, *et al.* Clinical and biochemical characterization of 3-hydroxyisobutyryl-CoA hydrolase (HIBCH) deficiency that causes Leigh-like disease and ketoacidosis. *Mol Genet Metab Rep* 2014;1:455-60.
 13. Yang H-Y, Wu L-W, Deng X-L, Yin F, Yang L-F. [Diagnosis and treatment of 3-hydroxyisobutyryl-CoA hydrolase deficiency: A case report and literature review]. *Zhongguo Dang Dai Er Ke Za Zhi* 2018;20:647-51.
 14. Karimzadeh P, Saberi M, Sheidaee K, Nourbakhsh M, Keramatipour M. 3-Hydroxyisobutyryl-CoA hydrolase deficiency in an Iranian child with novel HIBCH compound heterozygous mutations. *Clin Case Rep* 2019;7:375-80.