

RESEARCH

Open Access

The appearance of renal cells cytoplasmic degeneration and nuclear destruction might be an indication of GNPs toxicity

Mohamed Anwar K Abdelhalim^{1*} and Bashir M Jarrar²

Abstract

Background: Advances in nanotechnology have identified promising candidates for many biological and biomedical applications. Since the properties of nanoparticles (NPs) differ from that of their bulk materials, they are being increasingly exploited for medical uses and other industrial applications. The histological and the histochemical alterations in the renal tissues due to gold nanoparticles (GNPs) have not well documented and have not yet been identified. The aim of the present study was to investigate the particle-size effect of GNPs on the renal tissue in an attempt to address their potential toxicity.

Methods: A total of 70 healthy male Wistar-Kyoto rats were exposed to GNPs received 50 or 100 μ l of GNPs infusion of size (10, 20 and 50 nm for 3 or 7 days) to investigate particle-size effect of GNPs on the renal tissue. Animals were randomly divided into groups, 6 GNPs-treated rats groups and one control group. Groups 1, 2 and 3 received infusion of 50 μ l GNPs of size 10 nm (3 or 7 days), size 20 nm (3 or 7 days) and 50 nm (3 or 7 days), respectively; while groups 4, 5 and 6 received infusion of 100 μ l GNPs of size 10 nm, size 20 nm and 50 nm, respectively.

Results: The histological alterations were mainly seen in the cortex and the proximal renal convoluted tubules were more affected than the distal ones. In comparison with respective control rats, exposure to GNPs doses has produced the following renal tubular alterations: cloudy swelling and renal tubular necrosis. Interstitial alterations included: intertubular blood capillaries dilatation, intertubular hemorrhage and inflammatory cell infiltrations. The glomeruli showed moderate congestion with no hypercellularity and mesangial proliferation or basement membrane thickening.

Conclusions: The induced histological alterations might be an indication of injured renal tubules due to GNPs toxicity that become unable to deal with the accumulated residues resulting from metabolic and structural disturbances caused by these NPs. These alterations were size-dependent with smaller ones induced more effects and related with time exposure of GNPs. The produced histological alterations may suggest that GNPs interact with proteins and enzymes of the renal tissue interfering with the antioxidant defense mechanism and leading to reactive oxygen species (ROS) generation which in turn may induce stress in the renal cells to undergo atrophy and necrosis. More histomorphological investigations are needed to address the potential threat of GNPs as a therapeutic and diagnostic tool.

Keywords: gold nanoparticles, renal tissue, histology, hydropic degeneration, nanotoxicity

* Correspondence: abdelhalimmak@yahoo.com

¹Department of Physics and Astronomy, College of Science, King Saud, University, P.O. Box 2455, Riyadh-11451, Saudi Arabia
Full list of author information is available at the end of the article

Introduction

Nanoparticles are an intermediate state of matter somewhere between bulk and molecular level. These particles have important application for cell labeling and imaging, drug delivery, biological sensors, diagnostic and therapeutic purposes mainly in cancer and photodynamic therapy [1-6]. Studies revealed that the NPs were rapidly taken into the system with the highest accumulation in the liver, spleen, lungs, aorta, esophagus and olfactory bulb [7]. Moreover, particles of nano-dimension are believed to be more biologically reactive than their bulk counter parts due to their small size and larger surface area to volume ratio [7,8].

Gold in its bulk form has long been considered an inert, noble metal with some therapeutic and even medicinal value hence GNPs are thought also to be relatively non-cytotoxic [9]. Yet there are differing reports of the extent of the toxic nature of these particles owing to their different modifications, surface functional attachments, shape and size [10,11]. Moreover, the metallic nature of the metal derived NPs and the presence of transition metals encourages the production of reactive oxygen species (ROS) leading to oxidative stress [12,13].

Although some scientists consider NPs as nontoxic, there are other studies reporting the toxic effects of NPs [14-16]. While some NPs may appear to be nontoxic, other cellular mechanisms such as cell signaling and other normal cellular functions may be disrupted and are currently undergoing further investigation [17,18]. The toxicity of NPs is being addressed by a number of standardized approaches with *in vitro*, *in vivo* as well as detailed genomic or biodistribution studies [18]. In addition, it has been shown that NPs may produce *in vitro* toxicity in some cell-based assays, but not in others. This may be a result of interference with the chemical probes, differences in the innate response of particular cell types, or other factors, a point to be considered when GNPs are used as carriers for the delivery of drugs and in gene therapy [19,20].

While nanotoxicity research is now gaining attention, little is paid to the effect of size and period of NPs mainly to their distribution and alterations in the tissue [21,22]. In the present study, an attempt has been made to address the possible histological alterations in the renal tissues following exposure to GNPs and, if so, whether the potential nanotoxicity is related to the size of these particles and the time of exposure.

Materials and methods

A total of 70 healthy male Wistar-Kyoto rats obtained from the Laboratory Animal Center (College of Pharmacy, King Saud University, Saudi Arabia). The rats nearly of the same age (12 weeks old) and weighing 220-240 gm of King Saud University colony were used.

Animals were randomly divided into groups, 6 GNPs-treated rats groups and one control group. Following a period of stabilization (7 days), 10, 20 and 50 nm GNPs were administered intraperitoneally at the rate for 3 or 7 days as follows: Group 1: received infusion of 50 μ l GNPs of size 10 nm for 3 or 7 days ($n = 10$); Group 2: received infusion of 50 μ l GNPs of size 20 nm for 3 or 7 days ($n = 10$); Group 3: received infusion of 50 μ l GNPs of size 50 nm for 3 or 7 days ($n = 10$); Group 4: received infusion of 100 μ l GNPs of size 10 nm for 3 or 7 days; ($n = 10$); Group 5: received infusion of 100 μ l GNPs of size 20 nm for 3 or 7 days ($n = 10$); Group 6: received infusion of 100 μ l GNPs of size 50 nm for 3 or 7 days; ($n = 10$); Control group: received no GNPs ($n = 10$).

The rats were maintained on standard laboratory rodent diet pellets and were housed in humidity and temperature-controlled ventilated cages on a 12 h day/night cycle. All experiments were conducted in accordance with the guidelines approved by King Saud University Local Animal Care and Use Committee.

Fresh portions of both kidneys from each rat were cut rapidly, fixed in neutral buffered formalin (10%), then dehydrated, with grades of ethanol (70, 80, 90, 95 and 100%). Dehydration was then followed by clearing the samples in 2 changes of xylene. Samples were then impregnated with 2 changes of molten paraffin wax, then embedded and blocked out. Paraffin sections (4-5 μ m) were stained with hematoxylin and eosin (the conventional histological stain) according to Pearse [23]. Stained sections of control and treated rats were examined for alterations in renal tissue.

Results and discussions

No mortality occurred in any of the experimental groups of the present investigation, and no alterations were observed in the appearance and behavior of GNPs treated rats in comparison with the control ones. In comparison with the control group, the following histological alterations were detected in the renal tissue of GNPs treated rats: The following tubular alterations due to GNPs intoxication appeared in the renal tissue of the treated rats.

GNPs produced occasional glomerular congestion in the rats exposed to 10 nm or 20 nm particles for 7 days but not in the glomeruli of the rats exposed to 50 nm (Figure 1). Hypercellularity and mesangial proliferation or glomerular basement membrane thickening was not detected in the glomeruli of all GNPs treated rats. Occasional dilatation of glomerular tuft blood capillaries was observed. These little alteration showed by the glomeruli might be due to the glomerular basement membrane which forms a barrier that prevents nanoparticles accumulation. Terentyuk et al., 2009 [24] have reported

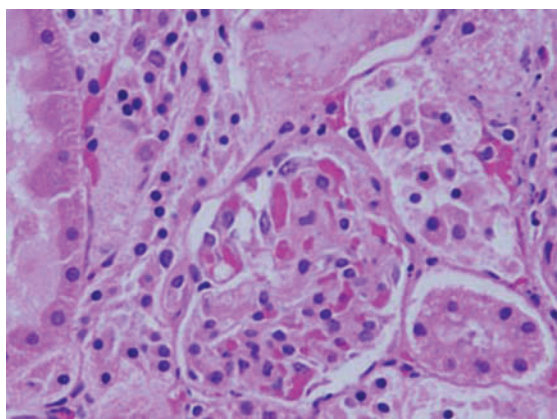


Figure 1 Light micrographs of sections in the kidney of: GNPs-treated rat received 100 μ l of 10 nm particles for 3 days demonstrating dissociation of renal cells next to glomerular congested glomerulus.

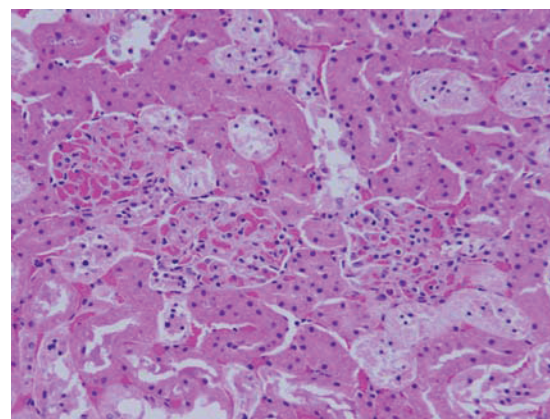


Figure 2 Light micrographs of sections in the kidney of: GNPs-treated rat received 50 μ l of 20 nm particles for 3 days demonstrating renal tubules necrosis.

proliferation of epithelial cells of Bowman's capsule by GNPs where 15 nm particles showed more effect than larger ones.

Dissociation of renal cells

dissociation of renal cells mainly next to glomerular congested glomeruli was seen (Figure 1). This alteration might indicate that GNPs affect renal cells adhesion and induces cell-cell junction disruption. According to Inumaru et al., 2009 [25] oxidative stress is a crucial factor to induce cell-cell dissociation.

Renal tubules necrosis

cellular necrosis was observed in the renal proximal tubules of GNPs-treated rats. The degenerative tubules showed swelling cytolysis and thinning or absence of the proximal tubular brush border and tubular irregularity (Figures 2 and 3). This alteration was more prominent in the cortex than the medulla and was accompanied with inter-tubular blood capillaries congestion and accompanied cytoplasmic eosinophilia in some of the necrotic proximal convoluted tubules. Tubular necrosis was detected in the renal tubules of rats exposed to 20 nm size particles and to lesser extent with 10 nm ones but was not seen with those exposed to 50 nm size particles. Necrosis was more prominent in the kidneys of the rats received 100 μ l than 50 μ l and less in 3 days than ones exposed to 7 days. Necrosis might be followed by organelles swelling specially mitochondria, endoplasmic reticulum and rupture of lysosomes before shrinking and dissolution of renal cells nuclei [26].

Inflammatory cells infiltration

Inflammatory cells infiltration was seen in renal tissue of some GNPs treated rats. The infiltrate cells were mainly

neutrophils and mononuclear cells (Figure 4). This infiltration was more after 7 days of administration and in rats received 100 μ l than those received 50 μ l but less prominent in the kidneys of rats exposed to 50 nm particles. The appearance of inflammatory cells in the renal tissue may suggest that GNPs could interact with proteins and enzymes of the renal interstitial tissue interfering with the antioxidant defense mechanism and leading to reactive oxygen species (ROS) generation which in turn may imitate an inflammatory response [27]. Yen et al., 2009 [28] have reported an induction of more immunological responses with smaller GNPs than the larger ones.

Interstitial alterations

The kidney of the GNPs treated rats showed the following interstitial alterations: 1) **Intertubular blood**

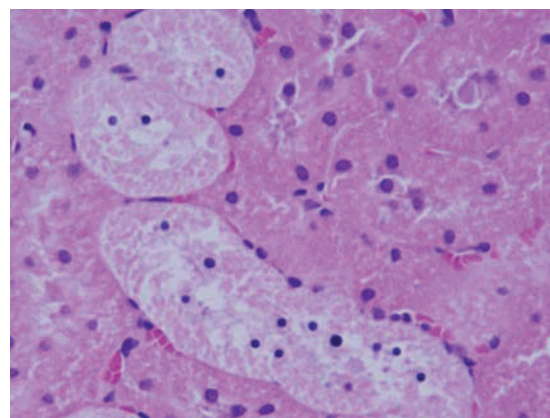


Figure 3 Light micrographs of sections in the kidney of: GNPs-treated rat received 100 μ l of 10 nm particles for 7 days demonstrating renal tubules necrosis.

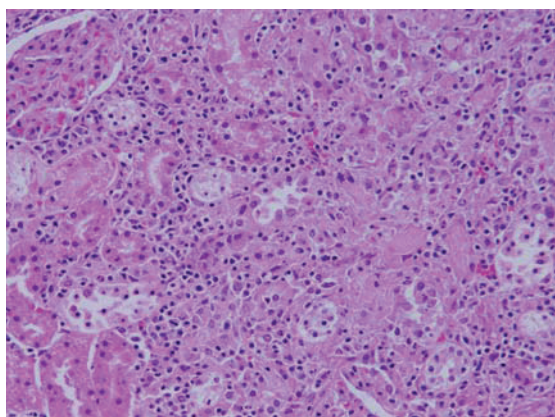


Figure 4 Light micrographs of sections in the kidney of: GNPs-treated rat received 100 μ l of 20 nm particles for 7 days demonstrating inflammatory cell infiltration.

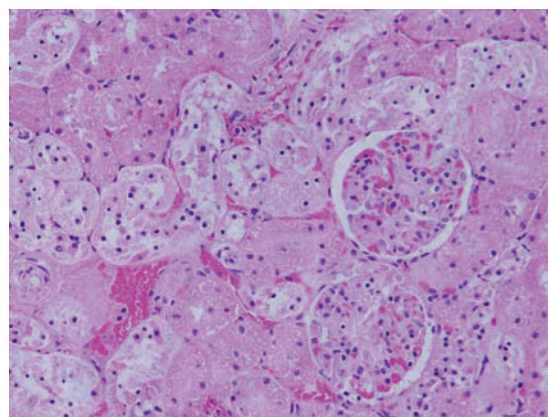


Figure 6 Light micrographs of sections in the kidney of: GNPs-treated rat received 100 μ l of 20 nm particles for 7 days demonstrating intertubular hemorrhage.

capillaries dilatation: the kidneys of GNPs treated rats showed occasional inter-tubular blood capillaries dilatation in rats received 100 μ l of 10 or 20 nm particles for 7 days (Figure 5). This dilatation might be due to the decrease in the vascular resistance of the renal tissue induced by GNPs; 2) **Intertubular hemorrhage:** Focal intertubular hemorrhage was seen in the kidneys of rats exposed to 100 μ l of 10 or 20 nm particles for 7 days (Figure 6).

The loop of Henle showed very little or no alterations due to GNPs intoxication while occasional cytomegaly and luminal hyaline casts were the only alterations observed in the collecting tubules. The renal tissue of the rats received 50 or 100 μ l of 50 nm GNPs for 3 or 7 days showed little or no alterations while none of the above alterations were observed in the renal tissue of any member of the control group (Figures 7 and 8).

Studies indicated that distribution in the inner organs is size dependent [24].

The results of the present work showed that the cortex is more affected than medulla due to treatment with GNPs. This could be partly due to uneven distribution of these particles in the tissue of the kidney where about 90% of the total renal blood flow enters the cortex via the bloodstream. Accordingly, a relative high concentration of particles might reach the cortex via the bloodstream than that would enter the medulla.

The findings of the present study indicate that the potential toxicity of GNPs is dependent upon the size of these particles. These findings are in line with the reports of Pan et al., 2007 [29] where cell lines where smallest GNPs demonstrated greatest toxicity compared to larger ones. Similar conclusion has been reported by Jong and Borm [30] when GNPs were injected

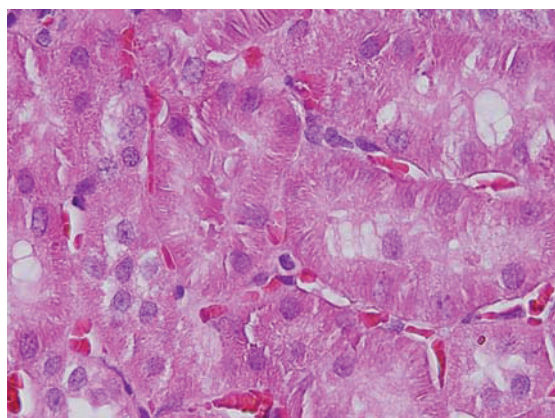


Figure 5 Light micrographs of sections in the kidney of: GNPs-treated rat received 100 μ l of 10 nm particles for 7 days demonstrating intertubular blood capillaries dilatation.

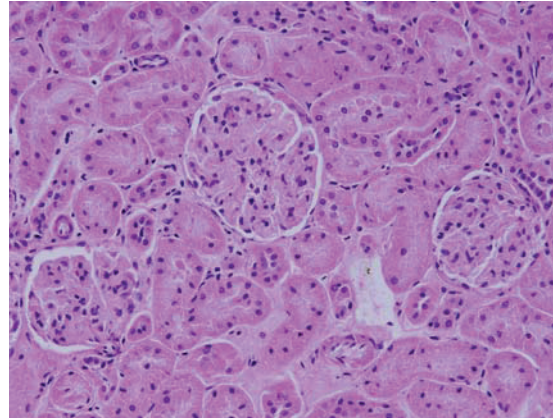


Figure 7 Light micrographs of sections in the kidney of: GNPs-treated rat received 50 μ l of 50 nm particles for 3 days demonstrating normal glomerular structure.

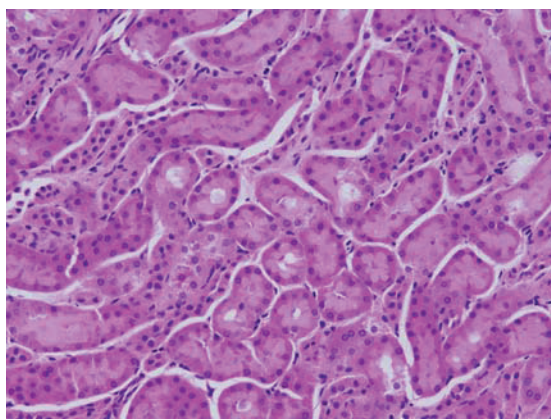


Figure 8 Light micrographs of sections in the kidney of: GNPs-treated rat received 100 μ l of 50nm particles for 7 days demonstrating normal renal tubules.

intravenously into mice. This might be due to the fact that as size of a particle decreases, its surface area to volume ratio increases, resulting in increased surface reactivity with a tendency for toxicity even if the material is relatively inert in a bulk form [31-33]. Also, several studies indicate that the distribution of GNPs in the body tissue is size dependent [34,35].

Conclusions

Histological alterations by GNPs exposure as shown in the results of the present work could be an indication of injured renal tissue due to GNPs toxicity that become unable to deal with the accumulated residues resulting from metabolic and structural disturbances caused by these particles. One might conclude that these alterations are size-dependent with smaller ones induced more damage to renal tissue with relation with the time exposure of GNPs. This might be due to earlier accumulation of the larger NPs in the tissue while the smaller ones stay much longer in the bloodstream due to recirculation.

The appearance of renal cells cytoplasmic degeneration and nuclear destruction may suggest that GNPs interact with proteins and enzymes of the renal tissue, interfering with the antioxidant defense mechanism and leading to generation and accumulation of the reactive oxygen species (ROS) which in turn may produce inflammatory response and mitochondrial destruction inducing stress in the renal cells to undergo atrophy, necrosis and programmed cell death.

More histomorphological, histochemical and ultrastructural investigations are needed to correlate the biomedical application of GNPs with their therapeutic and diagnostic use in correlation with the size, chemical

composition, surface charge, solubility and surface structure of these particles.

Acknowledgements

The authors are very grateful to National Plan of Science and Technology (NPST). This research was financially supported by the National Science and Technology Innovation Plan (NSTIP), **Research No. 08-ADV206-02** and **Research No. 09-NAN670-02**, College of Science, King Saud University, Saudi Arabia.

Author details

¹Department of Physics and Astronomy, College of Science, King Saud University, P.O. Box 2455, Riyadh-11451, Saudi Arabia. ²College of Applied Medical Sciences, Al-Jouf University, Saudi Arabia.

Authors' contributions

MAKA and BMJ have analyzed data, interpreted and written the final draft of this manuscript. The animal model used in this study was obtained from the Laboratory Animal Center (College of Pharmacy, King Saud University, Saudi Arabia). Dr. MAKA has conceived the study and its design and obtained research grants for this study. Moreover, both authors have read and approved the final manuscript.

Competing interests

The authors declare that they have no competing interests.

Received: 14 July 2011 Accepted: 22 August 2011

Published: 22 August 2011

References

1. Huang X, El-Sayed I, Qian W, El-Sayed M: **Cancer cell imaging and photothermal therapy in the near-infrared region by using gold nanorods.** *J Am Chem Soc* 2006, **128**:2115-20.
2. Jain P, El-Sayed I, El-Sayed M: **Au nanoparticles target cancer.** *Nanotoday* 2007, **2**:18-29.
3. Pissuwan D, Valenzuela S, Cortie MM: **Therapeutic possibilities of plasmonically heated gold nanoparticles.** *Trends in Biotechnol* 2006, **24**:62-67.
4. Visaria R, Bischof J, Loren M, Williams B, Ebbini E, Paciotti G, Griffin R: **Nanotherapeutics for enhancing thermal therapy of cancer.** *Int J Hyperthermia* 2007, **23**(6):501-511.
5. Huff T, Tong L, Zhao Y, Hansen M, Cheng JX, Wei A: **Hyperthermic effects of gold nanorods on tumor cells.** *Nanomed* 2007, **2**:125-132.
6. Chen J, Wang D, Xi J, Au L, Siekkinen A, Warsen A, Li Y, Zhang H, Xia Y, Li X: **Immuno gold nanocages with tailored optical properties for targeted photothermal destruction of cancer cells.** *Nano Lett* 2007, **7**:1318-1322.
7. Lanone S, Boczkowski J: **Biomedical applications and potential health risks of nanomaterials: molecular mechanisms.** *Curr Mol Med* 2006, **6**:651-663.
8. Yu LE, Yung L-YL, Balasubramaniam KS, Hartono D, et al: **Translocation and effects of gold nanoparticles after inhalation exposure in rats.** *Nanotoxicology* 2007, **1**(3):235-42.
9. Connor EE, Mwamuka J, Gole A, Murphy CJ, Wyatt MD: **Gold nanoparticles are taken up by human cells but do not cause acute cytotoxicity.** *Small* 2005, **1**(3):325-327.
10. Takahashi H, Niidome Y, Niidome T, Kaneko K, Kawasaki H, Yamada S: **Modification of gold nanorods using phosphatidylcholine to reduce cytotoxicity.** *Langmuir* 2006, **22**(1):2-5.
11. Neuss S, Leifert A, Fischler M, Wen F, Simon U, et al: **Size-dependent cytotoxicity of gold nanoparticles.** *Small* 2007, **3**(11):1941-1949.
12. MacNee W, Donaldson K: **Mechanism of lung injury caused by PM10 and ultrafine particles with special reference to COPD.** *Eur Respir J* 2003, **21**(40):475-515.
13. Jia HY, Liu Y, Zhang XJ, Han L, Du LB, Tian Q, et al: **Potential oxidative stress of gold Nanoparticles by induced-NO releasing in serum.** *J am Chem Soc* 2009, **131**(1):40-1.

14. Chithrani BD, Chan WC: **Elucidating the mechanism of cellular uptake and removal of protein-coated gold nanoparticles of different sizes and shapes.** *Nano Lett* 2007, **7**:1542-1550.
15. Pan Y, Neuss S, Leifert A, Fischler M, Wen F, Simon U, Schmid G, Brandau W, Jahnhen-Dechent W: **Size-dependent cytotoxicity of gold nanoparticles.** *Small* 2007, **3**:1941-1949.
16. BarathManiKanth S, Kalishwaralal K, Sriram M, Pandian SRK, Youn H, Soohyun Eom S, Gurunathan S: **Anti-oxidant effect of gold nanoparticles restrains hyperglycemic conditions in diabetic mice.** *Journal of Nanobiotechnology* 2010, **8**:16.
17. Hussain SM, Hess KL, Gearhart JM, Geiss KT, Schlager JJ: **In vitro toxicity of nanoparticles in BRL- 3A rat liver cells.** *Toxicol in Vitro* 2005, **19**:975-983.
18. Schrand AM, Bradich-Stolle LK, Schlager JJ, Dai L, Hussain SM: **Can silver nanoparticles be useful as potential biological labels?** *Nanotechnology* 2008, **9**:1-13.
19. Shaw SY, Westly EC, Pittet MJ, Subramanian A, Schreiber SL, Weissleder R: **Perturbational profiling of nanomaterial biologic activity.** *Proc Natl Acad Sci USA* 2008, **105**:7387-7392.
20. Gibson JD, Khanal BP, Zubarev ER: **Paclitaxel-functionalized gold nanoparticles.** *J Am Chem Soc* 2007, **129**:11653-11661.
21. De Jong W, Hagens W, Krystek P, Burger M, Sips A, Geertsma R: **Particle size-dependent organ distribution of gold nanoparticles after intravenous administration.** *Biomater* 2008, **29**(12):1912-1919.
22. Kattumuri V, Katti K, Bhaskaran S, Boote E, Casteel S, Fent G, Robertson D, Chandrasekhar M, Kannan R, Katti K: **Gum rabiic as a phytochemical construct for the stabilization of gold nanoparticles: In vivo pharmacokinetics and x-ray-contrast-imaging studies.** *Small* 2007, **3**:333-341.
23. Pearse AE: **Histochemistry. Theoretical and applied. Analytical technology.** Churchill-Livingstone, Edinburgh,; 4 19852.
24. Terentyuk G, Maslyakova G, Suleymanova L, Kogan B, Khlebtsov B, Akchurin G, Makisimova I, Shantrokha A, Tuchin V: **Tracking gold nanoparticles in the body.** *J Biomedical Optics* 2009, **14**:19-16.
25. Inumaru J, Tanihar H, Umezawa k, Niwa S, Suzuki Y, Nakumura S, Ishimoto T, Takahashi E, Nagano O, Saya H: **Molecular mechanisms regulating dissociation of cell-cell junction of epithelial cells by oxidative stress.** *Genes Cells* 2009, **14**(6):703-716.
26. Pandey G, Srivastava DN, Madhuri S: **A standard hepatotoxic model produced by paracetamol in rat.** *Toxicology International* 2008, **15**(1):69-70.
27. Johar D, Roth JC, Bay GH, Walker JN, Krocak TJ, Los M: **Inflammatory response, reactive oxygen species, programmed (necrotic-like and apoptotic) cell death and cancer.** *Rocz Akad Med Bialymst* 2004, **49**:31-9.
28. Yen HJ, Hsu SH, Tsai CL: **Cytotoxicity and immunological response of gold and silver nanoparticles of different sizes.** *Small* 2009, **5**:1553-1561.
29. Pan Y, Neuss S, Leifert A, Fischler M, Wen F, Simon U, Schmid G, Brandau W, Jahnhen-Dechent W: **Size-dependent cytotoxicity of gold nanoparticles.** *Small* 2007, **3**:1941-1949.
30. De Jong WH, Borm P: **Drug delivery and nanoparticles: applications and hazards.** *Int J Nanomed* 2008, **3**:133-149.
31. Tarnuzzer RW, Colon J, Patil S, Seal S: **Vacancy engineered ceria nanostructures for protection from radiation-induced cellular damage.** *Nano Lett* 2005, **5**:2573-2577.
32. Nel A, Xia T, Madler L, Li NB: **Toxic potential of materials at the nanolevel.** *Science* 2006, **311**:622-627.
33. Chen X, Schluesener HJ, Nanosilver V: **A nanoparticle in medical application.** *Toxicol Lett* 2008, **176**:1-12.
34. De Jong WH, Hagens WI, Krystek P, Burger MC, Sips AJ, Geertsma RE: **Particle size-dependent organ distribution of gold nanoparticles after intravenous administration.** *Biomaterials* 2008, **29**:1912-1919.
35. Florence AT, Hillery AM, Hussain N, Jani PU: **Factors affecting the oral uptake and translocation of polystyrene nanoparticles: histological and analytical evidence.** *J Drug Target* 1995, **3**:65-70.

doi:10.1186/1476-511X-10-147

Cite this article as: Abdelhalim and Jarrar: The appearance of renal cells cytoplasmic degeneration and nuclear destruction might be an indication of GNPs toxicity. *Lipids in Health and Disease* 2011 **10**:147.

Submit your next manuscript to BioMed Central and take full advantage of:

- Convenient online submission
- Thorough peer review
- No space constraints or color figure charges
- Immediate publication on acceptance
- Inclusion in PubMed, CAS, Scopus and Google Scholar
- Research which is freely available for redistribution

Submit your manuscript at
www.biomedcentral.com/submit

