

# Dissecting Cellulitis of the Scalp: A Rare Dermatological Manifestation of Crohn's Disease

Taseen A. Syed, MD<sup>1</sup>, Zain Ul Abideen Asad, MD<sup>1</sup>, George Salem, MD<sup>2</sup>, Kanika Garg, MD<sup>1</sup>, Erin Rubin, MD, FCAP<sup>3</sup>, and Nelson Agudelo, MD<sup>4</sup>

<sup>1</sup>Department of Internal Medicine, University of Oklahoma Health Sciences Center, Oklahoma City, OK

<sup>2</sup>Section of Digestive Diseases & Nutrition, University of Oklahoma Health Sciences Center, Oklahoma City, OK

<sup>3</sup>Section of Pathology, University of Oklahoma Health Sciences Center, Oklahoma City, OK

<sup>4</sup>Section of Infectious Diseases, University of Oklahoma Health Sciences Center, Oklahoma City, OK

## ABSTRACT

Dissecting cellulitis is an inflammatory disease of the skin. We report a case of recurrent dissecting cellulitis in a patient with Crohn's disease. A 31-year-old man with a history of purulent scalp lesions presented with night sweats, weight loss, abdominal pain, and hematochezia. Colonoscopy revealed a diffuse friable mucosa with extensive pseudopolyps. Scalp biopsy demonstrated epidermoid inclusion cysts with granulation tissue and chronic inflammatory cell infiltration, indicative of dissecting cellulitis. The incidence of dissecting cellulitis with Crohn's disease is underreported. This dermatologic condition has a tendency to recur, and considering an underlying disease is key for its appropriate treatment.

## INTRODUCTION

Dissecting cellulitis, also known as perifolliculitis capitis abscedens et suffodiens or Hoffman disease, is an inflammatory disease of the skin. It manifests as perifollicular pustules, keloids, nodules, abscesses, and sinuses that evolve into scarring alopecia. Dissecting cellulitis is included in the follicular inclusion triad along with hidradenitis suppurativa and acne conglobata. Dissecting cellulitis, the least common of the three, can concurrently present with hidradenitis suppurativa or acne conglobata. Dissecting cellulitis has been associated with arthritis, keratitis, and pyoderma gangrenosum.

## CASE REPORT

A 31-year-old man with a history of peptic ulcer disease status post partial gastrectomy 10 years prior and antibiotic-resistant purulent scalp lesions for 2 years presented with 5 days of night sweats, weight loss, abdominal pain, diarrhea, and hematochezia. On evaluation, he had bilateral lower abdominal tenderness in addition to multiple erythematous interconnecting plaques, some boggy with dried yellow crust on the frontal, parietal, and occipital scalp with scant purulent drainage (Figure 1). Relevant lab results were hemoglobin 8.6 g/dL, platelets 365,000/mm<sup>3</sup>, erythrocyte sedimentation rate 52 mm/h, and C-reactive protein 138 mg/L.

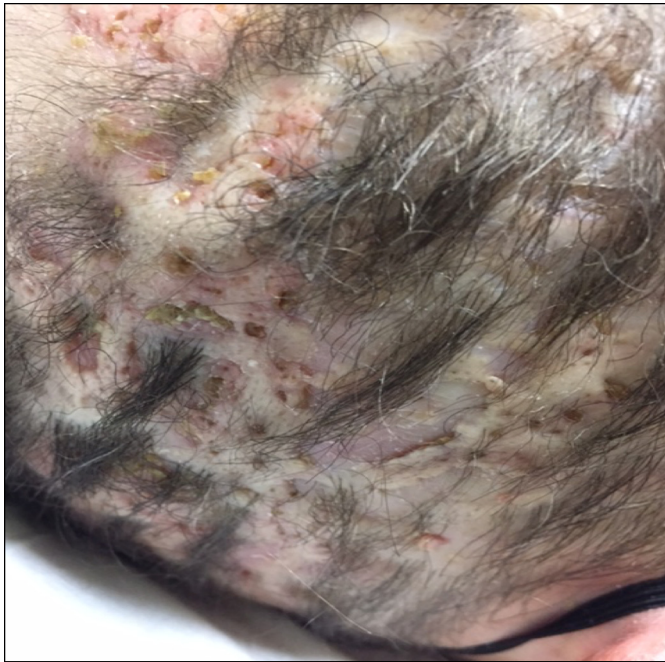
A comprehensive evaluation for infectious causes of diarrhea was unremarkable, including testing for *Clostridium difficile*. An enhanced abdominal computed tomography showed pancolitis. Colonoscopy disclosed a diffuse area of severely friable mucosa with contact bleeding and extensive polyps, most likely representing inflammatory pseudopolyps in the descending colon along with discontinuous areas of nonbleeding ulcerated mucosa in the rectum (Figure 2). Descending colon biopsy showed chronic active colitis and a single dilated crypt expanded with a

ACG Case Rep J 2018;5:e8. doi:10.14309/crj.2018.8. Published online: January 31, 2018.

**Correspondence:** Taseen A. Syed, Department of Internal Medicine, University of Oklahoma Health Sciences Center, 500 Central Park Dr, Oklahoma City, OK, 73105 (taseen-syed@ouhsc.edu).



**Copyright:** © 2018 Syed et al. This work is licensed under a Creative Commons Attribution-NonCommercial-NoDerivatives 4.0 International License. To view a copy of this license, visit <http://creativecommons.org/licenses/by-nc-nd/4.0>.



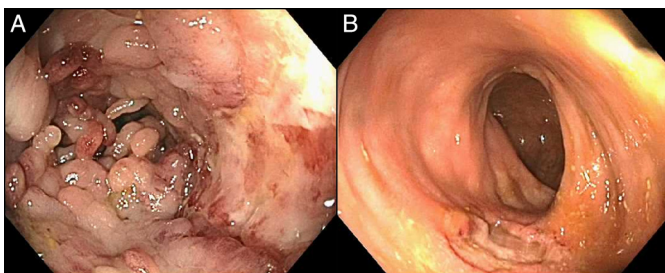
**Figure 1.** Multiple purulent erythematous interconnecting plaques, some boggy with dried, yellow crust on the scalp.

neutrophilic inflammatory infiltrate (crypt abscess; Figure 3). Scalp biopsy revealed epidermoid inclusion cysts, ruptured and inflamed, with granulation tissue and chronic inflammatory cell infiltration with no dysplasia or malignancy, indicative of dissecting cellulitis (Figure 4).

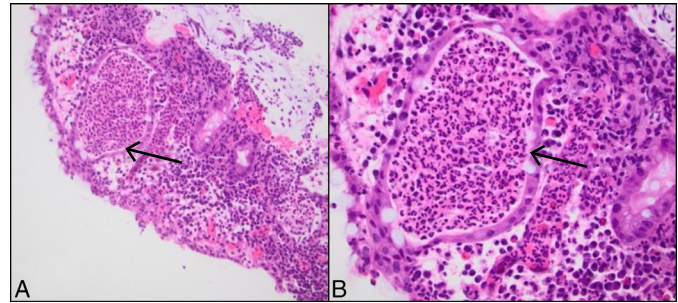
The patient was started on steroids and infliximab induction, and he experienced complete remission of the skin disease and gastrointestinal symptoms. The phenotype of Crohn's disease at the time of diagnosis was A2L2xB1: colonic, non-stricturing, non-fistulizing. Retrospectively, the specimen obtained at time of partial gastrectomy showed small sub-mucosal pseudopolyps and regenerative atypia of the immediately adjacent mucosa, suggestive of Crohn's disease.

**DISCUSSION**

Historically, dissecting cellulitis as a disease entity was first described by Spitz in 1903, who named it "dermatitis follicularis

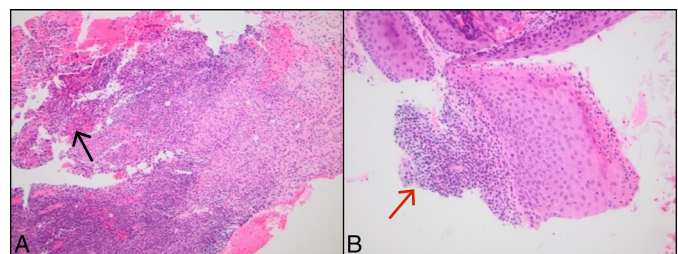


**Figure 2.** Colonoscopy showing (A) pseudopolyps in the descending colon and (B) nonbleeding ulcerated mucosa in the rectum.



**Figure 3.** Descending colonic mucosa biopsy showing chronic active colitis. There is a single dilated crypt expanded with a neutrophilic inflammatory infiltrate or crypt abscess (arrow). (A) 20x magnification. (B) 40x magnification.

capitis et perifolliculitis conglobata." Hoffman used the term "perifolliculitis capitis abscedens et suffodiens," though it is now also reported as Hoffman disease.<sup>1</sup> Dissecting cellulitis has a propensity for occurrence in African-American men 20-40 years of age.<sup>2</sup> It is a chronic disease with multiple remissions and relapses. The pathogenesis is described as follicular hyperkeratosis that leads to formation of plugs and retention of follicular products due to occlusion. The healed lesions can lead to keloid formation. This pathway is common to all of the diseases in the follicular occlusion triad. Histologically, dissecting cellulitis resembles hidradenitis suppurativa, with early lesions characterized by infiltration with dense neutrophils, lymphocytes, histiocytes, and plasma cells, with granulomas, scarring, and fibrosis seen in later stages.<sup>1</sup> In general, the differential diagnosis for dissecting cellulitis is broad and includes tinea capitis, pseudopelade of Brocq, squamous cell carcinoma, metastatic Crohn's disease, and erosive pustular dermatosis of the scalp.<sup>3</sup> Dissecting cellulitis, hidradenitis suppurativa, and acne conglobata are differentiated mainly on their clinical presentation, with dissecting cellulitis affecting the scalp, hidradenitis suppurativa affecting axillary and anogenital regions, and acne conglobata affecting back, buttocks, and chest.<sup>4</sup> Metastatic Crohn's disease, a similar disease entity, is characterized by noncaseating granulomas in the skin,



**Figure 4.** Scalp biopsy revealing ulceration of the overlying epithelium with inflamed granulation tissue and fibrinopurulent debris (black arrow), obliteration of the hair follicles and the sebaceous glands, and squamous epithelium with superficial neutrophilic inflammatory infiltrate (red arrow). Within the dermis there is infiltrate of macrophages, plasma cells, lymphocytes, and neutrophils. (A) 20x magnification. (B) 40x magnification.

but its noncontiguous occurrence with the gastrointestinal tract is a rare manifestation. Although the abscesses in dissecting cellulitis are sterile, it can be associated with secondary bacterial infection. Reported organisms include *Pseudomonas* species, *Staphylococcus epidermidis*, *Propionibacterium acnes*, and *Prevotella intermedia*.<sup>4</sup>

Dissecting cellulitis has been associated with multiple disease entities. In some cases, it may herald the actual clinical manifestations of an underlying disease process. The well-known associations are arthritis, keratitis, pyoderma gangrenosum, keratitis-ichthyosis-deafness syndrome, pilonidal cysts, and osteomyelitis.<sup>4</sup> A rare association with Crohn's disease has been documented; this connection is often missed when reviewing mucocutaneous manifestations of inflammatory bowel disease due to the low incidence of dissecting cellulitis itself, as well as its nonfulminant clinical course and the wide array of differential diagnoses that can mask the appropriate diagnosis.<sup>5,6</sup>

Treatment of dissecting cellulitis has changed significantly over the last decade. Newer treatment options include antibiotics (first-line therapy: ciprofloxacin, clindamycin, rifampin, and trimethoprim/sulfamethoxole) or tumor necrosis factor (TNF) inhibitors (e.g., adalimumab and infliximab). TNF inhibitors can also be used as a bridge to surgery for severe dissecting cellulitis or perianal fistulas in Crohn's disease, which result in faster healing and delayed relapse when used after surgery. Older treatment options included isotretinoin, dapsone, colchicine, and steroids. Some clinicians prefer using steroids (primarily prednisone) as a bridge to success with isotretinoin or other therapies. Zinc sulphate also has documented benefit, but its sole use for the treatment of dissecting cellulitis is not well established. Although topical agents in form of antibiotics, isotretinoin, tacrolimus, and steroids can somewhat control the disease activity, systemic treatments should always be favored for a more therapeutic advantage. If all treatment options fail, more invasive options can be used, such as modern external beam radiation therapy, scalp removal with graft, full x-ray treatment, or carbon dioxide ablation of scalp. Because of their destructive nature and the alternative of newer treatment modalities, invasive procedures are avoided.<sup>3</sup> Interestingly, the treatment options for dissecting cellulitis and Crohn's disease have significant overlap.<sup>7</sup>

The incidence of dissecting cellulitis is underreported, likely because of the diagnostic confusion with other dermatological conditions. In our patient, a possible diagnosis of Crohn's disease was missed at age of 21. Crohn's disease should be considered in patients with dissecting cellulitis. This dermatologic condition has a tendency for recurrence, and considering an underlying disease is key for its appropriate treatment. Treatment with anti-TNF- $\alpha$  can be beneficial for both conditions.

## DISCLOSURES

Author contributions: TA Syed and ZUA Asad wrote the manuscript and reviewed the literature. K. Garg reviewed the literature and collected the images. G. Salem wrote the manuscript. E. Rubin provided the pathology images. N. Aguedelo edited the manuscript and is the article guarantor.

Financial disclosure: None to report.

Informed consent was obtained for this case report.

Received June 27, 2017; Accepted November 22, 2017

## REFERENCES

1. Tchernev G. Folliculitis et perifolliculitis capitis abscedens et suffodiens controlled with a combination therapy: Systemic antibiotics (metronidazole plus clindamycin), dermatosurgical approach, and high-dose isotretinoin. *Indian J Dermatol*. 2011;56(3):318-20.
2. Scheinfeld NS. A case of dissecting cellulitis and a review of the literature. *Dermatol Online J*. 2003;9(1):8.
3. Scheinfeld N. Dissecting cellulitis (perifolliculitis capitis abscedens et suffodiens): A comprehensive review focusing on new treatments and findings of the last decade with commentary comparing the therapies and causes of dissecting cellulitis to hidradenitis suppurativa. *Dermatol Online J*. 2014;20(5):22692.
4. Gaopande VL, Kulkarni MM, Joshi AR, Dhande AN. Perifolliculitis capitis abscedens et suffodiens in a 7 years male: A case report with review of literature. *Int J Trichology*. 2015;7(4):173-75.
5. Ko JS, Uberti G, Napkoski K, Patil DT, Billings SD. Cutaneous manifestations in inflammatory bowel disease: A single institutional study of non-neoplastic biopsies over 13 years. *J Cutan Pathol*. 2016;43(11):946-55.
6. Hindryckx P, Novak G, Costanzo A, Danese S. Disease-related and drug-induced skin manifestations in inflammatory bowel disease. *Expert Rev Gastroenterol Hepatol*. 2017;11(3):203-14.
7. Wilkins T, Jarvis K, Patel J. Diagnosis and management of Crohn's disease. *Am Fam Physician*. 2011;84(12):1365-75.