

# Postoperative diaphragmatic hernia with upside-down stomach: a case report

Journal of International Medical Research

50(8) 1–5


© The Author(s) 2022

Article reuse guidelines:

[sagepub.com/journals-permissions](https://sagepub.com/journals-permissions)

DOI: 10.1177/03000605221115158

[journals.sagepub.com/home/imr](https://journals.sagepub.com/home/imr)

**Masakazu Wakabayashi** , **Shuichi Kobori,**  
**Kana Aoki, Hayato Yoshida, Kou Minoshima,**  
**Tomohiro Kimura, Yoshinori Domoto,**  
**Miki Hosaka, Hideki Ushiku, Kentarou Funatsu**  
**and Kazuo Aisaki**

## Abstract

A 31-year-old man presented to our hospital's Emergency Department with sudden epigastric pain and vomiting. He had undergone endoscopic resection via the retroperitoneal route for a retroperitoneal tumor located in the left diaphragmatic crus of the esophageal hiatus at another hospital 8 months previously. Radiography and computed tomography showed inversion of the stomach beyond the diaphragm into the thoracic cavity, with the gastroesophageal junction serving as the fulcrum point. This finding led to a diagnosis of postoperative diaphragmatic hernia accompanied by an upside-down stomach (UDS). The prolapsed stomach in the thoracic cavity was reduced to the abdominal cavity using laparoscopic surgery. The postoperative course was favorable, and the patient was discharged from the hospital on postoperative day 7. No recurrence has been observed in the past 5 years. The pathological condition of a UDS observed in esophageal hiatal hernias may be found in postoperative diaphragmatic hernias. Laparoscopic surgery for a postoperative diaphragmatic hernia with a UDS is considered a useful surgical procedure. Laparoscopic surgery can simultaneously confirm the viability of the herniated organs, reduce the organs to the abdominal cavity, and close and reinforce the diaphragm.

## Keywords

Upside-down stomach, diaphragmatic hernia, laparoscopic surgery, prolapsed stomach, mesh, suture

Date received: 1 April 2022; accepted: 4 July 2022

Department of Surgery, Sagamihara Kyodo Hospital, 4-3-1 Hashimoto-dai, Midori-ku, Sagamihara-shi, Kanagawa 252-5188, Japan

## Corresponding author:

Masakazu Wakabayashi, Department of Surgery, Sagamihara Kyodo Hospital, 4-3-1 Hashimoto-dai, Midori-ku, Sagamihara-shi, Kanagawa 252-5188, Japan.  
Email: [mw5636@gmail.com](mailto:mw5636@gmail.com)



Creative Commons Non Commercial CC BY-NC: This article is distributed under the terms of the Creative Commons Attribution-NonCommercial 4.0 License (<https://creativecommons.org/licenses/by-nc/4.0/>) which permits non-commercial use, reproduction and distribution of the work without further permission provided the original work is attributed as specified on the SAGE and Open Access pages (<https://us.sagepub.com/en-us/nam/open-access-at-sage>).

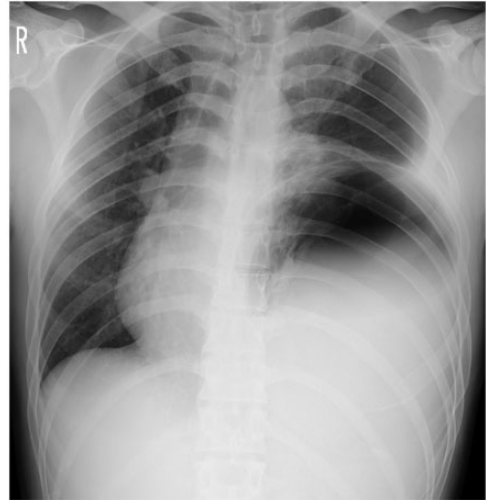
## Introduction

An upside-down stomach (UDS) is a rare type of esophageal hiatal hernia accompanied by gastric volvulus, which causes the stomach to be positioned cranial to the esophagogastric junction.<sup>1</sup> In general, the primary disease is esophageal hiatal hernia, but a UDS occurring after surgery of the diaphragm is extremely rare.

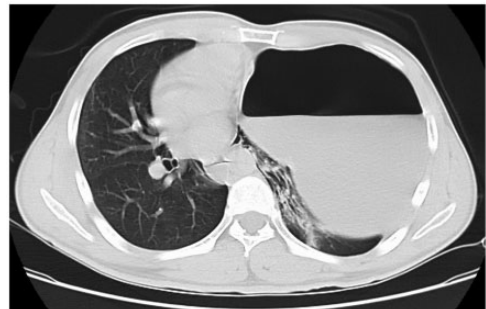We report a case of postoperative diaphragmatic hernia with a UDS that was successfully treated with laparoscopic repair of the hernia. In addition, we performed a brief review of the relevant literature.

## Case report

A 31-year-old man developed sudden epigastric pain and vomiting. Because his symptoms persisted for a couple of hours, he presented to the Emergency Department of our hospital. He had undergone endoscopic resection via the retroperitoneal route for a retroperitoneal tumor located in the left diaphragmatic crus of the esophageal hiatus at another hospital 8 months previously. A postoperative pathological examination showed a benign and cystic tumor. Accelerated respiration and tachycardia were observed, but blood pressure was maintained within the normal range. Radiography and computed tomography (CT) showed that the stomach was inverted beyond the diaphragm, with the gastroesophageal junction serving as the fulcrum point. Almost the entire stomach had prolapsed into the left thoracic cavity (Figures 1 and 2). The patient was admitted with a diagnosis of a postoperative diaphragmatic hernia accompanied by a UDS. With the expectation that the stomach would be returned to its normal position, gastric decompression was performed using a nasogastric tube, and the patient's clinical course was observed. However, there was no considerable change, and gastric fluoroscopy



**Figure 1.** Chest radiograph showing intragastric gas in the left thoracic cavity.



**Figure 2.** Chest computed tomography showing a collapsed left lung and intragastric gas with an air-fluid level in the left thoracic cavity.

showed no flow of contrast agent from the pylorus to the anal side.

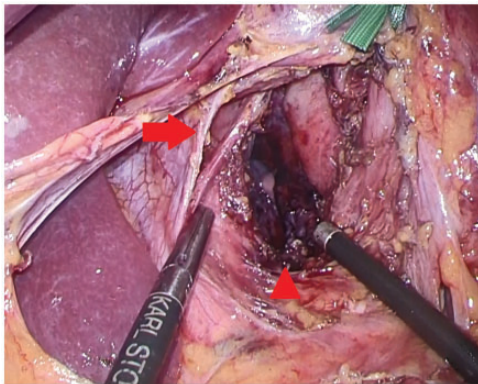
Therefore, laparoscopic surgery was performed. The patient was placed in the open-leg position. A 12-mm port for the camera was set in the umbilical region, a 5-mm port for the left hand of the operator was set in the right lateral abdominal region, and a 12-mm port for the right hand of the operator was set in the left lateral abdominal region. Additionally, a 5-mm port for the assistant was set in the left hypochondriac

region. Intraperitoneal observation showed slightly bloody ascites. Laparoscopic adhesiolysis was performed as much as possible, and the prolapsed stomach in the thoracic cavity was reduced. The hernial orifice measured  $35 \times 25$  mm and was located in the left diaphragm adjacent to the esophageal hiatus (Figure 3). There was no hernial sac, which indicated a pseudohernia, and the left lung was visible. The hernial orifice was closed tightly with 2-0 non-absorbable sutures. Subsequently, a mesh size of  $8 \times 8$  cm for intraperitoneal placement (Ventralight ST<sup>®</sup>; C.R. Bard, Warwick, RI, USA) was trimmed to a U-shaped structure and fixed with sutures around the esophagus to reinforce the diaphragm (Figure 4). The clinical course was favorable, and the patient was discharged on postoperative day 7. No recurrence has been observed in the past 5 years.

The reporting of this study conforms to the CARE guidelines.<sup>2</sup> The patient provided consent for treatment, and all of the patient's details have been de-identified.

## Discussion

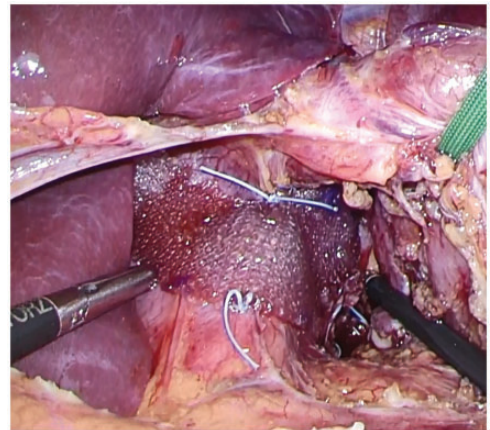
No cases of postoperative diaphragmatic hernia showing a UDS were retrieved



**Figure 3.** Operative findings. A normal esophageal hiatus (arrow) and an adjacent hernial orifice (arrowhead) can be seen during laparoscopic surgery.

from the PubMed database using the keywords “postoperative diaphragmatic hernia” and “upside down stomach.” Therefore, to the best of our knowledge, this is the first report of a case of this type of hernia. Patients with esophageal hiatal hernia have a chronic clinical course. The primary complaints of these patients are reflux esophagitis-related anorexia, gastrointestinal symptoms, such as heartburn and epigastric pain, and respiratory symptoms due to compression from the hernia content, often requiring surgery. Surgery should be performed immediately in such a condition.<sup>3</sup> In our case, the patient had an acute course and presented to the hospital with the chief complaint of respiratory symptoms due to compression.

There is no established treatment for postoperative diaphragmatic hernia with a UDS, but we consider that treatment similar to that for esophageal hiatal hernia should be performed. Therefore, the stomach with hernia should be returned to the normal anatomical position, and the diaphragmatic hernia should be closed with sutures and covered with a mesh. With



**Figure 4.** Placement of the mesh. An  $8 \times 8$ -cm, U-shaped, intra-abdominal mesh is used after closing the hernial orifice with non-absorbable sutures.

regard to surgical approaches, the surgical site is likely to be deep, and a large incision is required for thoracotomy or laparotomy; therefore, laparoscopy and thoracoscopy are useful.

Laparoscopic surgery for esophageal hiatal hernia with a UDS is superior to open surgery in terms of postoperative complications and the length of the hospital stay.<sup>4</sup> The abdominal and thoracic approaches have their advantages and disadvantages. When there is adhesion of the hernia content, including the stomach, adhesiolysis is easier with the thoracic approach than with the abdominal approach in the thoracic cavity. In addition, closure with sutures is relatively easy because there is a wide surgical space in the thoracic cavity after reduction of the hernia content. However, when a detailed examination or resection of the herniated intra-abdominal organ is necessary, the abdominal approach is superior to the thoracic approach.

Hernia repair procedures include the use of mesh, reefing of the hernial orifice, fundoplication, and gastropexy. Several studies have shown that the recurrence rate can be reduced with the use of a mesh compared with that without the use of a mesh. Hashemi et al.<sup>5</sup> reported a recurrence rate of 40% when laparoscopic surgery was performed for a giant esophageal hiatal hernia without using a mesh. Frantzides et al.<sup>6</sup> performed a randomized, controlled trial on laparoscopic surgery for esophageal hiatal hernia with a hernial orifice of  $\geq 8$  cm. They reported that the recurrence rate was significantly improved from 22% in the non-mesh group to 0% in the mesh group. The major complications of a mesh include damage to the surrounding organs due to the mesh, esophageal stenosis, esophageal mucosal ulcers, severe adhesion, scarring, and infection.<sup>7</sup> Koch et al.<sup>8</sup> used a composite mesh in 59 patients and reported no mesh-related complications. The use of a

mesh is not necessary for all cases, and selection should be made for individual cases with consideration of the size of the hernial orifice and fragility of the tissue.

In esophageal hiatal hernias with a UDS, concurrent reflux esophagitis is often observed, and in such cases, fundoplication is recommended.<sup>9</sup> Generally, the Nissen and Toupet methods are selected, but the Toupet method is associated with a lower incidence of dysphagia in the early postoperative period.<sup>10</sup>

Laparoscopy was selected for our case, and a mesh that is usually used for esophageal hiatal hernia was used in addition to closure of the hernial orifice with a non-absorbable suture. No fundoplication was performed, and only a part of the gastric wall was fixed to the diaphragm using sutures. Our patient was young and had no symptoms of reflux esophagitis before sudden onset and hospital admission, and he had a postoperative diaphragmatic hernia, not an esophageal hiatal hernia. Therefore, we considered that suturing and covering of the hernial orifice by a mesh would be sufficient for the treatment of postoperative diaphragmatic hernia. This procedure resulted in a favorable clinical course.

Although further accumulation of cases is required, laparoscopic surgery using hernial orifice covering and a mesh is considered useful for treating postoperative diaphragmatic hernias accompanied by a UDS.

#### **Declaration of conflicting interest**

The authors declare that there is no conflict of interest.


#### **Ethics statement**

The Institutional Ethics Review Board of Sagamihara Kyodo Hospital approved this study. Written informed consent was obtained from the patient for the publication of this case report and the accompanying images.

## Funding

This research received no specific grant from any funding agency in the public, commercial, or not-for-profit sectors.

## ORCID iD

Masakazu Wakabayashi  <https://orcid.org/0000-0002-8184-5544>

## References

1. Bettex M and Kuffer F. Long-term results of fundoplication in hiatus hernia and cardioesophageal chaliasia in infants and children. Report of 112 consecutive cases. *J Pediatr Surg* 1969; 4: 526–530.
2. Gagnier JJ, Kienle G, Altman DG, et al; CARE Group. The CARE guidelines: consensus-based clinical case reporting guideline development. *Headache* 2013; 53: 1541–1547.
3. Geha AS, Massad MG, Snow NJ, et al. A 32-year experience in 100 patients with giant paraesophageal hernia: The case for abdominal approach and selective antireflux repair. *Surgery* 2000; 128: 623–630.
4. Luketich JD, Raja S, Fernand HC, et al. Laparoscopic repair of giant paraesophageal hernia: 100 consecutive cases. *Ann Surg* 2000; 232: 608–618.
5. Hashemi M, Peters JH, DeMeester TR, et al. Laparoscopic repair of large type III hiatal hernia: Objective followup reveals high recurrence rate. *J Am Coll Surg* 2000; 190: 553–561.
6. Frantzides CT, Madan AK, Carlson MA, et al. A prospective, randomized trial of laparoscopic polytetrafluoroethylene (PTFE) patch repair vs simple cruroplasty for large hiatal hernia. *Arch Surg* 2002; 137: 649–652.
7. Stadlhuber RJ, Sherif AE, Mittal SK, et al. Mesh complications after prosthetic reinforcement of hiatal closure: A 28-case series. *Surg Endosc* 2009; 23: 1219–1226.
8. Koch OO, Asche KU, Berger J, et al. Influence of the size of the hiatus on the rate of reherniation after laparoscopic fundoplication and refundoplication with mesh hiatoplasty. *Surg Endosc* 2011; 25: 1024–1030.
9. Katkhouda N, Mavor E, Achanta K, et al. Laparoscopic repair of chronic intrathoracic gastric volvulus. *Surgery* 2000; 128: 784–790.
10. Strate U, Emmermann A, Fibbe C, et al. Laparoscopic fundoplication: Nissen versus Toupet two-year outcome of a prospective randomized study of 200 patients regarding preoperative esophageal motility. *Surg Endosc* 2008; 22: 21–30.