



ORIGINAL ARTICLE

## Facial paralysis after superficial parotidectomy: analysis of possible predictors of this complication<sup>☆</sup>



Renato Fortes Bittar\*, Homero Penha Ferraro, Marcelo Haddad Ribas, Carlos Neutzling Lehn

Hospital do Servidor Público Estadual (IAMSPE), São Paulo, SP, Brazil

Received 9 June 2015; accepted 25 August 2015

Available online 19 December 2015

### KEYWORDS

Salivary gland neoplasms;  
Parotidectomy;  
Superficial parotidectomy;  
Facial nerve;  
Facial paralysis

### Abstract

**Introduction:** Salivary gland tumors represent 3–10% of all head and neck neoplasms. These tumors occur predominantly in major salivary glands. The parotid gland is affected most often, ranging from 36.6% to 83%. The pleomorphic adenoma comprises 45–60% of all salivary gland tumors. Several surgical approaches have been described to treat this tumor. Lesion of the facial nerve is one of the most serious complications that can occur after parotid gland surgery. **Objectives:** To determine possible predictive factors related to the occurrence of peripheral facial paralysis (PFP) after superficial parotidectomy in the surgical treatment of the pleomorphic adenomas of the parotid gland.

**Methods:** This was a primary, observational, case-control study performed through the revision of patients' charts and histopathological reports. Data was obtained from 1995 to 2014. The analyzed events were: tumor's length and depth; duration of the disease referred by the patient (more than 1, 5 or 10 years); primary or secondary surgical approach.

**Results:** The analysis showed that tumor lengths equal or superior to 3.0 cm were a risk factor of PFP with an odds ratio of 3.98 ( $p=0.0310$ ). Tumor depths equal or superior to 2.0 cm were also a risk factor with an odds ratio of 9.5556 ( $p=0.0049$ ). When the tested event was secondary surgery to recurrent tumors we have found an odds ratio of 6.7778 ( $p=0.0029$ ).

**Conclusion:** Tumors with 3.0 cm or more in length and/or 2.0 cm or more in depth have a significant higher risk of facial nerve injury. Secondary surgery to recurrent tumors also has a much higher risk of evolving with facial palsy after superficial parotidectomy.

© 2015 Associação Brasileira de Otorrinolaringologia e Cirurgia Cérvico-Facial. Published by Elsevier Editora Ltda. This is an open access article under the CC BY license (<http://creativecommons.org/licenses/by/4.0/>).

<sup>☆</sup> Please cite this article as: Bittar RF, Ferraro HP, Ribas MH, Lehn CN. Facial paralysis after superficial parotidectomy: analysis of possible predictors of this complication. Braz J Otorhinolaryngol. 2016;82:447–51.

\* Corresponding author.

E-mails: [renatobittar@yahoo.com](mailto:renatobittar@yahoo.com), [rbittar@gmail.com](mailto:rbittar@gmail.com) (R.F. Bittar).

**PALAVRAS-CHAVE**

Neoplasias de glândulas salivares;  
Parotidectomia;  
Parotidectomia superficial;  
Nervo facial;  
Paralisia facial

**Paralisia facial após parotidectomia superficial: análise de possíveis preditivos dessa complicação****Resumo**

**Introdução:** Os tumores de glândulas salivares representam de 3 a 10% de todas as neoplasias de cabeça e pescoço. Esses tumores ocorrem predominantemente nas glândulas salivares maiores. A glândula parótida é afetada na maioria das vezes, variando de 36,6 a 83%. O adenoma pleomórfico abrange 45–60% de todos os tumores de glândulas salivares. Diversas abordagens cirúrgicas foram descritas para o tratamento desse tumor. A lesão do nervo facial é uma das complicações mais graves que podem ocorrer após cirurgia de glândula parótida.

**Objetivos:** Determinar possíveis fatores preditivos relacionados à ocorrência de paralisia facial periférica (PFP) após parotidectomia superficial no tratamento cirúrgico de adenomas pleomórficos de glândula parótida.

**Método:** Estudo preliminar, observacional, de caso-controle, realizado por meio de revisão dos prontuários de pacientes e laudos histopatológicos. Os dados foram obtidos no período de 1995–2014. Os eventos analisados foram o tamanho do tumor no maior diâmetro e a profundidade, o tempo de doença referido pelo paciente (mais de 1, 5 ou 10 anos) e a abordagem cirúrgica primária ou secundária.

**Resultados:** A análise mostrou que o tamanho do tumor igual ou superior a 3,0 cm foi um fator de risco para PFP, com um razão de chance de 3,98 ( $p=0,0310$ ). A profundidade do tumor igual ou superior a 2,0 cm também foi um fator de risco, com uma razão de chance de 9,5556 ( $p=0,0049$ ). Quando o evento testado foi cirurgia secundária para tumores recorrentes, encontramos uma razão de chance de 6,7778 ( $p=0,0029$ ).

**Conclusão:** Os tumores de 3,0 cm ou mais de comprimento e/ou 2,0 cm ou mais de profundidade apresentam um risco significativamente maior de lesão do nervo facial. A cirurgia secundária para tumores recorrentes também apresenta um risco maior de evoluir com paralisia facial após parotidectomia superficial.

© 2015 Associação Brasileira de Otorrinolaringologia e Cirurgia Cérvico-Facial. Publicado por Elsevier Editora Ltda. Este é um artigo Open Access sob uma licença CC BY (<http://creativecommons.org/licenses/by/4.0/>).

**Introduction**

Salivary gland tumors represent 3–10% of all head and neck neoplasms.<sup>1</sup> These tumors occur predominantly in major salivary glands.<sup>2,3</sup>

The parotid gland is affected most often, ranging from 36.6% to 83%. Malignant tumors are a minority, occurring in 15–32% of cases.<sup>1,4,5</sup>

The most common malignant and benign tumors are the mucoepidermoid carcinoma and the pleomorphic adenoma, respectively.<sup>6,7</sup>

The pleomorphic adenoma comprises 45–60% of all salivary gland tumors. Approximately 80% occur in the parotid gland, usually in the inferior pole of the superficial lobe; however, less frequently, it can occur at the deep lobe or in the accessory parotid tissue.<sup>8</sup>

Several surgical approaches have been described to treat this tumor. In 1895, Senn described enucleation as the technique of choice. However, tumor removal was incomplete with an unacceptable rate of recurrence.<sup>9</sup>

Total parotidectomy removes all gland tissue lateral and medial to facial nerve, whereas superficial parotidectomy removes parotid gland lateral to the facial nerve. In extracapsular dissection, it is not performed any dissection of the facial nerve.<sup>8,10–14</sup>

Lesion of the facial nerve is one of the most serious complications that can occur in parotid gland surgery. It is estimated that 30–65% of all patients experience some sort of transient facial weakness, and 3–6% evolve with permanent dysfunction resulting in significant impact in the quality of life.<sup>14</sup>

The main purpose of this study was to determine possible predictive factors related to the occurrence of peripheral facial paralysis after superficial parotidectomy in the surgical treatment of the pleomorphic adenomas of the parotid gland.

**Methods**

This was a primary, observational, case-control study performed through the revision of patients' charts and histopathological reports. Data was obtained from 1995 to 2014. Patient's names were not retrieved; all information was obtained through hospital's registration numbers.

The analyzed events were: tumor's length and depth; duration of the disease referred by the patient (more than 1, 5 or 10 years); primary or secondary surgical approach. The dimensions evaluated were obtained from the histopathological reports and not from the clinical staging, to give a more precise value.

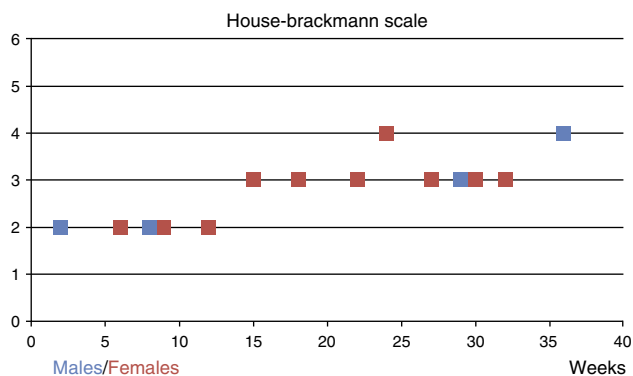


Chart 1. Facial paralysis grade versus elapsed time until complete recovery.

**Figure 1** Facial paralysis grade versus elapsed time until complete recovery.

We divided the patients into groups according to the studied event:

**Tumor length**

*Event analyzed:* tumor length  $\geq 0.5$  cm, 1.0 cm, 1.5 cm, 2.0 cm, 2.5 cm or  $\geq 3.0$  cm.

*Outcome:* Peripheral facial paralysis.

*Cases:* Patients who underwent superficial parotidectomy with tumor length greater than previously referred measures.

*Controls:* Patients who underwent superficial parotidectomy with tumor length smaller than previously referred measures.

**Tumor depth**

*Event analyzed:* tumor depth  $\geq 0.5$  cm, 1.0 cm, 1.5 cm or 2.0 cm.

*Outcome:* Peripheral facial paralysis.

*Cases:* Patients who underwent superficial parotidectomy with tumor depth greater than previously referred measures.

*Controls:* Patients who underwent superficial parotidectomy with tumor depth smaller than previously referred measures.

**Recurrence of the disease**

*Event analyzed:* secondary surgery to treat recurrent tumor.

*Outcome:* Peripheral facial paralysis.

*Cases:* Patients who underwent superficial parotidectomy with a recurrence of the tumor from previous surgery.

*Controls:* Patients who underwent superficial parotidectomy for a primary tumor.

**Duration of the disease**

*Event analyzed:* Time referred by the patient from the moment the lesion was noticed until surgical treatment.

*Outcome:* Peripheral facial paralysis.

**Table 1** Case-control table – tumor’s length.

Length	Facial paralysis	
	Yes	No
$\geq 3.0$ cm	10	27
$< 2.9$ cm	4	43

*Cases:* Patients with duration of the disease superior to 1, 5 or 10 years.

*Controls:* Patients with duration of the disease inferior to 1, 5 or 10 years.

Facial paralysis was classified and graduated according to House-Brackmann’s scale (HBS). Patients were evaluated at the first and seventh postoperative days; first, third and sixth months after surgery. And, in the first year after surgery.

All patients whose charts and histopathological reports did not fulfill these criteria were excluded from the study. Patients who have had any kind of facial motricity impairment previous to surgery were also excluded.

Data was then analyzed to calculate odds ratio, confidence interval, z-statistic, and significance level ( $p < 0.05$ ).

**Results**

During the studied period 219 patients were submitted to surgical approach in the parotid gland; 157 were due to pleomorphic adenoma.

After excluding those submitted to total parotidectomy and those whose information was incomplete there was a total of 84 patients who underwent superficial parotidectomy.

Males were 28 patients and females, 56. The average age was 56.7 years (17–89). Average length was 2.892 cm (0.8–6.0 cm) and average depth was 1.880 cm (0.5–3.2 cm). The right side was affected in 46 cases, and the left side, in 38 cases.

Facial paralysis occurred in 14 out of 84 patients (16.66%), four males and ten females.

Facial paralysis was graded according to HBS. Five patients had an HBS II, seven HBS III and two HBS IV. None was classified as HBS V or VI.

Time elapsed from initial paralysis to complete recovery was evaluated in weeks. One patient with HBS II had full recovery within two weeks. On the other hand, an HBS IV patient had full recovery only on the 36th week. No patient remained with facial paralysis after 36 weeks. Medium time until full recovery was 19.19 weeks (Fig. 1).

To evaluate tumor’s dimensions several values were sequentially tested in a 0.5 cm interval. Regarding tumor’s length we have found no statistical significance when tumor’s length was less than 2.5 cm; however, when a 3.0 cm cutoff point was set up we have found an odds ratio of 3.98 with a confidence interval of 1.1345–13.9728 ( $p = 0.0310$ ) (Table 1).

The same was done with tumor’s depth, and with a 2.0 cm depth we have found an odds ratio of 9.5556 with a confidence interval of 1.9832–46.0422 ( $p = 0.0049$ ) (Table 2).

When the tested event was secondary surgery to recurrent tumors we have found an odds ratio of 6.7778 with

**Table 2** Case-control table – tumor's depth.

Depth	Facial paralysis	
	Yes	No
≥2.0 cm	12	27
<1.9 cm	2	43

**Table 3** Case-control table – primary versus secondary surgery.

	Facial paralysis	
	Yes	No
Secondary	7	9
Primary	7	61

**Table 4** Case-control table – duration of the disease (1 year).

	Facial paralysis	
	Yes	No
≥1 year	12	57
<1 year	2	13

**Table 5** Case-control table – duration of the disease (5 years).

	Facial paralysis	
	Yes	No
≥5 year	0	11
<5 year	14	59

**Table 6** Case-control table – duration of the disease (10 years).

	Facial paralysis	
	Yes	No
≥10 year	0	4
<10 year	14	66

a confidence interval of 1.9227 to 23.8928 ( $p=0.0029$ ) (Table 3).

Considering the duration of the disease, the evaluated parameters were more than 1, 5 and 10 years. We have found odds ratios of 1.3684 with a confidence interval of 0.2725–6.8709 ( $p=.7032$ ), 0.1784 with a confidence interval of 0.0099–3.2072 ( $p=0.2423$ ), and 0.5096 with a confidence interval of 0.0260–9.9975 ( $p=0.6571$ ), respectively (Tables 4–6).

## Discussion

This was a retrospective, case-control study that analyzed a significant number of patients and used the pleomorphic adenoma's clinical and morphological features to determine

possible predictive factors of facial paralysis after superficial parotidectomy.

To the best of our knowledge, we have found no previous similar study in the reviewed literature.

The exclusion of doubtful data and the usage of measures obtained from high quality clinical and histopathological reports made the evaluation very precise and reliable.

In this study, the surgeries were performed by residents under the strict supervision of a senior Head and Neck surgeon. Patients with larger and/or deeper or recurrent tumors were operated by senior surgeons.

This may be considered a bias of the study since more than one surgeon performed the surgeries; however, this fact reflects best the reality of most medical residence centers in Brazil. Therefore, this information could be useful to predict and best prevent this undesirable outcome by the hands of training residents.

Intraoperative neural monitoring (IONM) was not routinely used due to hospital's limitation quota. Therefore, its use was reserved to recurrent tumors.

Females were 56 cases, and males, 28. Of the 14 patients with postoperative facial paralysis, 10 were females and four were males. No permanent lesions were reported, and all patients were fully recovered within 36 weeks. No severe facial paralysis (HBS V or VI) was also reported during the studied period.

Transient facial palsy remains the most common complication in parotid gland tumor<sup>14</sup> and an important factor of distress both to patients and the surgical team. Permanent palsy is seen in 0–19% of the cases.<sup>15–21</sup>

If the lesion is permanent the consequences are tremendous, resulting in possible cornea ulcers, facial asymmetry, dysphasia, and drooling.

Superficial parotidectomy remains the most efficient technique yet available, allowing the surgeon through the complete facial nerve dissection, with better chances of preserving its function.<sup>22</sup>

It is still a matter of debate whether the incidence of facial paralysis is higher after malignant tumors resection, due to a more aggressive surgical approach,<sup>23</sup> or after benign lesions, usually with a longer duration of the disease, associated with tumor's adherence and adjacent inflammatory process.<sup>19</sup>

It is quite intuitive to relate the increase of tumor's dimension to a higher incidence of complications. In this study, we have demonstrated that tumors with 3.0 cm or more in length and 2.0 cm or more in depth have a significant risk of evolving with facial paralysis. This should be taken into account in the pre-operative evaluation, and consequently, demand a much more careful technique during nerve dissection.

All of the 16 cases of recurrence occurred after enucleation of the lesion performed elsewhere, since this approach is not preconized at our institution. As seen in this study, the secondary surgery has a much higher risk of resulting in facial palsy, surely due to perilesional inflammation, fibrosis and lack of anatomical landmarks.

Surgery performed after a previous approach of the parotid gland has an odds ratio of 6.7778 with a confidence interval of 1.9227–23.8928 ( $p=0.0029$ ). This should be recognized when performing the primary surgery, demanding a curative approach to avoid a secondary and, therefore,

more risky surgery and during the secondary surgery itself, since the risks of facial nerve injury are significantly higher.

On the other hand, duration of the disease had no correlation with a higher risk of facial nerve injury during superficial parotidectomy. The calculated odds ratios were 1.3684 with a confidence interval of 0.2725–6.8709 ( $p=0.7032$ ); 0.1784 with a confidence interval of 0.0099–3.2072 ( $p=0.2423$ ), and 0.5096 with a confidence interval of 0.0260–9.9975 ( $p=0.6571$ ), with 1, 5 or 10 years of disease, respectively.

One might expect to find a higher risk of facial nerve injury with longer disease period. The explanation why that was not found in this study remains unclear. Further studies focusing at how the microscopic ultrastructure of tumor's boundaries changes over time might raise more information on this matter.

## Conclusion

Facial nerve injury during superficial parotidectomy remains the most common and most feared complication.

In this study, we have found that tumors with 3.0 cm or more in length and/or 2.0 cm or more in depth have a significant higher risk of facial nerve injury.

Secondary surgery to recurrent tumors also has a much higher risk of evolving with facial palsy after superficial parotidectomy.

## Conflicts of interest

The authors declare no conflicts of interest.

## References

1. Foresta E, Torroni A, Di Nardo F, de Waure C, Poscia A, Gasparini G, et al. Pleomorphic adenoma and benign parotid tumors: extracapsular dissection vs superficial parotidectomy – review of literature and meta-analysis. *Oral Surg Oral Med Oral Pathol Oral Radiol.* 2014;117:663–76.
2. Loyola AM, Araújo VC, de Sousa SOM, de Araújo NS. Minor salivary gland tumors. A retrospective study of 164 cases in a Brazilian population. *Oral Oncol Eur J Cancer.* 1995;31:197–201.
3. Nanda KDP, Mehta A, Nanda J. Fine-needle aspiration cytology: a reliable tool in the diagnosis of salivary gland lesions. *J Oral Pathol Med.* 2012;41:106–12.
4. Kayembe MK, Kalengayi MM. Salivary gland tumors in Congo (Zaire). *Odontostomatol Trop.* 2002;25:19–22.
5. Satko I, Stanko P, Longauerova I. Salivary gland tumors treated in the stomatological clinics in Bratislava. *J Craniomaxillofac Surg.* 2000;28:56–61.
6. Long-Jiang L, Yi L, Yu-ming W, Hong-wei Z. Clinical analysis of salivary gland tumor cases in West China in past 50 years. *Oral Oncol.* 2008;44:187–92.
7. Lima SS, Soares AF, de Amorim RF, Freitas R, de A. Epidemiologic profile of salivary gland neoplasms: analysis of 245 cases. *Braz J Otorhinolaryngol.* 2005;71:335–40.
8. Zbären P, Vander Poorten V, Witt RL, Woolgar JA, Shaha AR, Triantafyllou A, et al. Pleomorphic adenoma of the parotid: formal parotidectomy or limited surgery? *Am J Surg.* 2013;205:109–18.
9. Senn N. *The pathology and surgical treatment of tumors.* Philadelphia, PA: W.B. Saunders; 1895.
10. Witt RL. The significance of the margin in parotid surgery for pleomorphic adenoma. *Laryngoscope.* 2002;112:2141–54.
11. Klintworth N, Zenk J, Koch M, Iro H. Postoperative complications after extracapsular dissection of benign parotid lesions with particular reference to facial nerve function. *Laryngoscope.* 2010;120:484–90.
12. Roh JL, Kim HS, Park CI. Randomized clinical trial comparing partial parotidectomy versus superficial or total parotidectomy. *Br J Surg.* 2007;94:1081–7.
13. Malard O, Wagner R, Joubert M, Delemazure AS, Rio E, Durand N, et al. Prognostic factors for secondary recurrence of pleomorphic adenoma: a 20-year, retrospective study. *J Laryngol Otol.* 2013;127:902–7.
14. Zhang SS, Ma DQ, Guo CB, Huang MX, Peng X, Yu GY. Conservation of salivary secretion and facial nerve function in partial superficial parotidectomy. *Int J Oral Maxillofac Surg.* 2013;42:868–73.
15. Laccourreye H, Laccourreye O, Cauchois R, Jouffre V, Ménard M, Brasnu D. Total conservative parotidectomy for primary benign pleomorphic adenoma of the parotid gland: a 25-year experience with 229 patients. *Laryngoscope.* 1994;104:1487–94.
16. Witt RL. Facial nerve function after partial superficial parotidectomy: an 11-year review (1987–1997). *Otolaryngol Head Neck Surg.* 1999;121:210–3.
17. Koch M, Zenk J, Iro H. Long-term results of morbidity after parotid gland surgery in benign disease. *Laryngoscope.* 2010;120:724–30.
18. Guntinas-Lichius O, Klusmann JP, Wittekindt C, Stennert E. Parotidectomy for benign parotid disease at a university teaching hospital: outcome of 963 operations. *Laryngoscope.* 2006;116:534–40.
19. Gaillard C, Périé S, Susini B, St Guily JL. Facial nerve dysfunction after parotidectomy: the role of local factors. *Laryngoscope.* 2005;115:287–91.
20. Dulguerov P, Marchal F, Lehmann W. Postparotidectomy facial nerve paralysis: possible etiologic factors and results with routine facial nerve monitoring. *Laryngoscope.* 1999;109:754–62.
21. O'Brien CJ, Malka VB, Mijailovic M. Evaluation of 242 consecutive parotidectomies performed for benign and malignant disease. *Aust N Z J Surg.* 1993;63:870–7.
22. Johnson JT, Ferlito A, Fagan JJ, Bradley PJ, Rinaldo A. Role of limited parotidectomy in management of pleomorphic adenoma. *J Laryngol Otol.* 2007;121:1126–8.
23. Ellingson TW, Cohen JI, Andersen P. The impact of malignant disease on facial nerve function after parotidectomy. *Laryngoscope.* 2003;113:1299–303.