

Penetrating injury caused by a long iron bar: A case report

Seyithan Ozaydin,¹ Aykan Gulleroglu,² Birgul Karaaslan,¹ Suleyman Celebi,¹ Cemile Besik,¹
Melike Korkmaz Toker,² Serdar Sander¹

¹Department of Pediatric Surgery, Kanuni Sultan Suleyman Training and Research Hospital, Istanbul, Turkey

²Department of Anesthesiology and Reanimation, Kanuni Sultan Suleyman Training and Research Hospital, Istanbul, Turkey

ABSTRACT

Foreign bodies that strike the body with their long edges can cause severe problems. From the hospitalization of the patients to the removal of the foreign body and from surgery to follow-up, working as a team in a well-organized manner is necessary. In the present research, we present our experience, including the hospitalization, initial assessment by the emergency team, examination, and treatment plan, of a pediatric patient who had a 12-m long iron bar that traversed from the right side of the anus to the loin; this impalement happened while the patient was sliding through a snow-covered street, and the patient had to wait on the snow until the fire department arrived and cut the iron bar.

Keywords: Iron bar; perineal impalement injuries; pediatric patient.

Impalement and anorectal injuries in children are rarely observed, but they have high mortality and morbidity rates [1, 2]. While it is advantageous for the patient who had a foreign body, such as iron bar, which traverses a long distance within the body does not injure vital organs, it is disadvantageous that both the hospital and the fire department that are called for help do not have appropriate tools, which do not do harm to the patient and operating room, to cut the bar within safety measures.

Herein we present our experience including the examination, treatment, and follow-up of a pediatric patient who was admitted with a construction iron bar traversing from the perineum to the loin through the sacrum.

CASE REPORT

An 11-year-old boy was sliding in the supine position when an 18-mm wide, 12-m long construction iron bar entered his body from the right site of the anus and exited from the loin; he had to wait for an hour until the fire department arrived and cut the iron bar into a 140 cm piece. He was taken to the nearest state hospital and was then transferred to the emergency service of our hospital (Fig. 1). The patient was met by a team already present in the emergency service as they were informed by the 112 emergency services operator. He was slightly hypothermic and had an intermediate overall condition, with no



Received: April 04, 2017 Accepted: April 28, 2017 Online: January 11, 2018

Correspondence: Dr. Seyithan OZAYDIN. Kanuni Sultan Suleyman Egitim ve Arastirma Hastanesi, Cocuk Cerrahisi Klinigi, Istanbul Turkey.
Tel: +90 212 - 404 15 00 - 13 69 e-mail: seyithanozaydin@gmail.com

© Copyright 2018 by Istanbul Provincial Directorate of Health - Available online at www.northclinist.com

active hemorrhaging and a normal abdomen; however, he had difficulty in breathing. Chest and abdominal x-ray examinations were performed under the supervision of Pediatric Surgery, Orthopedics, Brain Surgery, Anesthesiology, and Radiology departments. Later, because the patients' pain and breathing difficulty increased, the patient was successfully intubated on a stretcher he was lying in the supine position; computed tomography (CT) was performed afterward (Figs. 2 a,b).

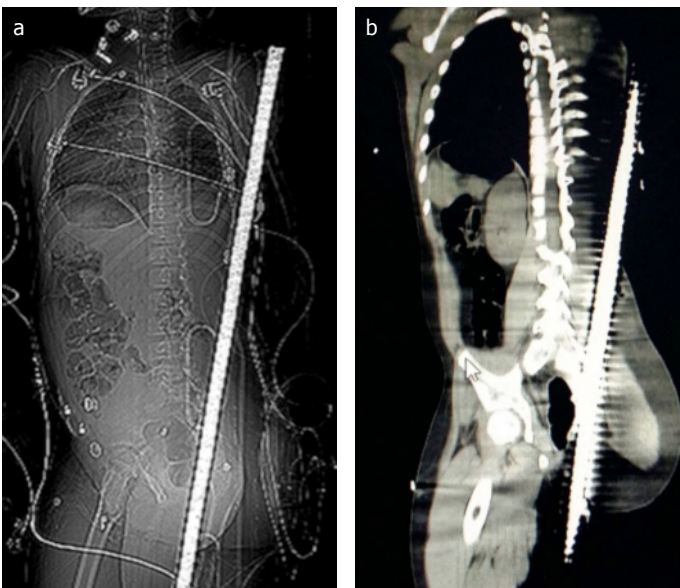
No abdominal or chest injury was detected in the CT image, and considering the possibility of rectosigmoid/retroperitoneal injury, laparotomy was performed to remove the construction iron bar in a controlled manner. Meanwhile, tetanus vaccination was performed and antibiotic (ampicillin/sulbactam, amikacin, ornidazole) treatment was started. The patient was very carefully placed in the supine position, and his abdominal re-

gion was opened. No pathological findings other than a hematoma that was 5–6 cm in diameter at the sigmoid colon mesentery were detected; his abdominal skin was then closed, and he was carefully placed in the face-down position.

The main goal of the intervention was to shorten the iron bar to avoid more injuries to the tissues while removing the 18-mm wide ribbed construction iron bar; however, as appropriate tools to cut an iron bar was not available at our hospital, the fire department was urgently called. The fire department reported that they had three types of bar cutters: the scissor-type cutter would cause more injuries to the patient and the other was a spiral cutter that cannot cut such a bar; therefore, these two cutters were not suitable for this task. The third type was a spiral-type cutter that can cut the iron by transmitting heat. Inevitably, this cutter was used, and cold water was

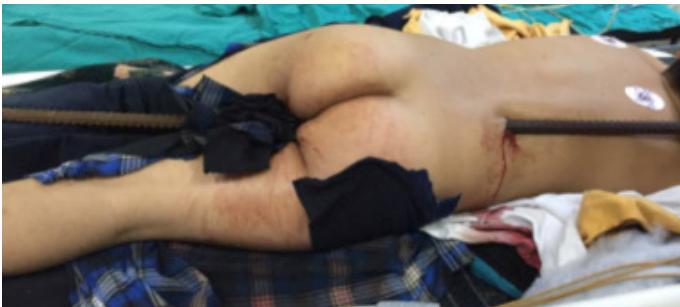

FIGURE 1. Penetrating injury caused by construction iron.



FIGURES 2A,B. Computed tomography images in supine position.



FIGURES 3A,B. The shortened 140-cm iron bar was pulled in a controlled manner and removed.

continuously poured to prevent the tissues from burning. The shortened iron bar was pulled out in a controlled manner and removed (Figs. 3 a,b). However, we later realized that oxygen and nitrous oxide container tubes for administering anesthesia should not be around while working with these cutters as they require high heat and pressure and that their presence almost caused an explosion.

After removing the shortened iron bar, a light exudate containing bone pieces came from the wound in the shape of a long tunnel, and specialists from the Orthopedics and Brain Surgery departments stated that it did not require intervention. Afterward, the wound was washed and cleaned and a lumbar exit hole was closed with a suture; a long Penrose drain was placed into the entry hole. The patient was placed in the supine position, and his abdominal cavity was examined once more and then cavity was closed. The patient remained in the intensive care unit for two days following the operation and was discharged with full recovery on the 11th day of his follow-up. In his control lumbar spinal magnetic resonance image, there were subcutaneous degenerative changes at L4-L5 levels, and there were degenerative changes in the nerve roots at S2-S5 levels. His electromyography findings were normal. The patient did not have any problems while walking, defecating, and urinating and still continues to have no such problems after the 14th postoperative month.

DISCUSSION

Impalement and anorectal injuries are rarely observed during childhood. Nevertheless, they can have high mortality and morbidity rates [3-5]. While falling from construction sites is usually seen in adults, in children, anorectal injuries occur due to sliding down from trees, falling on sharp objects in the sitting position while playing, or sexual assault [4, 6, 7]. These injuries can very rarely be iatrogenic [8]. These traumas are not limited to the anorectal region but can cause serious problems in every region that the foreign body passes through. Sometimes, a very careful examination should be performed on the patients from whom foreign bodies are removed, and extraperitoneal bladder rupture should not be missed even if the anorectal examination appears to be normal [9].

In our case, the entry site of the construction iron bar was 1 cm to the side of the anus; the bar scraped the rectum, went through the sacrum, affected the spinous

process of the vertebrae, and exited through the loin. Although more severe problems are expected with the injury of intra-abdominal organs, early surgery has been reported to be very critical in such cases [10]. There is emphasis on the importance of intervention within 6 h, particularly for improving sepsis and wound recovery [8]. Our patient waited for approximately 1 h for the removal of 12-m long foreign body by the fire department and was taken to the nearest hospital; he was later transferred to our hospital. The delay caused by these events was somewhat compensated as our team was well organized and ready after being informed by the 112 emergency services operator. Although an unexpected problem caused by the cutter type extended the shortening and removal duration, surgery was finally performed at 4 h. Although sphincter and urinary system problems are more frequently observed in cases accompanied by severe and vital organ injuries, perianal injuries also require long-term follow-up due to these problems [2]. After regular follow-ups for 14 months, our patient does not have any problems in walking, urinating, and defecating; follow-ups still continue and he still has no such problems.

In conclusion, surgical teams working in co-ordination have to share wisdom in order to have successful outcomes in similar cases. We believe that sharing our experiences and revealing their shortcomings and developing novel, solution-oriented guidelines will take us forward in similar cases in the future.

Acknowledgment: We would like to specially thank Istanbul Sevakoy Fire Department for their help and careful work.

Conflict of Interest: No conflict of interest was declared by the authors.

Financial Disclosure: The authors declared that this study has received no financial support.

Authorship contributions: Concept – S.O., A.G., B.K., S.C., C.B., M.K.T., S.S.; Design – S.O., A.G., B.K., S.C., C.B., M.K.T., S.S.; Supervision – S.O., A.G., B.K., S.C., C.B., M.K.T., S.S.; Materials – S.O., A.G., B.K., S.C., C.B., M.K.T., S.S.; Data collection &/or processing – S.O., A.G., B.K., S.C., C.B., M.K.T., S.S.; Analysis and/or interpretation – S.O., A.G., B.K., S.C., C.B., M.K.T., S.S.; Writing – S.O., A.G., B.K., S.C., C.B., M.K.T., S.S.; Critical review – S.O., A.G., B.K., S.C., C.B., M.K.T., S.S.

REFERENCES

1. Beiler HA, Zachariou Z, Daum R. Impalement and anorectal injuries in childhood: a retrospective study of 12 cases. *J Pediatr Surg* 1998;33:1287–91.

2. Russell KW, Soukup ES, Metzger RR, Zobell S, Scaife ER, Barnhart DC, et al. Fecal continence following complex anorectal trauma in children. *J Pediatr Surg* 2014;49:349–52.
3. Dar Rawat J, Goel P, S Kunnur V, Kushwaha B, Kushwaha R. Penetrating injury of pelvis, abdomen and thorax in a child with a trident (trishula). *APSP J Case Rep* 2013;4:3.
4. Vincent MV, Abel C, Duncan ND. Penetrating anorectal injuries in Jamaican children. *Pediatr Surg Int* 2012;28:1101–7.
5. Grisoni ER, Hahn E, Marsh E, Volsko T, Dudgeon D. Pediatric perineal impalement injuries. *J Pediatr Surg* 2000;35:702–4.
6. Kolahdouzan M, Rezaee MT, Shahabi S. Impalement Thoracoabdominal Trauma Secondary to Falling on Metallic (Iron) Bars: An Extremely Rare and Unique Case. *Arch Trauma Res* 2016;5:e18330.
7. Malla G, Basnet B, Vohra R, Herrforth C, Adhikari S, Bhandari A. Thoraco- abdominal impalement injury: a case report. *BMC Emerg Med* 2014;14:7.
8. Shatnawi NJ, Bani-Hani KE. Management of civilian extraperitoneal rectal injuries. *Asian J Surg* 2006;29:11–6.
9. Kim S, Linden B, Cendron M, Puder M. Pediatric anorectal impalement with bladder rupture: case report and review of the literature. *J Pediatr Surg* 2006;41:E1–3.
10. Zuccon W, Paternollo R, Del Re L, Cordovana A, De Murtas G, Gaverini G, et al. Emergency treatment of violent trauma: clinical cases and surgical treatment of penetrating thoracoabdominal, perineal and anorectal trauma. *Ann Ital Chir* 2013;84:11–8.