



Contents lists available at ScienceDirect

International Journal of Surgery Case Reports

journal homepage: www.casereports.com

Omental patch reinforced with polypropylene mesh and split-thickness skin grafting: A new procedure to close the “open abdomen”



Emilio Muñoz Muñoz^a, Fernando Pardo-Aranda^{a,*}, Esteban García-Olivares^a, Sandra Patricia Pontes De Sousa^b, Pilar Forcada^b, Enrique Veloso^a

^a Gastrointestinal Surgery Department, Hospital Universitario Mutua Terrassa, Barcelona, Spain

^b Pathologist Department, Hospital Universitario Mutua Terrassa, Barcelona, Spain

ARTICLE INFO

Article history:

Received 19 March 2016
Received in revised form 2 June 2016
Accepted 2 June 2016
Available online 23 June 2016

Keywords:

Laparostomy
Open abdomen
Great omentum
Polypropylene mesh
Split-thickness skin graft

ABSTRACT

INTRODUCTION: The “open abdomen” expression widely used to define a full-thickness defect of the abdominal wall intentionally made in some situations like abdominal compartment syndrome, has been replaced by a newest one called “laparostomy”. The definitive closure of an open abdomen with a giant full abdominal thickness defect remains a problem.

CASE REPORT: We present a 67-year old male with a descompressive laparostomy treated with a greater omentum flap sutured hermetically with interrupted stitches at the edges of the muscle wall, reinforced with large mesh of polypropylene (PP) placed on-lay and sutured to the fascia by two concentric running sutures of polypropylene. A vacuum-assisted closure device was placed on the second postoperative day and it was kept during three weeks. By then the PP mesh was completely integrated so skin grafts were applied to the surface of the granulation tissue. An incisional hernia was easily repaired at three years of follow-up. Eight months after the last surgery the patient is satisfied with the result achieved.

DISCUSSION: The great omentum has immunological and angiogenic properties that allow a rapid integration of the polypropylene mesh, even in septic environments, facilitating the engraftment of split-thickness skin graft.

The reactive fibrosis caused by the PP mesh replaces the fat tissue but the inner surface is preserved, thereby avoiding subsequent adhesion and facilitates surgical access to the abdominal cavity if necessary in the future.

CONCLUSION: The structure achieved is a strong structure, capable of visceral isolation that can be useful to close some OA.

© 2016 The Author(s). Published by Elsevier Ltd on behalf of IJS Publishing Group Ltd. This is an open access article under the CC BY-NC-ND license (<http://creativecommons.org/licenses/by-nc-nd/4.0/>).

1. Introduction

The “open abdomen” (OA) expression widely used to define a full-thickness defect of the abdominal wall intentionally made in some situations like abdominal compartment syndrome, some peritonitis and as a damage control surgery [1–3], has been replaced by a newest one called “laparostomy”. This is an accepted maneuver performed more often every day. Nevertheless, the OA can cause acute complications and create a new major problem like the closure of a full thickness large abdominal wall defect.

The interest of the case presented remains on one hand in the histological data reported of the new structure created for the replacement of the full thickness of the abdominal wall – constructed with great omentum reinforced with polypropylene mesh

and split skin grafts –, and on the other hand the clinical behavior during three years and a half of follow-up.

2. Case report

The patient is a 67-year old male with a medical history of morbid obesity (BMI 40), former smoker of cigarettes 3rd day, chronic obstructive pulmonary disease and sleep apnea. On the second day of the postoperative time of a radical cystoprostatectomy, he presented a complete evisceration after intense coughing. A primary closure was performed and 24 h later he suffered an abdominal compartment syndrome (40 mmHg, intragastric measure) refractory to medical treatment, so a descompressive laparostomy was mandatory. Once hemodynamically stable, four days later a full abdominal wall defect of 32 × 22 cm was confirmed. This defect was closed using a greater omentum flap sutured hermetically with interrupted stitches at the edges of the muscle wall, reinforced with large mesh of polypropylene (PP) placed on-lay and sutured

* Corresponding author.

E-mail address: fparranda@gmail.com (F. Pardo-Aranda).

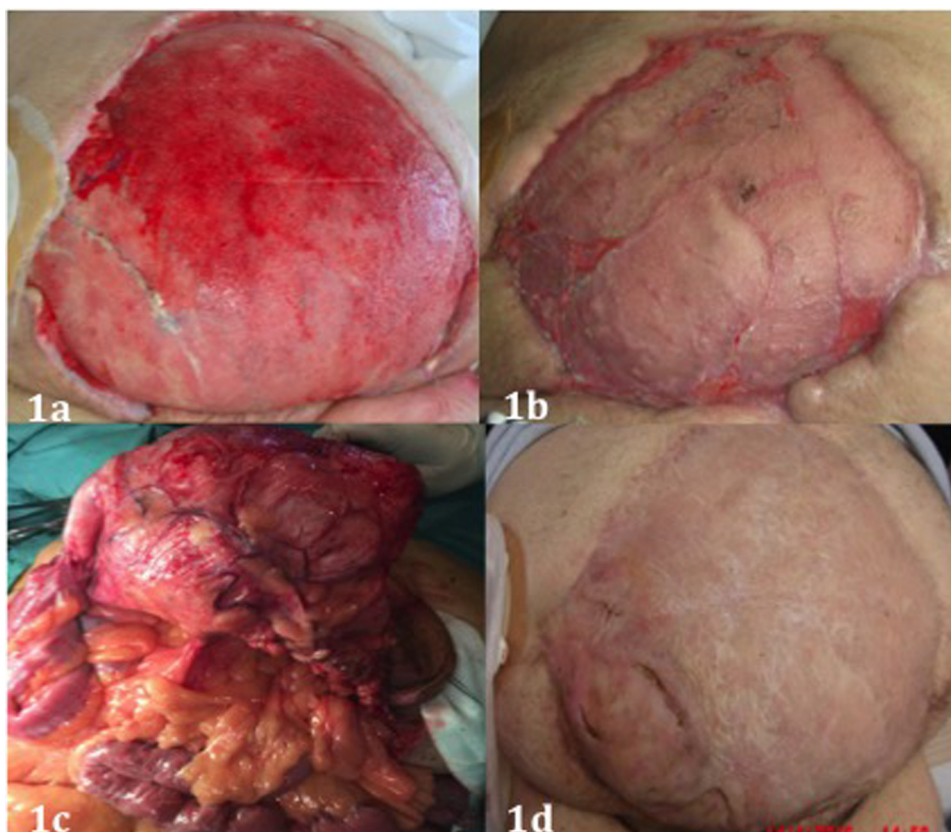


Fig. 1. (a) PP mesh integrated into granulation tissue. (b) Split skin grafts fully integrated. (c) The structure formed by the omentum reinforced with PP mesh and split skin grafts was easily handled and it did not adhere any intestine loop. (d) Result after the repair of incisional hernia.

to the fascia by two concentric running sutures of polypropylene. A vacuum-assisted closure device was placed on the second postoperative day and it was kept during three weeks. By then the PP mesh was completely integrated (Fig. 1a), so skin grafts were applied to the surface of the granulation tissue (Fig. 1b).

A small incisional hernia was diagnosed in the lower part of the small wound at one and a half year of follow-up. The patient increased 20 kg, and the incisional hernia acquired a large dimension three years after the reconstruction of the abdominal wall, so we decided to repair the defect. The surgical approach was performed through the incisional hernia. The access to the abdominal cavity did not present particular difficulties. The structure formed by the omentum reinforced with PP mesh and split skin grafts was strong and hard but flexible so it could be easily handled and it did not adhere any intestinal loop (Fig. 1c). After resecting redundant sac the abdominal wall was closed with interrupted non-absorbable stitches. A full thickness biopsy was performed in order to know something more about the “new abdominal wall”. The histopathological examination revealed “Fragment of 1.2 cm thick. At the level of superficial and deep dermis is noted marked fibrosis. In the deepest zone can recognize foreign material with giant cell inflammatory reaction”. The patient had a postoperative wound infection (culture + for *Pseudomonas Aeruginosa*), which healed without difficulty. Eight months after surgery the patient is satisfied with the result achieved (Fig. 1d).

3. Discussion

The definitive closure of an open abdomen with a giant full abdominal thickness defect remains a problem that can be even more complex if there is interference from a stoma. In this situa-

tion, not only primary fascial closure becomes impossible but also a component separation of the abdominal wall layers that could provide a fascial apposition.

On the other hand, a functional closure would not be recommended if the skin cannot be closed over a biological mesh. Likewise, a planned ventral hernia using split-thickness skin graft is not a definitive procedure, the risk of enteroatmospheric fistula increases significantly and it takes a long time for the final solution [2,4].

Good results have been reported using a tailored two-component mesh (polyglycolic acid and polypropylene meshes) as a safe alternative to the planned giant ventral hernias but it does not provide details about potential difficulties in case of further laparotomies or how to resolve a large skin defect [5].

The decrease of the number of fistulas has been observed for more than 20 year when the omentum is placed between the abdominal cavity and the PP mesh [6] and it has also been reported the usefulness of the combination of greater omentum and PP mesh when there is contamination or infection [7].

The great omentum is anatomically a fat structure composed of mesothelial sheets which enclose predominantly adipocytes embedded in a loose connective tissue and aggregates of mononuclear phagocytic cells. Its immunological and angiogenic properties [8–10] allow a rapid integration of the polypropylene mesh, even in septic environments, facilitating the engraftment of split-thickness skin graft.

The reactive fibrosis caused by the PP mesh replaces the fat tissue but the inner surface is preserved, thereby avoiding subsequent adhesion and facilitates surgical access to the abdominal cavity if necessary in the future. The structure achieved is a strong structure, capable of visceral isolation that can be useful to close some OA.

Consent

Written informed consent was obtained from the patient for publication of this case report and any accompanying images. A copy of the written consent is available for review by the Editor of this journal.

Conflicts of interest

The authors declare that there is no conflict of interest.

Funding

This research received no specific grant from any funding agency in the public, commercial, or not-for-profit sector.

Authors' contributions

F.P. drafted the manuscript. E.M. and E.G. participated in the design of the case. P.F. and S.P. participated in its design and coordination and E.V. helped to draft the manuscript. All authors read and approved the final manuscript.

Ethical approval

A written and signed informed consent from the patient has been obtained and approved for our ethical committee.

Guarantor

All authors accept full responsibility for the work.

References

- [1] J.J. Atema, S.L. Gans, M.A. Boermeester, Systematic review and meta-analysis of the open abdomen and temporary abdominal closure techniques in non-trauma patients, *World J. Surg.* 39 (2015) 912.
- [2] M. Kääriäinen, H. Kuokkanen, Primary closure of the abdominal wall after open abdomen situation, *Scand. J. Surg.* 102 (2013) 20–24.
- [3] A. Campbell, M. Chang, T. Fabian, M. Franz, M. Kaplan, F. Moore, R.L. Reed, B. Scott, R. Silverman, Management of the open abdomen: from initial operation to definitive closure, *Am. Surg.* 75 (Suppl. 11) (2009) S1–S22.
- [4] T.W. Jernigan, T.C. Fabian, M.A. Croce, N. Moore, F.E. Pritchard, G. Minard, T.K. Bee, Staged management of giant of giant abdominal wall defects: acute and long term results, *Ann. Surg.* 238 (2003) 349–357.
- [5] U.A. Dietz, C. Wichelmann, C. Wunder, L. Kauczok Jm Spor, A. Straub, R. Wildenauer, C. Jurowich, C.T. Germer, Early repair of the open abdomen with a tailored two-component mesh and conditioning vacuum packing: a safe alternative to planned giant ventral hernia, *Hernia* 16 (2012) 451–460.
- [6] C.P. Brandt, C.R. McHenry, D.G. Jacobs, J.J. Piotrowski, P.P. Priebe, Polypropylene mesh closure after emergency laparotomy: morbidity and outcome, *Surgery* 118 (1995) 736–741.
- [7] R.P. Bleichrodt, A.W. Malyar, T.S. de Vries Reilingh, O. Buyne, J.J. Bonenkamp, H. Van Goor, The omentum-polypropylene sandwich technique: an attractive method to repair large abdominal-wall defects in the presence of contamination or infection, *Hernia* 11 (2007) 71–74.
- [8] C. Platell, D. Cooper, J.M. Papadimitriou, J.C. Hall, The omentum, *World J. Gastroenterol.* 6 (2) (2000) 169–176.
- [9] Q.X. Zhang, C.J. Magovern, C.A. Mack, K.T. Budenbender, W. Ko, T.K. Rosengart, Vascular endothelial growth factor is the major angiogenic factor in omentum: mechanism of the omentum-mediated angiogenesis, *J. Surg. Res.* 647 (1997) 147–154.
- [10] A. Bikfalvi, J. Alterio, A.L. Inyang, E. Dupuy, M. Laurent, M.P. Hartmann, L. Vigny, D. Raulais, Y. Courtois, G. Tobelem, Basic fibroblast growth factor expression in human omental microvascular endothelial cells and the effect of phorbol ester, *J. Cell. Physiol.* 144 (1990) 151–158.

Open Access

This article is published Open Access at sciendo.com. It is distributed under the [IJSCR Supplemental terms and conditions](#), which permits unrestricted non commercial use, distribution, and reproduction in any medium, provided the original authors and source are credited.