

## Full Mouth Rehabilitation by Implant Supported Fixed Prosthesis

### Abstract

The purpose of this study is to report a case of full-mouth rehabilitation on six endosseous implants loaded following the standard procedure. It was decided to insert six implants in the maxillary and six implants in the mandibular arch in a patient with no systemic disease. The surgery was performed with the patient under local anesthesia with lignocaine and 1:100,000 adrenaline. Implant stability was sufficient (35 N/cm measured with a torque spring) for all 12 implants. An impression is taken in the open tray with a silicone impression material. Vertical dimension for rest and occlusion was checked with wax occlusal rims placed in the mouth. Interocclusal records were made with the metal framework in place. The final restoration was realized with ceramic layering completed. Good impressions and meticulous attention to detail are crucial for a successful implant-supported fixed prosthesis.

**Keywords:** Dental implants, full-mouth rehabilitation, implant-supported fixed prosthesis, vertical dimension at occlusion

### Introduction

A dental implant is defined as a prosthetic device made of alloplastic material(s) implanted into the oral tissues beneath the mucosal and/or periosteal layer and on or within the bone to provide retention and support for a fixed or removable dental prosthesis, a substance that is placed into and/or on the jaw bone to support a fixed or removable dental prosthesis.<sup>[1]</sup> Dental implants have revolutionized restorative dentistry. They offer permanent replacement to loose and missing teeth and can be an alternative to wearing dentures and rebuilding confidence with a functional and secure smile.

Recent standards in implantology are intended to provide prosthetic restorations with the finest esthetic and functional results. Several parameters have been suggested to achieve benchmark results: adequate bone height, width and sagittal projection, adequate soft-tissue quantity and quality, preservation of buccal sulcus, and adequate papillae and gingival contour.<sup>[2]</sup> Solutions to inadequate ridge height include the use of short implants,<sup>[3]</sup> vertical ridge augmentation procedures,<sup>[4,5]</sup> or cantilever prostheses.<sup>[6]</sup> Although having a comparable

short-term survival rate, some authors state that the long-term performance of short implants is less understood, especially in the posterior maxilla with lower bone density.<sup>[7]</sup> Vertical augmentation procedures increase patient injury, and the outcome is less predictable, especially in the posterior mandible. Cantilever prostheses might incur higher rates of prosthetic complications such as abutment loosening, denture fracture, and implant failure.

Due to the less predictable long-term prognosis associated with the above-mentioned procedures, the “All-on-Four” technique was proposed for the rehabilitation in edentulous jaws. Although the use of only four implants for a complete fixed rehabilitation of the maxilla has been supported by clinical studies at short period,<sup>[8-10]</sup> it has been suggested that using a larger number of implants (around 6) for prosthetic treatment of the edentulous maxilla may be beneficial as the stresses on the majority of the implants were lower in the all-on-six planning in comparison to the all-on-four planning.

The “all-on-six” treatment concept was developed to maximize the use of available remnant bone in jaws, allow immediate function, and avoid regenerative procedures that increase the treatment costs and patient morbidity, as well as the complications inherent to these procedures.<sup>[11]</sup>

**Jitendra Bhandari,  
Prasad Adhapure<sup>1</sup>,  
Nimisha N Barve<sup>1</sup>,  
Nazish Baig<sup>1</sup>, Vivek  
Jadhav<sup>1</sup>, Snehal  
Vispute<sup>2</sup>**

*Department of Prosthodontics,  
D Y Patil Dental School  
Lohagaon, Pune, <sup>1</sup>Department  
of Prosthodontics, CSMSS  
Dental College, Aurangabad,  
<sup>2</sup>Department of Orthodontics,  
CSMSS Dental College,  
Aurangabad, Maharashtra,  
India*

**Submitted :** 30-Sep-2018  
**Revised :** 08-Nov-2018  
**Accepted :** 01-Oct-2019  
**Published :** 07-Aug-2020

#### Address for correspondence:

*Dr. Nimisha N Barve,  
404, Aamrapali Apts, Lane No.  
1, Shahu Colony, Karve Nagar,  
Pune - 411 052, Maharashtra,  
India.  
E-mail: nimishabarve.1110@  
gmail.com*

#### Access this article online

**Website:**  
[www.contempclindent.org](http://www.contempclindent.org)

**DOI:** 10.4103/ccd.ccd\_738\_18

#### Quick Response Code:



**How to cite this article:** Bhandari J, Adhapure P, Barve NN, Baig N, Jadhav V, Vispute S. Full mouth rehabilitation by implant supported fixed prosthesis. *Contemp Clin Dent* 2020;11:199-202.

This is an open access journal, and articles are distributed under the terms of the Creative Commons Attribution-NonCommercial-ShareAlike 4.0 License, which allows others to remix, tweak, and build upon the work non-commercially, as long as appropriate credit is given and the new creations are licensed under the identical terms.

**For reprints contact:** [reprints@medknow.com](mailto:reprints@medknow.com)

The original Brånemark surgical prosthetic protocol advocated the placement of four implant fixtures for the restoration of a resorbed maxillae and six implant fixtures on mandibles that demonstrated minimal-to-moderate resorption.<sup>[12]</sup>

The implant-supported fixed restoration (FP-3) restoration appears to replace the natural teeth crowns and a portion of the soft tissue. Basically, two approaches for an FP-3 prosthesis exist: a hybrid restoration of denture teeth, acrylic and metal substructure, or a porcelain-metal restoration.<sup>[13]</sup>

The primary factor that determines the restoration type is the amount of interarch space, transition line, and smile line. The challenge today is not only to prove functionality but also to develop simple and cost-effective protocols.

The purpose of this paper is to report a case of full-mouth prosthetic rehabilitation on six endosseous implants loaded following the standard procedure.

## Case Report

A 56-year-old male patient has been to a dental clinic with a completely edentulous maxillary and mandibular jaw. He showed no systemic pathology and was not a smoker. The patient was unhappy with the esthetics and did not want a removable prosthesis. After careful evaluation, it was decided to insert six implants in the maxillary and six implants in the mandibular arch.

## Investigations

Cone-beam computed tomography (CBCT) was the preferred investigation. CBCT scan of both the arches revealed the following:

- Regions of 11, 12, 13, 14, 15, 16, 17, 21, 22, 23, 24, 25, 26, 27, 31, 32, 33, 34, 35, 36, 37, 41, 42, 43, 44, 45, 46, and 47 are the sites for implant placement
- Insufficient width of the alveolar bone in the regions of 11, 21, and 45
- Insufficient height of the alveolar bone in the regions of 46, 47, 15, 16, 17, 26, 27, 35, and 36
- Irregular thickening of the lining mucosa along the walls of the maxillary sinus in the regions of 15, 16, and 17.

## Surgical phase

The surgery was performed under local anesthesia with lignocaine and 1:100,000 adrenaline. A total of 12 implants were placed for maxillary and mandibular rehabilitation. Implant stability was sufficient (35 N/cm measured with a torque spring) for all 12 implants. Second-stage surgery was performed, and prosthetic rehabilitation was conducted.

Figure 1 shows a total 12 implants in the maxilla and mandible.

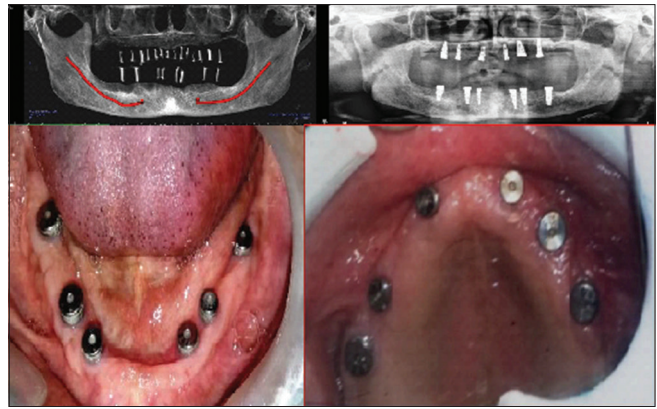


Figure 1: Total 12 implants in the maxilla (lower right) and mandible (lower left), OPG after implant placement (upper right), CBCT Scan (upper left)

## Prosthetic phase

### Impression making for multiple implants

For rehabilitation, a conventional alginate impression was made, and study models were cast. A rigid custom tray was manufactured with a window cut through over the implants.

Then, the healing abutments were removed; appropriate impression copings were selected and fitted. These copings were splinted together intraorally to provide greater rigidity and possibly greater accuracy.<sup>[14]</sup>

The open tray was tried in the mouth taking care that the impression copings emerged in level with the windows made in the tray. This permitted easy removal of the impression copings while ensuring that the copings are supported by sufficient impression material. The tips of the impression copings should be felt through the wax covering the window. The impression of implants was made with addition silicone (VPS) with different viscosities after merging all the impression transfer copings with DuraLay pattern resin.

Open trays were fabricated, copings were splinted together, and impression was recorded in the silicon impression material [Figure 2].

Once the impression was set, the impression copings were unscrewed through the window on the tray, and the impression was removed from the mouth along with all the impression copings in place.

### Jaw relation record and try-in

The vertical dimension for rest and occlusion was checked with wax occlusal rims placed in the mouth. A divider was used to measure the vertical dimension at occlusion (VDO) and vertical dimension at rest. Facebow record was established, and centric relation recorded. Teeth were arranged in the rim, and try-in was done.

Maintaining the same VDO, metal framework was fabricated, and metal try-in was done. Interocclusal records were made with the metal framework in place.

Facebow record was made, VDO was checked, teeth arrangement was made, and metal framework was made and checked with the same VDO [Figure 3].

The final restoration was realized with complete ceramic layering.

Figure 4 shows the final restoration with ceramic layering.

The trial was done, and occlusal adjustments were made. With the occlusal modifications, bite forces are primarily compressive in nature to the prosthesis, the implants, and the bone. The prosthesis was then screwed and the screws were covered by composite.

## Discussion

The original work of Branemark *et al.*<sup>[12]</sup> was carried out in 1977, whereby they utilized 4–6 vertical implants placed within the anterior segment of the edentulous maxilla and mandible cantilevered to accommodate a full-arch fixed prosthesis. Their 10-year study (78.3%–80.3% for the maxilla and 88.4%–93.2% for the mandible) showed a good success rate.

Four implants are used to rehabilitate fully edentulous jaws with fixed dentures.<sup>[11]</sup> Two implants are placed

axially in the anterior region of the alveolar ridge, and two are distally angled (30° to 45°) in the posterior region. Clinical studies<sup>[3,7,10]</sup> have shown that the all-on-four approach is predictable and has an implant cumulative survival rate of up to 99%. However, prosthetic survival is slightly smaller (up to 95% after 10 years).<sup>[12]</sup> Problems such as prosthetic fracture, porcelain crown fracture, abutment loosening, and prosthetic screw loosening and factors that lead to prosthesis overloading, such as bruxism or presence of long cantilever, may be related to the decrease of prosthetic survival rate in all-on-four concept.<sup>[15-17]</sup>

Depending on the positioning of the posterior implant and the degree of jaw atrophy, the presence of cantilever may be inevitable which increases the risk of mechanical complications in the prostheses (up to 50%).<sup>[15-17]</sup> Thus, the presence of bone volume in the posterior jaw that allows the insertion of more implants (six implants in each arch) is beneficial to improve prosthetic support and to decrease cantilever length.<sup>[15-17]</sup> The impression posts were splinted using floss and pattern resin for better precision and accuracy. The vertical dimension of occlusion was established and maintained throughout the prosthetic protocol.

While prosthetic planning of the case, special attention was paid to the transition zone and the smile line. In this case, a ceramometal final prosthesis was selected as the cosmetic defect was not much.<sup>[18]</sup> Careful occlusal adjustment was done to provide bilateral occlusion in the canine and first premolar areas.

## Summary

An appropriate diagnosis and accurate implant planning are keys to success in implant rehabilitation. Good impressions and meticulous attention to detail were crucial for successful implant-supported fixed prosthesis. As the stresses at the majority of the implants were lower in the all-on-six planning in

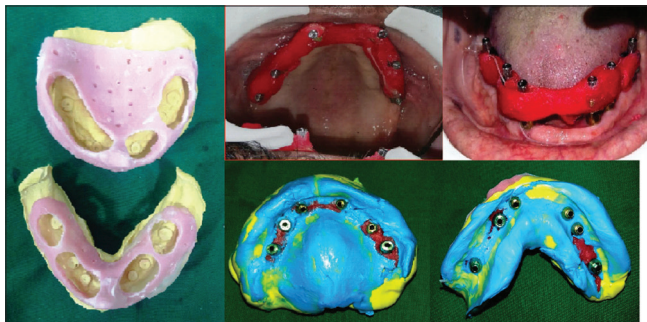


Figure 2: Open trays fabricated (left side), copings were splinted together (upper right and centre), and impression recorded in the silicon impression material (lower right and centre)

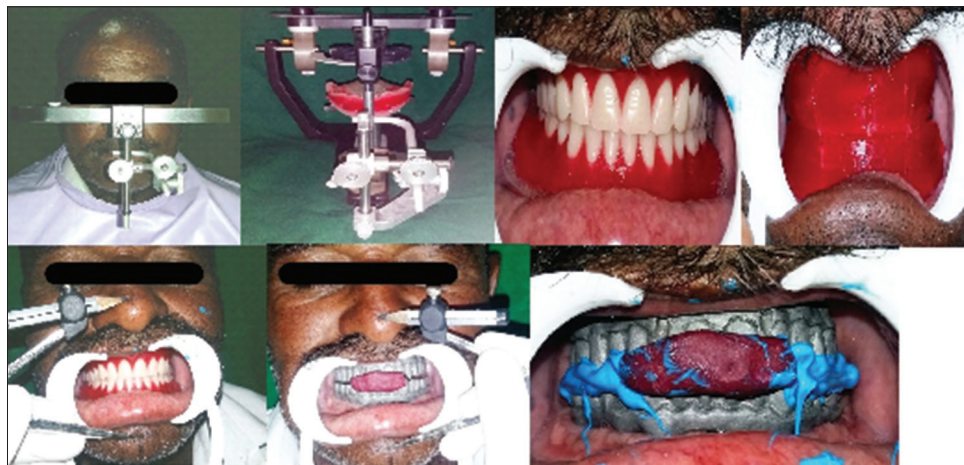
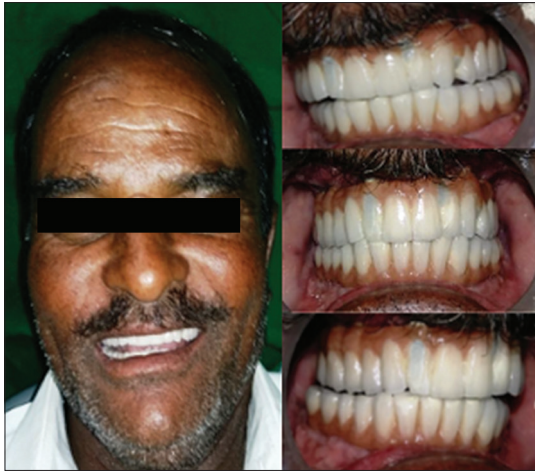
Figure 3: Facebow record was made (upper left), vertical dimension at occlusion was checked (lower left), teeth arrangement was made (upper right), and metal framework was made and checked with the same vertical dimension at occlusion (lower right)





**Figure 4:** Final restoration with ceramic layering (left),left lateral (upper right),centric occlusion (centre right),right lateral (lower right)

comparison to the all-on-four planning, it should be considered as advantageous as it decreases the cantilever.

#### Declaration of patient consent

The authors certify that they have obtained all appropriate patient consent forms. In the form the patient(s) has/have given his/her/their consent for his/her/their images and other clinical information to be reported in the journal. The patients understand that their names and initials will not be published and due efforts will be made to conceal their identity, but anonymity cannot be guaranteed.

#### Financial support and sponsorship

Nil.

#### Conflicts of interest

There are no conflicts of interest.

#### References

1. Ferro KJ. The Glossary of Prosthodontic Terms: Ninth Edition. *J Prosthet Dent.* 2017;117(5S):e1-e105.
2. Guerrero C, Lopez P, Figueroa F. Three-dimensional alveolar distraction osteogenesis. In: Bell W, Guerrero C, editors. *Distraction Osteogenesis of the Facial Skeleton.* 1<sup>st</sup> ed. Hamilton (Canada): BC Decker; 2007. p. 457-93.
3. Esposito M, Grusovin MG, Coulthard P, Worthington HV. The efficacy of various bone augmentation procedures for dental implants: A Cochrane systematic review of randomized controlled clinical trials. *Int J Oral Maxillofac Implants* 2006;21:696-710.
4. Sorní M, Guarínós J, García O, Peñarrocha M. Implant rehabilitation of the atrophic upper jaw: A review of the

- literature since 1999. *Med Oral Patol Oral Cir Bucal* 2005;10 Suppl 1:E45-56.
5. Maestre-Ferrín L, Boronat-López A, Peñarrocha-Diago M, Peñarrocha-Diago M. Augmentation procedures for deficient edentulous ridges, using onlay autologous grafts: An update. *Med Oral Patol Oral Cir Bucal* 2009;14:e402-7.
6. Chaushu G, Mardinger O, Peleg M, Ghelfan O, Nissan J. Analysis of complications following augmentation with cancellous block allografts. *J Periodontol* 2010;81:1759-64.
7. Hashemi HM. Neurosensory function following mandibular nerve lateralization for placement of implants. *Int J Oral Maxillofac Surg* 2010;39:452-6.
8. Lazari PC, Sotto-Maior BS, Rocha EP, de Villa Camargos G, Del Bel Cury AA. Influence of the veneer-framework interface on the mechanical behavior of ceramic veneers: A nonlinear finite element analysis. *J Prosthet Dent* 2014;112:857-63.
9. Hasan I, Bourauel C, Mundt T, Heinemann F. Biomechanics and load resistance of short dental implants: A review of the literature. *ISRN Dent* 2013;2013:424592.
10. Corbella S, Taschieri S, Del Fabbro M. Long-term outcomes for the treatment of atrophic posterior maxilla: A systematic review of literature. *Clin Implant Dent Relat Res* 2015;17:120-32.
11. Maló P, Rangert B, Dväsäter L. Immediate function of brånemark implants in the esthetic zone: A retrospective clinical study with 6 months to 4 years of follow-up. *Clin Implant Dent Relat Res* 2000;2:138-46.
12. Brånemark PI, Engstrand P, Ohnrell LO, Gröndahl K, Nilsson P, Hagberg K, et al. Brånemark novum: A new treatment concept for rehabilitation of the edentulous mandible. Preliminary results from a prospective clinical follow-up study. *Clin Implant Dent Relat Res* 1999;1:2-16.
13. Bodine RL. Prosthodontic essentials and an evaluation of the mandibular subperiosteal implant denture. *J Am Dent Assoc* 1955;51:654-64.
14. Lee H, So JS, Hochstedler JL, Ercoli C. The accuracy of implant impressions: A systematic review. *J Prosthet Dent* 2008;100:285-91.
15. Maló P, Nobre Md, Lopes A. The rehabilitation of completely edentulous maxillae with different degrees of resorption with four or more immediately loaded implants: A 5-year retrospective study and a new classification. *Eur J Oral Implantol* 2011;4:227-43.
16. Maló P, Rangert B, Nobre M. All-on-4 immediate-function concept with brånemark system implants for completely edentulous maxillae: A 1-year retrospective clinical study. *Clin Implant Dent Relat Res* 2005;7 Suppl 1:S88-94.
17. Malo P, de Araujo Nobre M, Lopes A. The use of computer-guided flapless implant surgery and four implants placed in immediate function to support a fixed denture: Preliminary results after a mean follow-up period of thirteen months. *J Prosthet Dent* 2007;97:S26-34.
18. Bedrossian E. *Implant Treatment Planning for the Edentulous Patients. A Graftless Approach to Immediate Loading.* St Louis, MO: Mosby, an Imprint of Elsevier; 2011.