

[ CASE REPORT ]

## Successful Application of Edoxaban in the Treatment of Venous Thromboembolism Recurrence in a Patient with Non-small Cell Lung Cancer after Tumor Shrinkage

Tetsuaki Shoji, Hidenori Mizugaki, Yasuyuki Ikezawa, Megumi Furuta, Yuta Takashima, Hajime Kikuchi, Houman Goudarzi, Hajime Asahina, Junko Kikuchi, Eiki Kikuchi, Jun Sakakibara-Konishi, Naofumi Shinagawa, Ichizo Tsujino and Masaharu Nishimura

### Abstract:

This report describes the case of a 66-year-old man with non-small cell lung cancer and venous thromboembolism (VTE). Unfractionated heparin (UFH) was initially used to control VTE before chemotherapy. However, switching UFH to warfarin or edoxaban, a novel oral anticoagulant (NOAC), failed. Chemotherapy was then administered to control the tumor which was thought to have been the main cause of VTE, which had been treated by UFH. After tumor shrinkage was achieved by chemotherapy, we were able to successfully switch from UFH to edoxaban. Controlling the tumor size and activity enabled the use of edoxaban as maintenance therapy for VTE.

**Key words:** lung cancer, venous thromboembolism, novel oral anticoagulants, direct oral anticoagulants, tumor shrinkage, tumor volume

(Intern Med 57: 1769-1772, 2018)

(DOI: 10.2169/internalmedicine.9741-17)

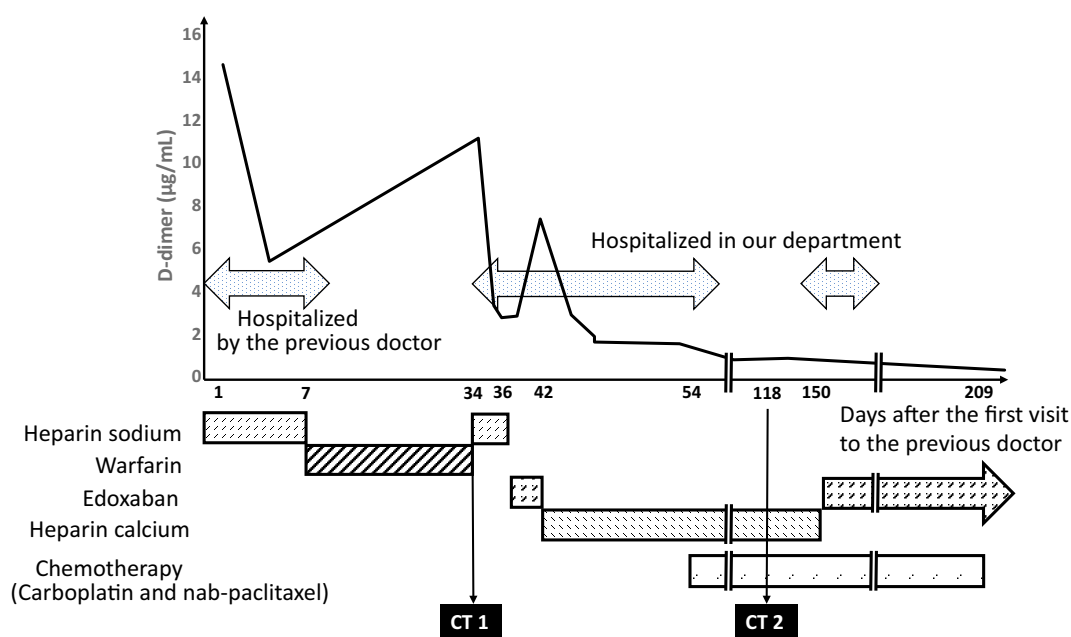
### Introduction

Venous thromboembolism (VTE) often occurs in patients with advanced lung cancer (1). Registry data have shown a 3-fold reduction in the 1-year survival of patients with cancer and VTE in comparison to those without VTE (2). The risk of VTE recurrence in patients with VTE and cancer is more than 3-fold higher than that in patients without cancer (3). Thus, both the initial treatment and prophylaxis against VTE recurrence are important for patients with cancer and VTE. Low-molecular weight heparin (LMWH) is recommended for the initial 5 to 10 days of treatment for VTE and also as long-term prophylactic therapy for at least 6 months (4). LMWH is preferred over unfractionated heparin (UFH) because the mortality rate and the incidence of thrombosis and bleeding in patients who receive LMWH is reduced in comparison to patients who receive UFH. However, UFH is widely used for patients with VTE and cancer

because the administration of LMWH for VTE in nonsurgical patients is not covered by health insurance in Japan. For long-term prophylactic therapy, vitamin K antagonists (VKAs) are acceptable if heparin is not available. Since LMWH and UFH must be administered via intermittent subcutaneous injection or continuous intravenous injection, and thus impair the quality of life (QOL) of the patient, VKAs are widely used for long-term prophylactic therapy in Japan.

The use of novel oral anticoagulants (NOACs), also known as direct oral anticoagulants, is not currently recommended for cancer patients with VTE due to the limited available data (4, 5). However, NOACs have been widely used as anticoagulants for patients without cancer (6), and recent studies have reported the efficacy and safety of NOACs in patients with VTE (7, 8).

We herein report the successful application of edoxaban, an NOAC, in the treatment of the recurrence of VTE in a patient with non-small cell lung cancer after tumor shrinkage was achieved using chemotherapy. This is the first re-



**Figure 1.** The schedule of treatment and the D-dimer level after the first visit to the previous doctor. During the treatment for venous thromboembolism with warfarin and the first edoxaban treatment, the D-dimer level increased and these treatments seemed to fail. However, during the second edoxaban treatment (after tumor shrinkage was achieved by chemotherapy), the D-dimer level remained within the normal range. Thus, the second application of edoxaban was successful. Computed tomography images of the tumor and pulmonary embolism (CT1 and 2 in Fig. 1) are shown in Fig. 2.

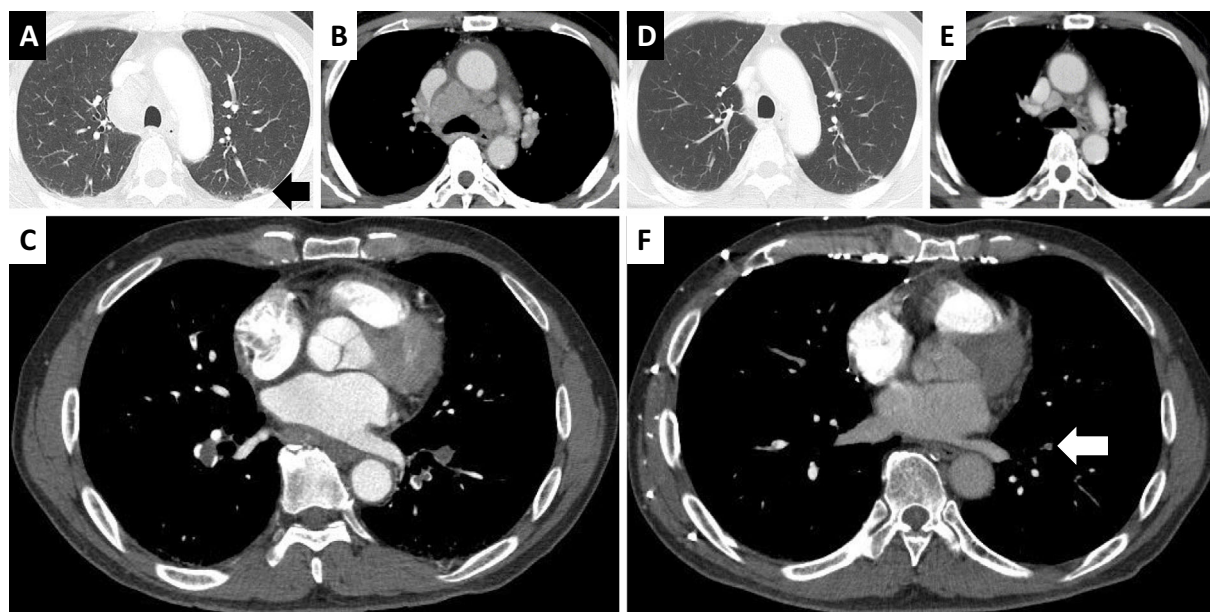
port to indicate that the tumor size and activity play an important role in the efficacy of anticoagulation therapy.

## Case Report

The patient was a 66-year-old man who had previously presented (at another hospital) with breathlessness and bilateral pedal edema. Computed tomography (CT) revealed a nodule in the left upper lobe that was suggestive of lung cancer and which was also associated with pulmonary embolism (PE) and deep venous thrombosis (DVT). His D-dimer level was high (14.6 µg/mL). The patient was not obese and was not a current smoker. There were no congenital factors associated with thrombosis in his family history. His anti-β2glycoprotein I antibody level was within the normal level. Thus, we concluded that it was likely that his VTE had been caused by lung cancer. VTE was considered to be a greater threat than lung cancer; thus, treatment for VTE was administered before the diagnosis of lung cancer. The schedule of treatment for VTE and lung cancer is shown in Fig. 1. The patient was hospitalized and was initially treated with a continuous intravenous injection of heparin sodium, which is a UFH. The symptoms improved and the D-dimer level decreased to 5.4 µg/mL. Seven days after the first visit, heparin sodium was switched to oral warfarin for long-term prophylactic therapy. The patient was discharged on a VKA (warfarin, 4 mg, daily). The International Normalized Ratio of Prothrombin Time (PT-INR) was maintained within the appropriate range (INR 2.0-3.4) for approximately 3 weeks. On the 34th day after his first visit

to the previous doctor, the patient was referred to our department. At that time, his breathlessness had become worse and the D-dimer level had increased to 11.2 µg/mL. CT revealed that the PE and DVT had progressed (Fig. 2). Thus, the patient was hospitalized again and was treated with a continuous intravenous injection of heparin sodium. Two days later, the D-dimer level decreased to 2.8 µg/mL and his breathlessness and pedal edema disappeared. Heparin sodium was switched to oral edoxaban (60 mg, daily) as long-term prophylactic therapy. However, the D-dimer level increased to 7.0 µg/mL after one week. Thus, treatment failure was suspected (9). We discontinued treatment with edoxaban and started the intermittent subcutaneous injection of heparin calcium, a UFH. During heparin treatment, the D-dimer level decreased and CT showed that the PE and DVT were reduced in size.

The patient was diagnosed with primary lung adenocarcinoma (cT1aN3M0 stage IIIB) based on the findings of a bronchoscopic biopsy of the enlarged mediastinal lymph nodes. From the 54th day, he was treated with chemotherapy consisting of carboplatin (area under the concentration-time curve 6, once every 3 weeks) and nab-paclitaxel (100 mg/m<sup>2</sup>, weekly) along with heparin calcium. After the second course of chemotherapy, contrast CT on the 118th day showed tumor shrinkage and the regression of VTE; the DVT had disappeared, and only a small thrombus remained in left arteria segmentalis basalis anterior (A8) (Fig. 2). The patient had no symptoms of VTE; however, he complained of skin irritation caused by the intermittent subcutaneous injection of heparin calcium. After the third course of chemo-



**Figure 2.** Contrast computed tomography (CT) images. (A) (B) (C) CT was performed on the 34th day after the first visit to the previous doctor, which is indicated by CT1 in Fig. 1. (A) A small primary nodule was detected in the apicoposterior segment of the left lung (black arrow). (B) The mediastinal lymph nodes were enlarged. (C) Pulmonary embolism (PE) in the bilateral pulmonary arteries progressed with anticoagulant treatment with warfarin for approximately 3 weeks. (D) (E) (F) CT was performed on the 118th day after the first visit to the previous doctor, which is indicated by CT2 in Fig. 1. (D) (E) Both the primary nodule and the mediastinal lymphadenopathy shrank after 2 courses of chemotherapy. (F) A regressed PE remained in the left arteria segmentalis basalis anterior (A8) (white arrow) after treatment with intermittent subcutaneous injections of heparin calcium for more than 2 months. After the patient complained of skin irritation from heparin injections, oral edoxaban was retried.

therapy and from the 150th day, treatment with edoxaban was reattempted. After the second switch from the heparin injection to edoxaban, the D-dimer level remained within the normal range, and a very small thrombus remained in the left pulmonary artery, as observed on contrast CT. The sixth course of chemotherapy was completed on the 209th day. The CT findings revealed a partial response and that a small thrombus remained. Neither the symptoms nor the D-dimer level became worse. The patient continued to receive edoxaban without any adverse events and the skin irritation from the injection of heparin ceased. Thus, the second application of edoxaban was successful.

Informed consent was obtained from the patient for the publication of this case report and any accompanying images, laboratory data, and pathological data.

## Discussion

The patient in the present case suffered from VTE associated with lung cancer. UFH was initially used to control the VTE. Attempts to switch anti-coagulants to warfarin (VKA) or edoxaban (NOAC) failed. Chemotherapy was then administered to control the tumor, which was considered to be the most likely cause of VTE. After the shrinkage of the tumor through chemotherapy, we were able to switch anti-

coagulation therapy from UFH to edoxaban. The relief of the skin irritation caused by the subcutaneous injection of UFH improved the patient's QOL. To the best of our knowledge, this is the first report to indicate that tumor size and activity plays an important role in the efficacy of anticoagulation therapy. The present case suggests that NOACs can be used as maintenance therapy for VTE when the tumor size and activity are controlled.

In the guidelines of both the American Society of Clinical Oncology and the European Society for Medical Oncology, NOACs are not currently recommended for patients with both cancer and VTE because of limited data (4, 5). NOACs were recently reported to show good efficacy in a population of patients with VTE that included some cancer patients. Edoxaban was not inferior - in terms of efficacy - to warfarin as long-term prophylactic therapy after initial treatment with heparin, and was associated with a significantly lower risk of bleeding in patients with VTE; 9.2% of these patients were suffering from cancer (7). Rivaroxaban, an NOAC, had similar efficacy to the combination of LMWH and warfarin or acenocoumarol in patients with VTE; 6.8% of these patients were suffering from active cancer (8). NOACs are a convenient treatment and allow for a good QOL for several reasons: they are orally administered and have a wide therapeutic window, any drug and food interac-

tions are minor, and there is no need for strict laboratory monitoring (10). Based on these previous reports, we chose NOAC as an alternative to UFH, rather than VKA. Edoxaban was selected because - at that time - it was the only NOAC that was covered by health insurance for the treatment of VTE in Japan.

Thrombosis is a common complication of cancer and anti-cancer chemotherapy. Substances derived from tumor cells, such as tissue factor (TF), plasminogen activator inhibitor, mucin, cytokines and other procoagulants, activate various mechanisms of thrombi formation (11, 12). Warfarin inhibits the vitamin K-dependent synthesis of clotting factors II, VII, IX, and X (13). NOACs directly inhibit the final steps of the coagulation cascade, which are clotting factor Xa (inhibited by edoxaban, rivaroxaban, and apixaban) or thrombin (inhibited by dabigatran) (7, 8, 14, 15). In addition to the abovementioned antithrombotic mechanism of NOACs, heparins have other antithrombotic mechanisms, such as inhibiting interaction with mucin and cell adhesion molecules, activating heparin cofactor II and protein C, releasing tissue factor pathway inhibitor from the vascular epithelium, and neutralizing a wide variety of cytokines and chemokines (12). Thus, heparins might have a stronger anticoagulation effect than warfarin and NOACs. Patients with more potent thrombi formation might require stronger anticoagulation treatment. In the present case, the tumor shrinkage achieved using chemotherapy might have weakened the thrombus formation activity and allowed the edoxaban to work well.

In addition to the tumor activity, a thrombotic state might influence the effects of anticoagulants. In the present case, when edoxaban was tried for the second time, the thrombus size regressed and the D-dimer level decreased. It is possible that the unstable parts of the thrombi were dissolved with UFH and that only the stable parts remained.

Further studies are needed to detect the clinical factors and biomarkers that indicate thrombus formation activity; this will allow the selection of the appropriate anticoagulation treatment depending on the potency of thrombus formation. The site of the tumor, body mass index, hemoglobin level, thrombocyte count, and leukocyte count are associated with a risk of VTE in cancer patients (16). Furthermore, the TF level may predict not only the initial but also recurrent VTE (11, 17). These factors might be indicators of thrombus formation as well as tumor size.

## Conclusion

We showed for the first time that tumor size and activity might affect the outcome of anticoagulation therapy. After tumor shrinkage, NOACs may be effective and important treatment options for patients with both cancer and VTE; they have good efficacy and the ease of monitoring have the potential to improve the QOL of patients. Further studies are

needed to determine the requirements for using NOACs as initial or long-term prophylactic therapy for VTE in cancer patients.

**The authors state that they have no Conflict of Interest (COI).**

## References

1. Chew HK, Davies AM, Wun T, Harvey D, Zhou H, White RH. The incidence of venous thromboembolism among patients with primary lung cancer. *J Thromb Haemost* **6**: 601-608, 2008.
2. Sorensen HT, Mellekjær L, Olsen JH, Baron JA. Prognosis of cancers associated with venous thromboembolism. *N Engl J Med* **343**: 1846-1850, 2000.
3. Levitan N, Dowlati A, Remick SC, et al. Rates of initial and recurrent thromboembolic disease among patients with malignancy versus those without malignancy. Risk analysis using Medicare claims data. *Medicine* **78**: 285-291, 1999.
4. Lyman GH, Bohlke K, Khorana AA, et al. Venous thromboembolism prophylaxis and treatment in patients with cancer: American society of clinical oncology clinical practice guideline update 2014. *J Clin Oncol* **33**: 654-656, 2015.
5. Mandala M, Falanga A, Roila F. Management of venous thromboembolism (VTE) in cancer patients: ESMO Clinical Practice Guidelines. *Ann Oncol* **22**: vi85-vi92, 2011.
6. Kearon C, Akl EA, Ornelas J, et al. Antithrombotic therapy for VTE disease: CHEST guideline and expert panel report. *Chest* **149**: 315-352, 2016.
7. Buller HR, Decousus H, Grosso MA, et al. Edoxaban versus warfarin for the treatment of symptomatic venous thromboembolism. *New Engl J Med* **369**: 1406-1415, 2013.
8. Prins MH, Lensing AW, Bauersachs R, et al. Oral rivaroxaban versus standard therapy for the treatment of symptomatic venous thromboembolism: a pooled analysis of the EINSTEIN-DVT and PE randomized studies. *Thromb J* **11**: 21-30, 2013.
9. Palareti G, Cosmi B, Legnani C, et al. D-dimer testing to determine the duration of anticoagulation therapy. *N Engl J Med* **355**: 1780-1789, 2006.
10. Di Minno A, Frigerio B, Spadarella G, et al. Old and new oral anticoagulants: food, herbal medicines and drug interactions. *Blood Rev* **31**: 193-203, 2017.
11. Sato T, Tsujino I, Ikeda D, Ieko M, Nishimura M. Trousseau's syndrome associated with tissue factor produced by pulmonary adenocarcinoma. *Thorax* **61**: 1009-1010, 2006.
12. Varki A. Trousseau's syndrome: multiple definitions and multiple mechanisms. *Blood* **110**: 1723-1729, 2007.
13. Ansell J, Hirsh J, Hylek E, Jacobson A, Crowther M, Palareti G. Pharmacology and management of the vitamin K antagonists: American College of Chest Physicians Evidence-Based Clinical Practice Guidelines (8th Edition). *Chest* **133**(Suppl): 160S-198S, 2008.
14. Granger CB, Alexander JH, McMurray JJ, et al. Apixaban versus warfarin in patients with atrial fibrillation. *N Engl J Med* **365**: 981-992, 2011.
15. Connolly SJ, Ezekowitz MD, Yusuf S, et al. Dabigatran versus warfarin in patients with atrial fibrillation. *N Engl J Med* **361**: 1139-1151, 2009.
16. Ay C, Dunkler D, Marosi C, et al. Prediction of venous thromboembolism in cancer patients. *Blood* **116**: 5377-5382, 2010.
17. Khorana AA, Kamphuisen PW, Meyer G, et al. Tissue factor as a predictor of recurrent venous thromboembolism in malignancy: biomarker analyses of the CATCH trial. *J Clin Oncol* **35**: 1078-1085, 2017.

The Internal Medicine is an Open Access article distributed under the Creative Commons Attribution-NonCommercial-NoDerivatives 4.0 International License. To view the details of this license, please visit (<https://creativecommons.org/licenses/by-nc-nd/4.0/>).