

Received: 2013.04.02
Accepted: 2013.05.06
Published: 2013.07.24

Laparoscopic resection of colonic lipomas: When and why?

Authors' Contribution:
Study Design A
Data Collection B
Statistical Analysis C
Data Interpretation D
Manuscript Preparation E
Literature Search F
Funds Collection G

ABDEF 1 **Deniz Eren Böler**
ABEF 2 **Bilgi Baca**
ABDE 1 **Cihan Uras**

1 Department of General Surgery, Acıbadem University Medical Faculty, İstanbul, Turkey
2 Department of General Surgery, İstanbul University Cerrahpaşa Medical Faculty, İstanbul, Turkey

Corresponding Author: Böler Deniz Eren, e-mail: denniseren@yahoo.com and dboler@asg.com.tr

Patient: Male, >60
Final Diagnosis: Colonic lipoma
Symptoms: Rectal bleeding • abdominal pain • fatigue • abdominal distention
Medication: —
Clinical Procedure: Laparoscopic resection
Specialty: General surgery

Objective: We aimed to review and discuss the clinical picture and management of 4 patients who underwent laparoscopic colonic resection with a definitive pathology of colonic lipoma

Background: Colonic lipomas are rare benign nonepithelial tumors of the colon. They begin to be symptomatic when they reach a certain size, although the presentation can vary. Different endoscopic and surgical treatment strategies have been reported in the literature.

Case Reports: Four male patients who underwent laparoscopic colonic resection and had definitive diagnosis of colonic lipoma were included in this report. All patients were over 60 years old. The first case presented with massive rectal bleeding. Obstructive symptoms and intermittent bleeding were prominent in the second and third cases. Abdominal pain and discomfort was present in the fourth case. In the first 2 cases, abdominal CTs were suggestive of colonic lipoma and laparoscopic ileocecal resection was performed. However, malignancy could not be ruled out in the other 2 cases due to large size and heterogeneous appearance of the lesions and inconclusive endoscopic biopsies consisted of ulcer with exudate and inflammatory cells. Laparoscopic left and right hemicolectomy was performed in the third and fourth cases, respectively. There were no complications in any patients.

Conclusions: Laparoscopic resection can be the first choice in treatment of colonic lipomas with various presentations. Wider resections should be considered in cases with uncertain diagnosis.

Key words: colonic lipoma • laparoscopic resection

Full-text PDF: <http://www.amjcaserep.com/download/index/idArt/889247>



Background

Colonic lipomas are rare, nonepithelial benign tumors of the gastrointestinal system. Whereas small lipomas are asymptomatic, the larger ones produce nonspecific symptoms like abdominal pain, rectal bleeding, and change in bowel habits. Once they are symptomatic, surgery is the only treatment. The clinical challenge is the differential diagnosis of lipomas from malignant processes in the absence of specific findings. Because radical resection is mandatory in the latter, a lipoma must be specifically diagnosed before surgery. Colonic lipomas in the literature are case reports and there is a diversity of operative techniques. With the increasing application of laparoscopic surgery, laparoscopic resection may be the first choice, especially in cases with any suspicion of malignancy with all the well known advantages of minimally invasive surgery.

Case Report

Between 2001 and 2010, 4 patients with colonic lipoma were managed with laparoscopic approach. Presenting symptoms, site of the tumor, type of laparoscopic resections, and postoperative results were evaluated. The patients' characteristics and results are summarized in Table 1.

Surgical procedure

Laparoscopic ileocecal resections and hemicolectomies were done via 4 ports. Intracorporeal resection was done. The specimen was retrieved through a mini-Pfannenstiel incision and extracorporeal anastomosis was performed. A silicone non-suction drain was placed in the pelvis.

All the patients were male and over 60 years old. They applied to the hospital with different clinical presentations and malignant processes were tried to be ruled out. In the first 2 cases, the CT images of the lesions were typical of lipoma with fatty composition but this could not be verified with endoscopic punch biopsy. The patients were operated on with a preoperative diagnosis of cecal lipoma, so laparoscopic ileocecal resection was done. In the other 2 cases, the lesions had atypical appearances resulting from ulcerations and patchy necrosis. The endoscopic punch biopsy revealed only an ulcer with exudate and inflammatory cells. Malignancy could not be ruled out, so radical resections according to oncological principles were performed. The postoperative period was uneventful in all patients and median hospital stay was 6 days. In all patients, definitive pathology was colonic lipoma.

Discussion

Colonic lipomas are nonepithelial benign tumors, which are most common in the fifth and sixth decades of life. Female predominance has been reported [1–3], but other authors have found no sex predilection [4].

The incidence is estimated about 0.035–4.9% because they are rarely symptomatic unless they reach a certain size [4,5]. They are mostly solitary, but may be multiple in 6–20% of cases [1,3,4] and are usually located in the cecum and ascending colon [1,6,7].

The symptoms occur in about one-fourth of patients with lipomas [8]. Abdominal pain and discomfort, change in bowel habits, diarrhea, and rectal bleeding or even melena can be seen [1,8]. They may have serious consequences like life-threatening hemorrhage, intussusception, and intestinal obstruction. Even spontaneous expulsion has been reported [9].

In a review by Chung et al., 16 colonic lipomas were found in 10 658 patients [10]. The most common symptom was mild bleeding from the rectum. Right-sided lipomas were palpable and left-sided ones were associated with obstructive symptoms [10]. Rogy et al. suggested that the clinical manifestations were associated with size of the lipoma rather than the involved segment of the colon [4]. When diameter exceeds 2 cm, symptoms are likely to appear, whereas nearly all over 3.5 cm are symptomatic. Smaller lesions are found incidentally with increased use of colonoscopy and they can be managed endoscopically [2,11,12]. All 4 cases in our study were over 3 cm in size and had different clinical presentations. Colonoscopic appearances of these lesions were not typical for lipoma due to ulceration. Endoscopic removal was not attempted by the attending gastroenterologist in any of them.

Preoperative diagnosis is important for planning; however, due to variable presentation and appearance, discrimination from malignant lesions can be difficult. There are different modalities for diagnosis of colonic lipomas. They are seen as an ovoid, well demarcated radiolucent mass in barium enema series [9]. "Squeeze sign" is the change of a lipoma into a fusiform appearance with the colonic peristalsis, but it is not totally reliable because if the lesion is located in the right colon or ulcerated it is hard to differentiate from colonic malignancy [3,5]. A barium enema series was not performed in our patients. Instead, colonoscopy and abdominal CT scans were used for diagnosis.

Colonic lipomas are usually seen as a submucosal mass covered by normal colonic mucosa at colonoscopy [9]. Elevation of mucosa by the biopsy forceps ("tent sign"), indentation by pressing on it ("cushion sign"), or extrusion of fat after biopsy

Table 1. Patient's characteristics and clinical presentations.

	Case 1	Case 2	Case 3	Case 4
Age	65	65	63	74
Gender	Male	Male	Male	Male
Complaints	Rectal bleeding	Fatigue and dyspnea Crampy abdominal pain and intermittent hematochesia associated with nausea and vomiting	Abdominal distention, difficulty in defecation and bloody stools	Abdominal pain and discomfort
Location of the lipoma	Cecum	Cecum and ileum	Transverse colon	Cecum
Colonoscopic findings	Blood in the ascending colon and ulcerated polypoid mass in the ileocecal region	Multiple polyps in the ascending and transverse colon and mobile polyp in the terminal ileum	Ulcerated mass in the splenic flexura leading to near complete obstruction	Broad based polypoid lesion with superficial ulcerations
Abdominal CT	3×2 cm mass in the cecum with density of fatty tissue	2.7×1.8×1.8 cm mass in the cecum protruding into the distal ileum with density of fatty tissue	7×7×4 cm heterogenous mass at the level of splenic flexura	Heterogenous mass in the cecum measuring about 6 cm
Type of the operation	Laparoscopic ileocecal resection	Laparoscopic ileocecal resection	Laparoscopic left hemicolectomy	Laparoscopic right hemicolectomy
Size of the lipoma	3.5×2.1×2 cm	3.3×1.8×2 cm	7.8×6.5×3.5 cm	7.2×6.0×5.5 cm
Postoperative hospital stay	5 days	6 days	7 days	6 days
Definitive pathology	Ulcerated lipoma	3,3cm lipoma in the terminal ileum and a second 2cm lipoma located in the submucosa and diffuse adipose tissue in the ileocecal valve; Colonic adenomas without dysplasia	Lipoma with superficial ulcerations and patchy necrosis	Ulcerated lipoma

("naked fat sign") can also be seen [5,13,14]. Sometimes necrotic mucosa, ulceration, and relatively hard texture of the lesion make it difficult to differentiate from a malignant lesion [1]. When the lesion is actively bleeding, endoscopic biopsy may not be safe and reliable. In the present cases, the endoscopic biopsies were done without subsequent complications but were not definitive because the sampled tissue showed ulcer base with exudate and inflammatory cells. Adipocytes or malignant cells were not seen in pathology.

Computed tomography has been reported to be the most useful tool for detection of these lesions [2,15–17]. Generally, they are seen as spherical or ovoid masses with absorption densities of –40 to –120 Hounsfield units, typical of fat [15,18]. CT appearance may be atypical if fat necrosis or infarction is

present [19]. For large colonic lipomas and acutely ill patients, CT and MRI may be more useful in showing fatty composition of the tumor [20]. Despite the diagnostic tools, differentiation from malignant processes is the main challenge before surgical resection [3,15,19,21]. In 2 cases, CT findings were highly suggestive of lipoma, so a limited resection was performed. In the other 2 patients, malignancy could not be ruled out with CT, colonoscopy, and endoscopic biopsy, so radical resections according to oncological principles were done.

The second case had a past history of abdominal cramps and constipation for several days with spontaneous regression without further treatment. After oral intake of contrast material, the signs and symptoms resolved and only a mass in the cecum was seen in CT images. After colonoscopy, an ileal

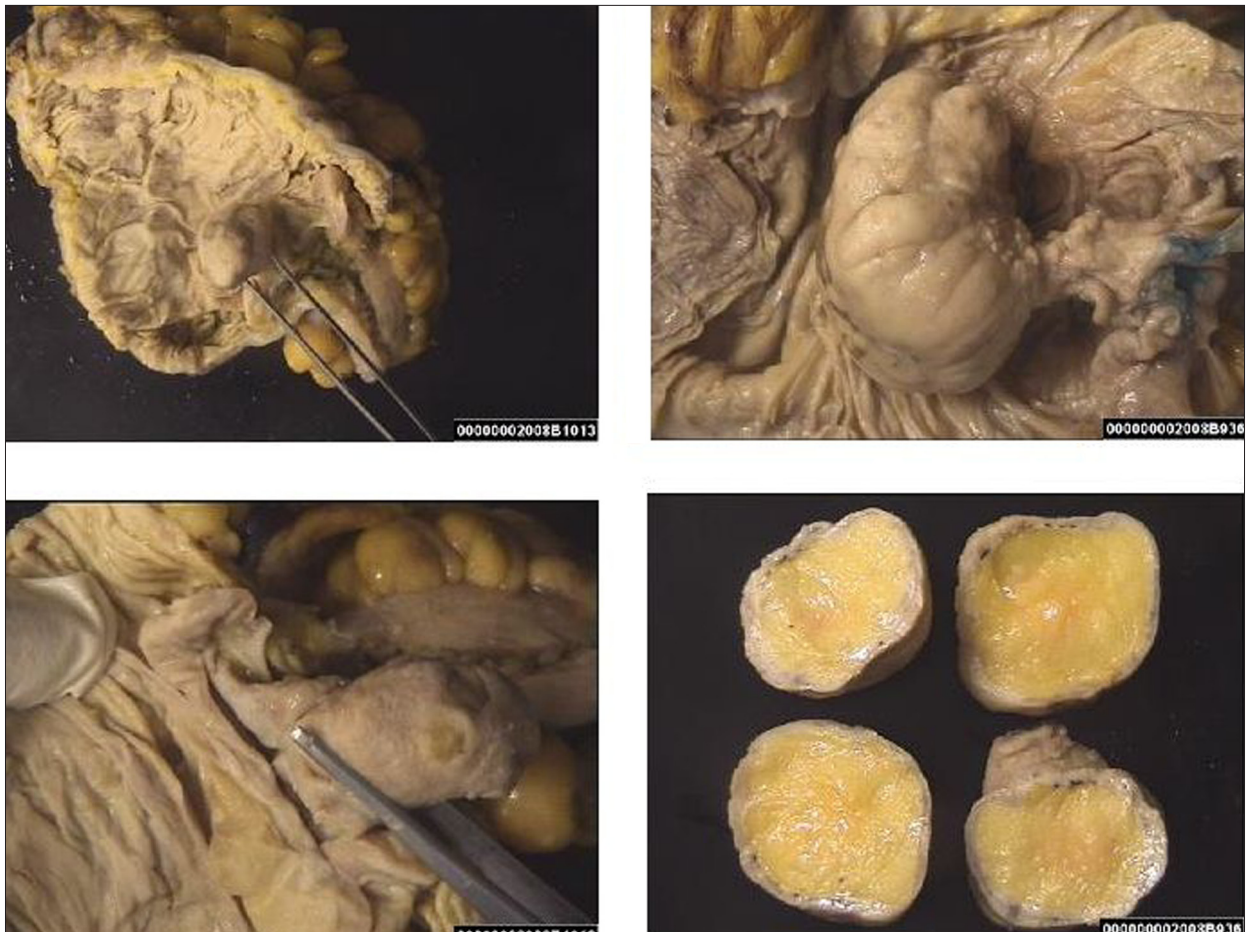


Figure 1. Macroscopic appearance of the specimen.

mass was seen and intussusception due to the ileal mass and spontaneous reduction was suggested. Adult intussusception is hard to diagnose due to variable presentation and vague symptoms unless pathognomonic appearance is seen in ultrasonography (USG) or CT. The great majority of adult intussusceptions are definable causes, which are mostly neoplasia. In adult intussusception, the colonic lead points are more frequently malignant than small bowel lead points [22–24], whereas the most common benign condition leading to intussusception is lipomas [25]. Wang et al. reported that 100% of colocolonic intussusceptions were malignant and recommended primary surgical resection without reduction but for ileocolonic intussusceptions reduction or surgery was equivocal [26]. If the cause of adult intussusception cannot be identified preoperatively, the surgery should be planned as if the condition is malignant unless proven otherwise because of the high incidence of malignancy. Large polypoid lesions can harbor invasive carcinoma. The dysplastic adenomas are concomitant findings and were biopsied with a snare in the present case. Although they were contained in the specimen, final pathology showed no dysplasia. If colonic lipomas are associated with other lesions, larger resection margins may be required.

The management strategy for colonic lipomas mainly depends on the size, clinical symptoms, and preoperative diagnosis. Endoscopic removal of colonic lipomas is considered, especially for asymptomatic lesions smaller than 2 cm [2,5,11,27] and safely removed colonic lipomas larger than 2 cm have been reported [11,13]. However, lipomas require more electrical current for transection, which increases the risk of perforation and bleeding, especially in sessile lesions [14]. The risks for complications like hemorrhage or perforation increase [2,11,28,29] or complete excision cannot be done because the size is larger [30]. Surgical resection is the best choice of treatment for large and symptomatic lipomas [5,31]. Several types of operations have been reported. Limited resections are considered adequate for preoperatively diagnosed colonic lipomas [16,31]. Hemicolectomy and even subtotal colectomy may be done, especially when malignancy cannot be excluded preoperatively or complications occur [5,17,21,32]. Whatever the clinical implication, surgery creates a large wound in certain cases. Minimally invasive techniques offer some advantages over conventional surgery. In several studies comparing laparoscopic resection with open surgery for colonic polyps, laparoscopic colectomy was found to have a shorter period of ileus,

less postoperative pain, and shorter hospital stay and recovery period [33–35]. Laparoscopic approach also offers diagnostic advantages in cases with suspicion of malignancy and in elderly patients with comorbid medical conditions [36]. In cases of ileocecal or colocolonic intussusception, laparoscopic approach provides a safe resection and shortens the operative period without additional morbidity, although it is not critical for prognosis in benign lesions of the colon [8,37–40].

On the other hand, there are some limitations of laparoscopic procedures. The first, limitation is the location. Tattooing or intraoperative colonoscopy may be helpful in these situations. CT colonography is highly predictive for localization of the lesions, especially when extensive resection is planned. Extensive resection also overcomes the difficulty in accurate location of the lesion, especially in emergency conditions [37,41–45]. The second limitation is that extensive resections may require extensive mobilization of the remaining colon to accomplish a tension-free anastomosis. The third limitation is that laparoscopic resection may be more time consuming for inexperienced surgeons.

The extent of the resection primarily depends on the preoperative diagnosis. If the preoperative diagnosis is benign, limited resection can be the treatment of choice. However, preferring a radical resection, even in benign cases, is not irrational because

it is technically easier and eliminates a second operation when an unexpected malignancy is diagnosed in the final pathological examination. Laparoscopic ileocecal resection was performed in 2 patients in whom the preoperative diagnosis was colonic lipoma (Figure 1). However, laparoscopic right hemicolectomy and laparoscopic left hemicolectomy were done in the other 2 patients with high risk of malignancy to eliminate need for a second operation. There were no preoperative or postoperative complications, including atelectasia, urinary retention, or wound infection, despite old age and comorbidities of the patients.

Conclusions

The clinical presentation of colonic lipomas may be anywhere in the spectrum between asymptomatic lesions and life-threatening complications. Laparoscopic resection can be the first choice (1) in patients with unclear preoperative diagnosis and (2) complicated cases like intussusception, in addition to (3) lipomas not suitable for endoscopic removal, (4) whenever endoscopic removal cannot be performed safely with negative margins, and (5) lipomas located in the muscular or serosal layer. Laparoscopic resection is a good alternative to open conventional surgery with all the known advantages of minimally invasive procedures.

References:

1. Jiang L, Jiang LS, Li FY et al: Giant submucosal lipoma located in the descending colon: a case report and review of the literature. *World J Gastroenterol*, 2007; 13(42): 5664–67
2. Pfeil SA, Weaver MG, Abdul-Karim FW, Yang P: Colonic lipomas: outcome of endoscopic removal. *Gastrointest Endosc*, 1990; 36: 435–38
3. Mischowitz M, Lazebink N, Noy S, Lazebink R: Lipoma of the colon: a report of 22 cases. *Am Surg*, 1985; 51: 449–54
4. Zhang H, Cong JC, Chen CS et al: Submucous colon lipoma: a case report and review of the literature. *World J Gastroenterol*, 2005; 11(20): 3167–69
5. Ryan J, Martin JE, Pollock DJ: Fatty tumours of the large intestine: a clinicopathological review of 13 cases. *Br J Surg*, 1989; 76: 793–96
6. Tascilar O, Çakmak GK, Gün BD et al: Clinical evaluation of submucosal colonic lipomas: decision making. *World J Gastroenterol*, 2006; 12(31): 5075–77
7. Ladurner R, Mussack T, Hohenbleicher F et al: Laparoscopic assisted resection of giant sigmoid lipoma under colonoscopic guidance. *Surg Endosc*, 2003; 17(1): 160
8. Jelenc F, Brencic E: Laparoscopically assisted resection of an ascending colon lipoma causing intermittent intussusception. *J Laparoendosc Adv Surg Tech A*, 2005; 15: 173–75
9. Ghidirim G, Mishin I, Gutsu E et al: Giant submucosal lipoma of the cecum: report of a case and review of the literature. *Romanian J Gastroenterol*, 2005; 14(4): 393–96
10. Chung YF, Ho YH, Nyam DC et al: Management of colonic lipomas. *Aust N Z J Surg*, 1998; 68: 133–35
11. Kim CY, Bandres D, Tio TL et al: Endoscopic removal of large colonic lipomas. *Gastrointest Endosc*, 2002; 55: 929–31
12. Liessi G, Pavenello M, Cesari S et al: Large lipomas of the colon: CT and MR findings in three symptomatic cases. *Abdom Imaging*, 1996; 21: 150–52
13. Bahadursingh AM, Robbins PL, Longo WE: Giant submucosal sigmoid colon lipoma. *Am J Surg*, 2003; 186: 81–82
14. Messer J, Wayne JD: The diagnosis of colonic lipomas-the naked fat sign. *Gastrointest Endosc*, 1982; 28: 186–88
15. Rogy MA, Mirza D, Berlakovich G et al: Submucous large-bowel lipomas-presentation and management. An 18-year study. *Eur J Surg*, 1991; 157: 51–55
16. Nakagoe T, Sawai T, Tsuji T et al: Minilaparotomy approach for removal of a large colonic lipoma: report of two cases. *Surg Today*, 2004; 34: 72–75
17. Rogers So Jr, Lee MC, Ashley SW: Giant colonic lipoma as lead point for intermittent colo-colonic intussusception. *Surgery*, 2002; 131: 687–88
18. Notaro JR, Masser PA: Annular colon lipoma: a case report and review of the literature. *Surgery*, 1991; 110: 570–72
19. Buetow PC, Buck JL, Carr NJ et al: Intussuscepted colonic lipomas: loss of fat attenuation on CT with pathologic correlation in 10 cases. *Abdom Imaging*, 1996; 21: 153–56
20. Liessi G, Pavenello M, Cesari S et al: Large lipomas of the colon: CT and MR findings in three symptomatic cases. *Abdom Imaging*, 1996; 21: 150–52
21. Bardaji M, Roset F, Camps R et al: Symptomatic colonic lipoma: differential diagnosis of large bowel tumors. *Int J Colorectal Dis*, 1998; 13: 1–2
22. McKay R: Ileocecal Intussusception in an adult: the laparoscopic approach. *JLS*, 2006; 10: 250–53
23. Azar T, Berger DL: Adult intussusception. *Ann Surg*, 1997; 226: 134–38
24. Nagorney DM, Sarr MG, McIlrath DC: Surgical management of intussusception in the adult. *Ann Surg*, 1981; 193: 230–36
25. Hozo I, Perkovic D, Grandic L et al: Colonic lipoma intussusception: a case report. *Med Arch*, 2004; 58: 382–83
26. Wang LT, Wu CC, Yu JC et al: Clinical entity and treatment strategies for adult intussusceptions: 20 years' experience. *Dis Colon Rectum*, 2007; 50: 1941–49
27. Tamura S, Yokoyama Y, Morita T et al: "Giant" colon lipoma: what kind of findings are necessary for the indication of endoscopic resection? *Am J Gastroenterol*, 2001; 9: 1944–46

28. Raju GS, Gomez G: Endoloop ligation of a large colonic lipoma: a novel technique. *Gastrointest Endosc*, 2005; 62: 988–90
29. Yarze JC: Coloscopic resection of an asymptomatic colon lipoma. *Gastrointest Endosc*, 2006; 63: 890–91
30. Nivatvongs S: Complications in colonoscopic polypectomy: lessons to learn from an experience with 1576 polyps. *Am Surg*, 1988; 54: 61–63
31. Cirino E, Cali V, Basile G et al: Intestinal invagination caused by colonic lipoma. *Minerva Chir*, 1996; 51: 717–23
32. Alponat A, Kok KY, Goh PM et al: Intermittent subacute intestinal obstruction due to a giant lipoma of the colon: a case report. *Am Surg*, 1996; 62: 918–21
33. Eijssbouts QA, Heuff G, Sietses C et al: Laparoscopic surgery in the treatment of colonic polyps. *Br J Surg*, 1999; 86: 505–8
34. Joo JS, Amarnath L, Wexner SD: Is laparoscopic resection of colorectal polyps beneficial? *Surg Endosc*, 1998; 12: 1341–44
35. Young-Fadok TM, Radice E, Nelson H, Harmsen WS: Benefits of laparoscopic-assisted colectomy for colon polyps: a case-matched series. *Mayo Clinic Proc*, 2000; 75: 344–48
36. Lo SH, Law WL: Laparoscopic colorectal resection for polyps not suitable for colonoscopic removal. *Surg Endosc*, 2005; 19(9): 1252–55
37. Saclarides TJ, Ko ST, Airan M et al: Laparoscopic removal of a large colonic lipoma. Report of a case. *Dis Colon Rectum*, 1991; 34: 1027–29
38. Alonso V, Targarona EM, Bendehan GH et al: Laparoscopic treatment for intussusception of the small intestine in the adult. *Surg Laparosc Endosc Percutan Tech*, 2003; 13: 394–96
39. Chekan EG, Westcott C, Low VH et al: Small bowel intussusception and laparoscopy. *Surg Laparosc Endosc Percutan Tech*, 1998; 8: 324–26
40. Park KT, Kim SH, Song TJ et al: Laparoscopic resection of ileal lipoma causing ileo-ileocolic intussusception. *J Korean Med Sci*, 2001; 16: 119–22
41. Chiu C, Wei PL, Huang MT et al: Colonoscopic-assisted laparoscopic resection of a colon lipoma. *J Laparoendosc Adv Surg Tech*, 2006; 16(1): 37–40
42. Hensman C, Luck AJ, Hewett PJ: Laparoscopic-assisted colonoscopic polypectomy: technique and preliminary appearance. *Surg Endosc*, 1999; 13: 231–32
43. Franklin ME Jr, Diaz EJA, Abrego G et al: Laparoscopic assisted colonoscopic polypectomy: The Texas Endosurgery Institute experience. *Dis Colon Rectum*, 2000; 43: 1246–49
44. Fu KI, Fujii T, Kato S et al: A new endoscopic tattooing technique identifying the location of colonic lesions during laparoscopic surgery: a comparison with the conventional technique. *Endoscopy*, 2001; 33: 687–91
45. Montorsi M, Opocher E, Santambrogio R et al: Original technique for small colorectal tumor localizatin during laparoscopic surgery. *Dis Colon Rectum*, 1999; 42: 819–22