

Tissue expansion in the treatment of giant congenital melanocytic nevi of the upper extremity

Tengxiao Ma, Master^a, Ke Fan, Bachelor^b, Lei Li, Doctor^a, Feng Xie, Master^a, Hao Li, Master^a, Haiyan Chou, Master^a, Zhengwen Zhang, Doctor^{a,*}

Abstract

The aim of our study was to use tissue expansion for the treatment of giant congenital melanocytic nevi of the upper extremity and examine potential advantages over traditional techniques.

There were 3 stages in the treatment of giant congenital melanocytic nevi of the upper extremities using tissue expansion: first, the expander was inserted into the subcutaneous pocket; second, the expander was removed, lesions were excised, and the wound of the upper extremity was placed into the pocket to delay healing; third, the residual lesion was excised and the pedicle was removed. The pedicle flap was then unfolded to resurface the wound.

During the period between June 2007 and December 2015, there were 11 patients with giant congenital melanocytic nevi of the upper extremities who underwent reconstruction at our department with skin expansion. Few complications were noted in each stage of treatment. The functional and aesthetic results were observed and discussed in this study.

Optimal aesthetic and functional results were obtained using tissue expansion to reconstruct the upper extremities due to the giant congenital melanocytic nevi.

Abbreviation: TBSA = total body surface area.

Keywords: flap, giant congenital melanocytic nevi, reconstruction, tissue expansion, upper extremities

1. Introduction

Expanded full-thickness or split-thickness skin grafts have been previously applied to treat giant congenital melanocytic nevi of the upper extremities. However, patients undergoing such treatment are often dissatisfied in the follow-up, which drove plastic surgeons to develop improved techniques.

Tissue expansion was applied by Radovan, an American plastic surgeon, in 58 cases of post-mastectomy breast reconstruction, which provided optimal color matching, improved texture, and minimum malformation.^[1] Since this initial development, this technique was employed to reconstruct involved extremities and has been widely used in plastic and reconstructive surgery as a significant routine procedure over the last 20 years.^[2] Tissue expansion was considered a paradigm shift in plastic surgery,^[3] and the crucial key was that donor skin

possessed the same characteristics, including similar texture, color, hair follicles, and sensation in the transplanted area.^[4,5]

Therefore, the aim of this study was to examine the use of tissue expanders in reconstructing upper extremities in patients with giant congenital melanocytic nevi. The second objective was to determine any advantages over traditional techniques.

2. Materials and methods

2.1. Patients

During the period between June 2007 and December 2015, a total of 11 patients (5 males accounting for 45.5%, 6 females accounting for 54.5%) with giant congenital melanocytic nevi of the upper extremities, involving 13 expanders (Guangzhou Wanhe Plastic Materials Co. Ltd.) from 400 mL to 500 mL, were treated with tissue expansion in Henan Provincial People's Hospital, China. Patient ages ranged from 3 to 21 years, and the average age of patients was 6.6 ± 4.99 years old. Circumferential lesions were identified in each patient, 2 of which were throughout the hand and forearm. Skin involvement ranged from 3% to 7%, with the average extent 5.5% of total body surface area (TBSA). This study was approved by the institutional ethics committee. Informed consent was obtained from each patient.

2.2. Surgical technique

There were 3 stages to the surgical procedure. Patients were positioned in the lateral position after administration of general anesthesia.

2.3. The first stage

It was essential to design the most optimal donor location for the insertion and incision of expander prior to operating. In order to

Editor: Mahmood S. Choudhery.

Informed consent was received for publication of the figures in this article.

The authors have no funding and conflicts of interest to disclose.

^a Department of Plastic Surgery, ^b Department of Operating Theater, Henan Provincial People's Hospital, Zhengzhou City, Henan Province, China.

* Correspondence: Zhengwen Zhang, Department of Plastic Surgery, Henan Provincial People's Hospital, Zhengzhou City, Henan Province, China (e-mail: mt_x_198628@163.com).

Copyright © 2017 the Author(s). Published by Wolters Kluwer Health, Inc. This is an open access article distributed under the terms of the Creative Commons Attribution-Non Commercial-Share Alike 4.0 License, which allows others to remix, tweak, and build upon the work non-commercially, as long as the author is credited and the new creations are licensed under the identical terms.

Medicine (2017) 96:13(e6358)

Received: 15 August 2016 / Received in final form: 1 February 2017 / Accepted: 19 February 2017

<http://dx.doi.org/10.1097/MD.0000000000006358>

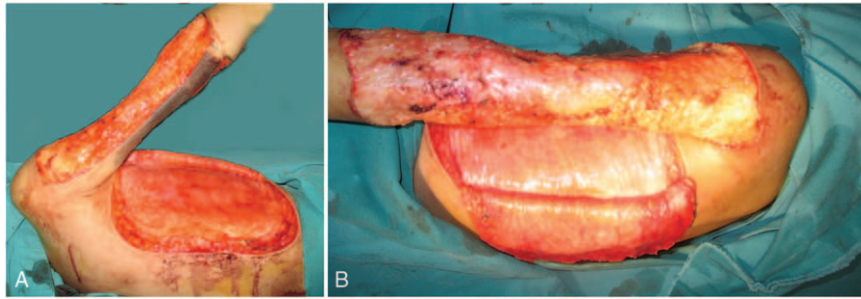


Figure 1. Second stage of the procedure. The designed flap was harvested, and then the expander removed. Lesions were excised and the lesion tissue with a width of 2 cm remained in the inner side of the upper extremity: (A) anterior aspect; (B) superior aspect.

find the optimal donor location, the upper extremity was put against the flank. Based on the body surface area in which the lesions occupied, the volume and number of the expander were decided. When the lesion was localized to the forearm or upper arm, 1 expander was inserted in the appropriate position of the back of the patient where the upper limb lesion was against, using the appropriate size expander, slightly longer than the lesion length. For example, the length of a 500 mL expander is 125 mm. When the lesion invaded the whole upper limb, 2 or more expanders were inserted to acquire sufficient skin. For the opisthenar lesion, 1 appropriate size expander was inserted into the abdomen subcutaneously. 0.5% lidocaine, coupled with 1:200000 epinephrine, was injected into the subcutaneous tissue of the location for insertion of the expander. A longitudinal incision, parallel to the midaxillary line was made, and the subcutaneous pocket was stripped on superficial layer of deep fascia. The dimension of the pocket was 1 cm larger than that of the expander. The expander was then inserted into the pocket, together with the drainage tube, which was removed within approximately 3 to 5 days after the operation, when the suctioned fluid became serous. The filling valves were buried in the subcutaneous tissue. The wound was closed with nylon sutures. During the operation, approximately 20% of the expander volume was injected. Perioperative antibiotics were used, primarily a first-generation cephalosporin. Expansion commenced 2 weeks after the insertion of the expander, and saline was injected once a week. The expansion

generally lasted 8 to 12 weeks. The expander was kept for at least 2 weeks after full expansion with no continuous injection before delivery.

2.4. The second stage

Before the operation, it was necessary to design the expansion flaps that would be transferred. The width of the flap was designed on the basis of the length of the nevus, and the length of the flap was arm circumference. The expanded flap with a random pattern was at the width-to-length ratio of more than 1:3. The designed flap was harvested, and then the expander was removed. The expander capsule was removed partially so the expansion flap unfolded. Most lesions were excised and the lesion tissue with the width of 2 cm remained in the inner side of upper extremity (Fig. 1). For the defect of the upper extremity generated by excision of the nevi, the expansion flap was transferred to cover it. For the remaining lesion tissue, 2-side margins were stitched with respectively the lateral thoracic wall and distal expansion flap to close the wound (Fig. 2). In some cases, a wound cavity was left near the axilla generally filled with tela iodoformum. External fixation was used for binding and immobilizing, which could protect the pedicle flap from avulsion and hemorrhage from mobility.

2.5. The third stage

Three weeks after transfer, the pedicle flap was generally separated from the trunk (Fig. 3). The area of the remaining lesion was based to design the incision on the pedicle flap. The residual lesion was excised and the pedicle was removed according to the designed incision (Fig. 4). The pedicle flap was unfolded to resurface the wound. The secondary defect of the donor site was sutured in a direct manner. Segmented grafts from the groin region or back area were applied to close the defect. The patients retained baseline functional capacity of the upper extremity after the third-stage of treatment.

3. Results

Patients were followed up from 3 months to 5 years. Among 13 expanders, 2 expanders demonstrated 2 complications in the first stage of treatment. A hematoma was found in 1 patient due to active bleeding in the pocket. An incision was made to prevent further bleeding. The other complication demonstrated was during the period of expansion. The filling valve was exposed in 1 patient. However, the external valve was used to complete

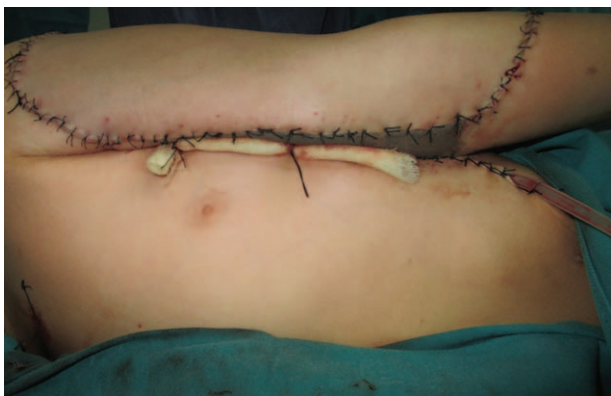

Figure 2. For the remaining lesion tissue, 2-sided margins were stitched with respectively the lateral thoracic wall and distal expansion flap to close the wound.

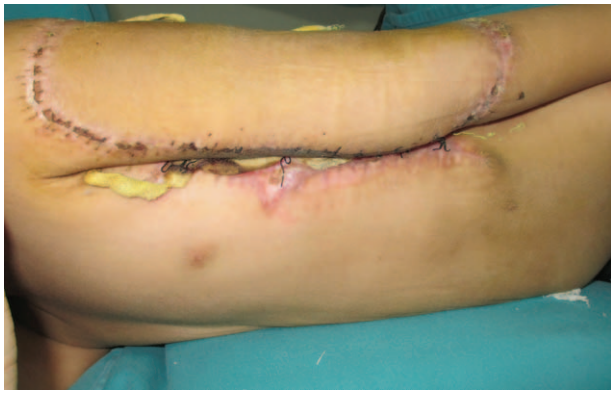

Figure 3. Operative site prior to the third operation.

the injection. During the second stage of treatment, in 1 patient, the transferred flap developed distal tip necrosis (2 cm × 1.5 cm) in the upper extremity. This was treated with debridement and dressing for 2 weeks. No malignant melanomas were shown in the pathological examination of the resection specimen. A close match existed in terms of tissue color, texture, and retention of sensibility, which led to good functional and aesthetic results.

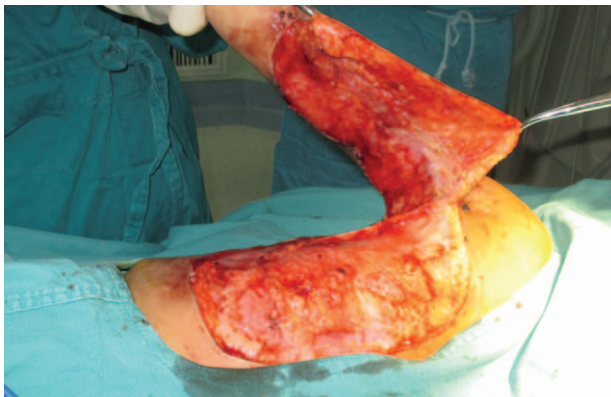

Figure 4. Third stage: the residual lesion was excised and the pedicle was removed, according to the designed incision.

3.1. Typical case report

In 2009, the patient, a 4-year-old boy, presented with a giant circumferential nevus throughout the elbow joint and the upper arm. The lesion contributed approximately 5% of TBSA (Fig. 5). The nevus was recommended to be excised. Prior to surgery, family members were informed of surgical risks and advantages, as well as the potential of malignancy. A staged expanded flap technique was used. The patient underwent general anesthesia in every procedure. An inflatable rectangular expander (500 mL) was used and then inserted into the left lateral thoracic wall (Fig. 6). In accordance with the above procedures, surgical treatment was executed. The expanded flap was used to reconstruct the soft-tissue defects produced by the nevi section, except the defect (7 cm × 4.5 cm) in the thoracic wall. Full-thickness skin graft from the back area was applied to close the defect in the thoracic wall. Through pathological diagnosis, intradermal nevi were identified in the specimens resected from 2 steps. Following surgery, the patient reported stiffness with flexion restriction of the elbow joint, but recovered after 1 month of functional training. During follow-up over the next 6 months, the function of the upper arm and elbow joint remained unhindered. The skin in the surgery area was soft in texture with flat scars and no hyperplasia. Some scars remained in the thoracic wall (Fig. 7). The parents of the patients were fundamentally satisfied with the results of surgery.

4. Discussion

Melanocytic nevi are hematomas comprising of a surplus of nevocytes, penetrating each layer of the skin. Melanocytic nevi affect approximately 1% of newborns.^[6] Giant congenital melanocytic nevi are very uncommon, and the occurrence rate is 1 in 50,000 births.^[7] The definition of giant congenital melanocytic nevi is a lesion affecting 2% of TBSA in newborns^[8] and toddlers, or a diameter larger than 20 cm in older children and teenagers.^[9] The underlying malignant potential of giant congenital melanocytic nevi is a primary concern, alongside significant cosmetic impairment. Recent recommendations suggest treating nevi early, as related lifetime risk of melanoma is 4% to 10%.^[10] Various approaches can be used for the treatment of nevi, such as curettage, dermabrasion, surgical excision, and laser therapy.^[11] Surgical removal, however, is the only technique that can remove all of the nevus cells present. Therefore, surgical intervention is regarded as the treatment option of choice in treating nevi.^[12]

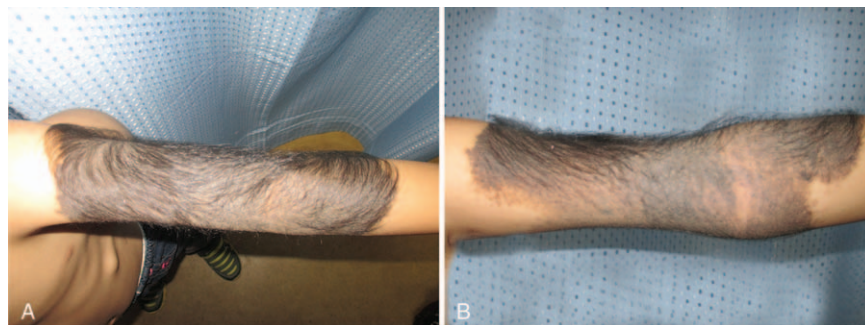


Figure 5. A 4-year-old boy presented with a giant circumferential nevus throughout the elbow joint and the upper arm. The lesion made up 5% of TBSA: (A) superior aspect of the lesion; (B) anterior aspect of the lesion. TBSA = total body surface area.

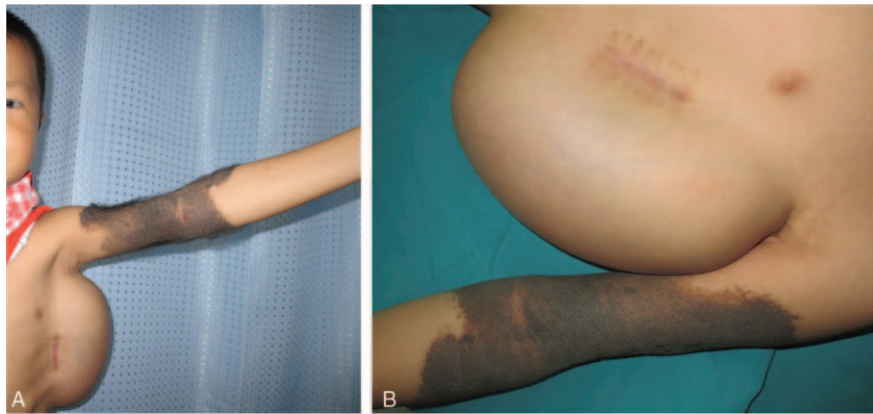


Figure 6. The expansion procedure was completed: (A) standing position and (B) horizontal position.

However, the point at which surgical intervention should be undertaken remains controversial. From the perspective of doctors in our department, reconstruction is best completed at pre-school age. The appearance of the nevi often impacts psychologically on patients, especially those of a younger age. Second, patients at pre-school age are relatively compliant toward the periods of expansion, immobilization, and functional training. Third, optimal skin elasticity at a pre-school age offers improved tissue expansion.^[13] Furthermore, from reports in the literature, younger patients are more likely to undergo melanocytic transformation.^[14]

Generally, giant congenital melanocytic nevi are distributed in the whole upper extremities. Therefore, formation of local flap is not practical. Split-thickness skin grafting was used prior to 2007 to complete the reconstruction of the affected extremity. However, patients were often dissatisfied with treatment, which drove specialists to seek another improved technique. This is mainly accounted for by several reasons. First, there was obvious color difference between the transplanted skin area and normal skin. Second, malformations often occurred at the donor site. Some patients were disappointed due to hypertrophic scars of the donor site. Lastly, in line with the growth of patients, the scars negatively influence the development of the upper extremities due to scar contraction. Therefore, it is found that tissue expansion can provide more optimal color match, improved texture and minimum malformation of the donor site when the above factors are taken into account.

It is controversial whether the expander capsule should be removed in the second stage.^[15] We consider that limited radial division of the capsule along the edge is necessary. A thickened

band is often formed by the capsule at the base of the expander, which is shown along the excision edge of the flap.^[3] Due to the restriction of flap advancement by the capsule, the removal of the capsule is beneficial to unfold and flatten the expansion flap so as to realize the utilization to the maximum extent. Furthermore, the adhesion between the wound and the flap is beneficial to promote formation of a blood supply. However, the procedure is often of a long duration and bleeding is increased due to capsulectomy; therefore, division of the capsule should be limited.

In the first stage of treatment, 15.38% of patients developed minor complications. Based on experience, various measures can be undertaken in order to decrease surgical complications. First, as one of the most common complications, hematoma formation is closely related with inadequate drainage, continual bleeding, and unsatisfied stripping. Therefore, after the pocket is stripped, bleeding should be stopped. It is essential to examine the suction drain before banding up in order to ensure sufficient drainage. Second, infection, another common complication, is often found in or after the first stage. Perioperative antibiotics can be applied to prevent infection. An aseptic technique must be adopted during the period of expansion. Third, it is important to avoid exposure of the expander due to incision dehiscence. Formation of a subcutaneous pocket is expected to be larger than the dimensions of the expander. Nylon sutures are used to close the wound in layers in order to decrease the tension of incision. Furthermore, the incision is expected to be 1 cm from the edge of the expander. In addition, it is also recommended that patients do not engage in excessive activity after surgery.

With regard to the 2 patients with lesions throughout hand and forearm, 2 expanders were inserted in the upper back and lateral

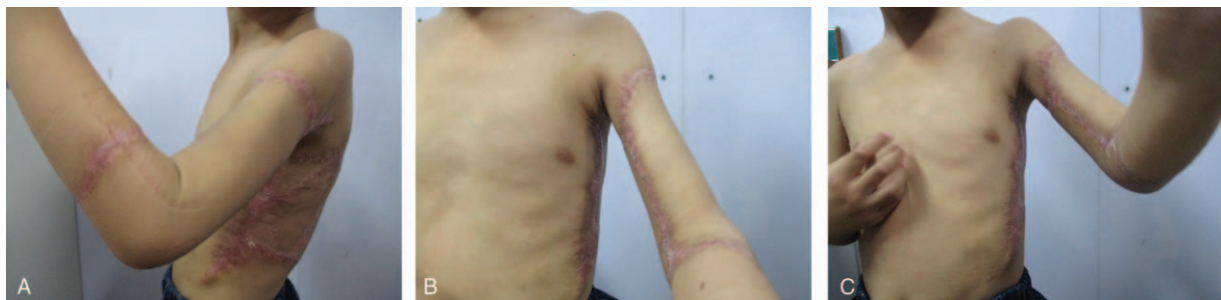

Figure 7. (A) The skin in the surgical area was soft with flat scars and no evidence of hyperplasia. Some scars were left in the thoracic wall. (B and C) 6-month follow-up showed that the function of the upper arm and elbow joint was unremarkable.

thoracic wall, respectively. In the forearm, an expanded delayed flap was applied from the upper back. In the patient who had a nevi located on the hand, we used a thin, pliable expander full-thickness skin graft. Thus, optimal functional and aesthetic results were obtained in the upper extremity.

During follow-up, for patients undergoing treatment, the function of the elbow joint and upper arm was unremarkable. The skin in the surgical area was soft in the texture with flat scars and no hyperplasia. However, scarring was still present in the thoracic wall. For 1 patient with significant scars, the problem was addressed with an expanded flap on the back. All patients were satisfied with the results of the procedures. For 1 female patient, at 8-year follow-up, she had normal limb motor function; however, the transferred flap was of a greater thickness, and the surgical limb is thicker compared with contralateral limb. However, the reasons for these findings are not clear.

However, the technique discussed here does have some limitations. First, due to multiple stages in nevus removal, many hospital visits and financial costs are incurred. Second, some patients after treatment were stiff with flexion restriction of the elbow joint due to long-time immobilization, although most recovered after 1-month of functional training.

5. Conclusions

The approach of expanded pedicle flaps is employed to treat giant congenital melanocytic nevi of the upper extremities. Indeed, tissue expansion can offer improved color matching, better texture, and minimum malformation of the donor site. Improved aesthetic and functional results are achieved by tissue expansion to treat giant congenital melanocytic nevi of the upper extremities compared with traditional approaches.

References

- [1] Radovan C. Breast reconstruction after mastectomy using the temporary expander. *Plast Reconstr Surg* 1982;69:195–208.
- [2] Dzonov B, Daskalov O, Noveski L, et al. Tissue expansion in limbs vs other body regions. *Prilozi* 2014;35:219–25.
- [3] Hudson DA, Lazarus D, Silfen R. The use of serial tissue expansion in pediatric plastic surgery. *Ann Plast Surg* 2000;45:589–94.
- [4] Vander Kolk CA, McCann JJ, Knight KR, et al. Some further characteristics of expanded tissue. *Clin Plast Surg* 1987;14:447–53.
- [5] Argenta LC, Marks MW, Pasyk KA. Advances in tissue expansion. *Clin Plast Surg* 1985;12:159–71.
- [6] Walton RG, Jacobs AH, Cox AJ. Pigmented lesions in newborn infants. *Br J Dermatol* 1976;95:389–96.
- [7] Rhodes AR. Melanocytic precursors of cutaneous melanoma: estimated risks and guidelines for management. *Med Clin North Am* 1986;70:3–7.
- [8] Lorentzen M, Pers M, Bretteville-Jensen G. The incidence of malignant transformation in giant pigmented nevi. *Scand J Plast Reconstr Surg* 1977;11:163–7.
- [9] Quaba AA, Wallace AF. The incidence of malignant melanoma (0 to 15 years of age) arising in “large” congenital nevocellular nevi. *Plast Reconstr Surg* 1986;78:174–81.
- [10] Kopf AW, Bart RS, Hennessey P. Congenital nevocytic nevi and malignant melanomas. *J Am Acad Dermatol* 1979;1:123–30.
- [11] Corcoran J, Bauer BS. Management of large melanocytic nevi in the extremities. *J Craniofac Surg* 2005;16:877–85.
- [12] Gosain AK, Santoro TD, Larson DL, et al. Giant congenital nevi: a 20-year experience and an algorithm for their management. *Plast Reconstr Surg* 2001;108:622–36.
- [13] Liu Y, Huang J, Wen K, et al. Treatment of giant congenital melanocytic nevus of the left upper extremity with staged expanded flap. *J Plast Reconstr Aesthet Surg* 2012;65:258–63.
- [14] Bittencourt FV, Marghoob AA, Kopf AW, et al. Large congenital melanocytic nevi and the risk for development of malignant melanoma and neurocutaneous melanocytosis. *Pediatrics* 2000;106:736–41.
- [15] Morris SF, Pang CY, Mahoney J, et al. Effect of capsulectomy on the hemodynamics and viability of random-pattern skin flaps raised on expanded skin in the pig. *Plast Reconstr Surg* 1989;84:314–22. discussion 323–324.