



Case Report

Combined anterior and posterior cruciate ligaments avulsion from the tibial side in adult patient: case report[☆]

Marcos George de Souza Leão*, Erika Santos Santoro, Rafael Lima Avelino, Ronan Campos Granjeiro, Nilton Orlando Junior

Orthopedics and Traumatology Service, Fundação Hospital Adriano Jorge, Manaus, AM, Brazil

ARTICLE INFO

Article history:

Received 27 February 2013

Accepted 22 March 2013

Keywords:

Fractures bone

Anterior cruciate ligament

Posterior cruciate ligament

Knee/surgery

Therapeutics

Palavras-chave:

Fraturas ósseas

Ligamento cruzado anterior

Ligamento cruzado posterior

Joelho/cirurgia

Terapia

ABSTRACT

The authors describe a rare case of a 28-year-old male patient, victim of motorcycle crash, with direct impact on the right knee, who sustained a bicruciate ligament fracture avulsion from the tibial side, dislocated and with large dimensions, without associated ligamentary lesions; he has undergone surgical treatment – open reduction and internal fixation, of the avulsions, and the follow up was at least six months, presenting good outcome using the Tegner–Lysholm scale.

© 2013 Sociedade Brasileira de Ortopedia e Traumatologia. Published by Elsevier Editora Ltda. Este é um artigo Open Access sob a licença de [CC BY-NC-ND](#)

Fratura avulsão simultânea das inserções tibiais dos ligamentos cruzados anterior e posterior em adulto

RESUMO

Os autores relatam o raro caso de um paciente de 28 anos, vítima de acidente de moto, com trauma direto no joelho direito, que apresentou fratura avulsão das inserções tibiais dos ligamentos cruzados anterior e posterior, desviadas e de grandes dimensões, sem outras lesões ligamentares associadas, sem similar na literatura. O paciente foi submetido a tratamento cirúrgico com fixação das avulsões. Com seguimento ambulatorial de seis meses, evoluiu com bom resultado.

© 2013 Sociedade Brasileira de Ortopedia e Traumatologia. Publicado por Elsevier Editora Ltda. Este é um artigo Open Access sob a licença de [CC BY-NC-ND](#)

Introduction

Injuries to the cruciate ligaments of the knee are typically of intrasubstance nature, with tears to collagen fibers. Less

frequently, they imply avulsion fractures at the insertion location, generally on the tibial surface. Avulsions of the cruciate ligaments of the knee can be seen well on routine radiographs. Thus, they enable diagnosis of this specific type of injury and, depending on the classification of the fracture; they may be

[☆] Work performed at Fundação Hospital Adriano Jorge, Manaus, AM, Brazil.

* Corresponding author.

E-mail: mgsleao@uol.com.br (M.G. de Souza Leão).

treated either conservatively or surgically, which will both produce good results. Over the last decade, arthroscopic fixation of avulsions of the cruciate ligaments has become popular, along with open fixation. The choice of surgical technique and fixation material, as well as the results, depend on the type of fracture and particularly on the size, displacement, comminution and orientation of the avulsed fragment.¹

We report a rare case, without any similar cases in the literature, of a patient who was a victim in a motorcycle accident, with displaced avulsion fractures of both cruciate ligaments of the knee, at their tibial insertions, which were treated surgically.

Case report

The patient was a 28-year-old man who was a victim in a motorcycle accident, with direct trauma to his right knee. He was initially attended at the emergency service, where the initial radiographs were produced (Figs. 1 and 2), which showed a tibial avulsion fracture of the anterior and posterior cruciate ligaments. His leg was immobilized from the inguinal region to the foot and he was sent to our outpatient service. We examined him and applied the Tegner-Lysholm questionnaire (35 points). He presented a painful knee, effusion ++/4, Lachmann ++, anterior drawer + and posterior drawer ++, and was negative for varus and valgus stress. Computed tomography (Fig. 3) and magnetic resonance (Fig. 4) were requested. The diagnosis was confirmed and the avulsions were classified as Meyers and McKeever III-B for the anterior tibial spine and

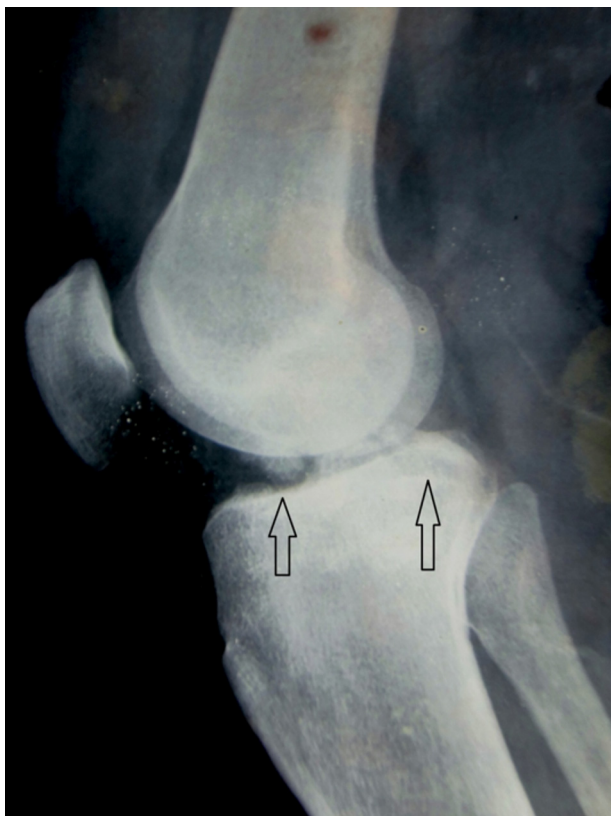

Fig. 1 – AP radiograph of the knee (arrow).

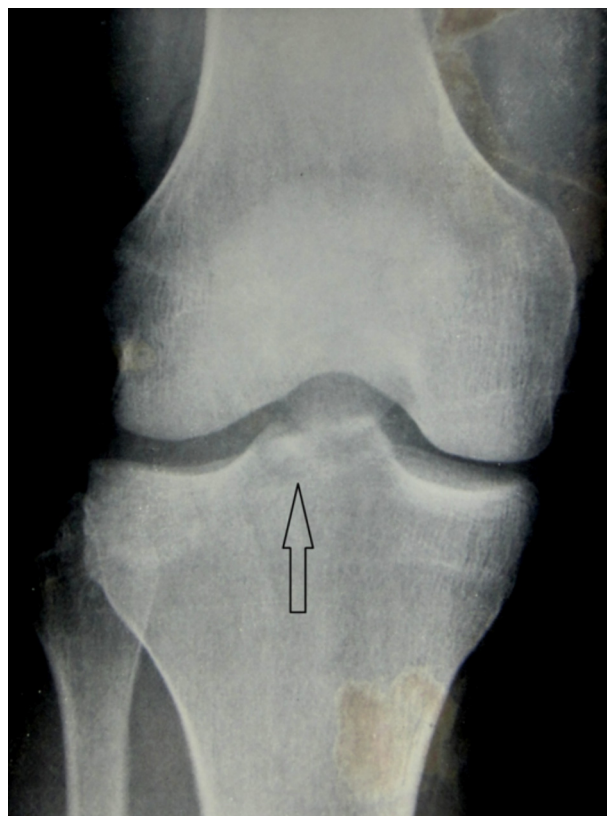

Fig. 2 – Lateral radiograph of the knee (arrow).

II for the avulsion of the posterior cruciate ligament. Because of the magnitude of the fragment displacement (the posterior fragment extended to the tibial plateau) and the time that had elapsed since the trauma, it was decided to perform open reduction of both avulsions.

The patient underwent the surgical procedure 21 days after the trauma. He was initially positioned in horizontal ventral decubitus, which is the position enabling posterior access to the knee as recommended by Burks and Schaffer.¹ The reduction was performed and internal fixation of the posterior fracture was achieved using two 3.5 mm spongy screws and washers. Following this, the patient was repositioned in horizontal dorsal decubitus and the surgical fields were changed so as to enable anterior access. Limited medial parapatellar arthrotomy (mini mid-vastus) was performed, followed by reduction and internal fixation of the anterior spine, also with two 3.5 mm spongy screws with washers (Fig. 5). There was no meniscal interposition at the focus of the fracture.

The patient was discharged from hospital two days after the surgery, with an immobilizer, prophylactic antibiotics and prophylaxis for deep vein thrombosis (enoxaparin sodium, 40 mg, for 15 days), and was instructed not to put his body weight on the operated limb.

Fifteen days after the operation, physiotherapy consisting of isotonic and isometric exercises was started. On the 30th day after the operation, the patient attained range of motion of 0–90°. On the 60th day of follow-up, the patient presented range of motion of 0–100°, with radiographs that showed consolidation of the fractures and absolutely anatomical

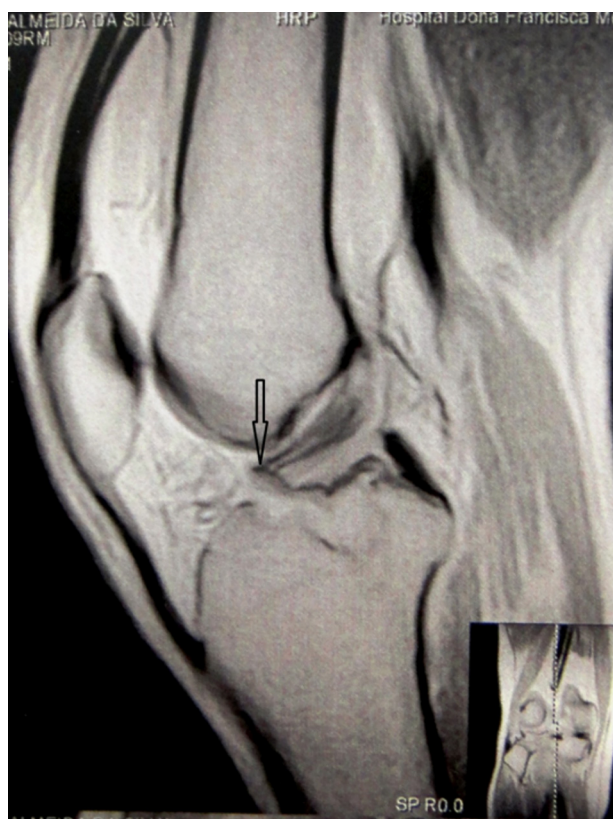

Fig. 3 – Computed tomography slice showing displaced posterior fragment.

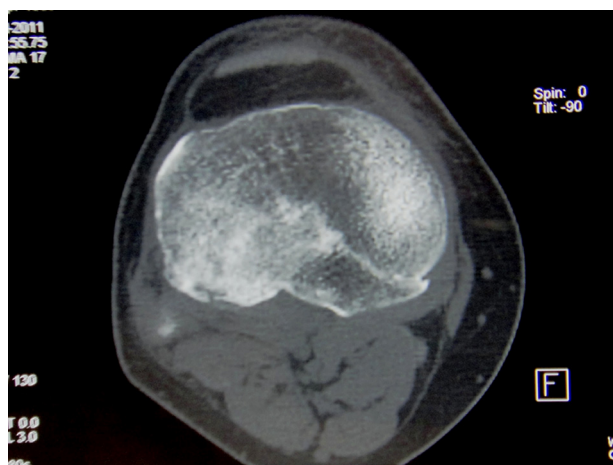


Fig. 4 – Magnetic resonance image showing wrenching of tibial spine (arrow).

reduction of the spines. He was then allowed to partially bear weight on the limb, with crutches. After 10 weeks of follow-up, he was released for full weight-bearing, while continuing with the rehabilitation protocol.

From then on, the patient was followed up every month at the knee disease outpatient clinic of our institution until the sixth month, when new radiographs were produced. At that consultation, the patient was reassessed by another knee

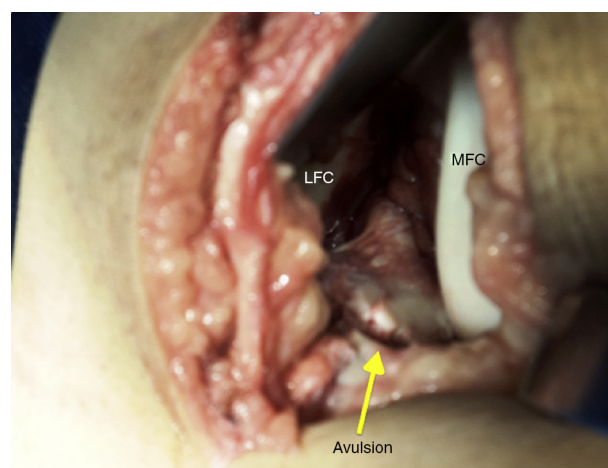


Fig. 5 – During the operation, showing large fragment of the tibial spine (arrow). LFC – lateral femoral condyle; MFC – medial femoral condyle.

specialist surgeon who had not participated in the surgical procedure. This assessment showed that the patient was free from symptoms. He had already returned to his habitual working activities. The Tegner–Lysholm knee evaluation score was measured as 94 points (good result); his range of motion was 0–115°; he was negative for Lachmann maneuvers, negative for anterior and posterior drawers, negative for pivot shift and negative for varus and valgus stress; and his radiographs showed consolidated tibial spines (Fig. 6). Outpatient discharge was therefore given.

Discussion

Knee ligament injuries are a frequent topic in large number of published scientific papers, particularly injuries of the anterior cruciate ligament (ACL). However, over the last few years, injuries of the posterior cruciate ligament (PCL) have received special attention, as confirmed by the increasing number of articles dealing with this ligament. From an anatomical point of view, the ACL originates from the anterior intercondylar area of the tibia, immediately behind the fixation of the medial meniscus. Its insertion is in the posterior part of the medial face of the lateral condyle of the femur, and its main function is to block anterior displacement of the tibia in relation to the femur. The PCL is fixed to the anterior half of the lateral face of the medial femoral condyle, and it projects caudally and medially through the intercondylar notch, toward its tibial insertion, which is located posteriorly, inferiorly and juxtalaterally to the medial line of the tibial plateau. It acts as the main posterior stabilizer of the knee and restricts posterior tibial translation in relation to the femur.²

Avulsion fractures of the ACL are rare injuries in adults and occur in 1–5% of the injuries to this ligament.³ Fractures of the intercondylar eminence are better described in the pediatric orthopedic literature and occur at lower frequency in adults. Thus, the bibliography on this subject is very limited.⁴ Even in children, these injuries are uncommon, affecting only three in every 100,000, and the anterior tibial spine is injured ten times

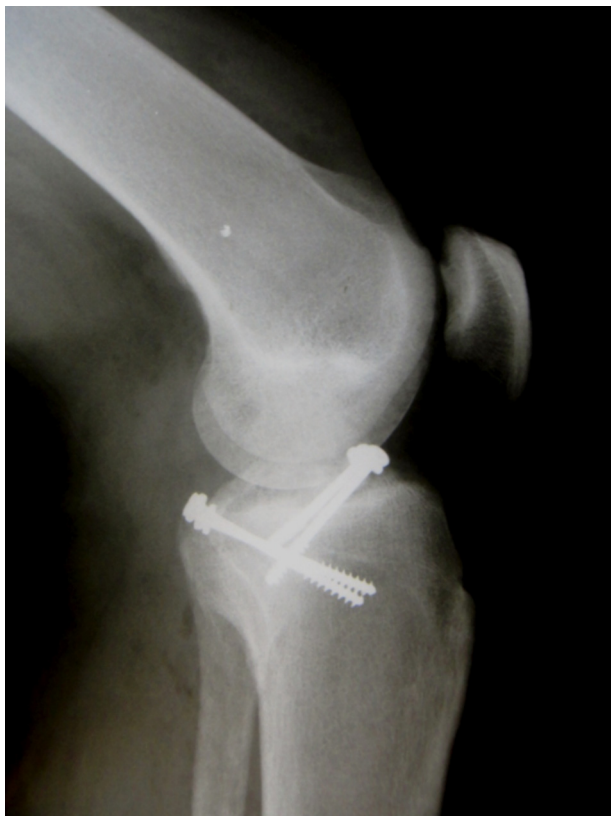

Fig. 6 – Radiograph of the knee six months after the operation, showing anatomical reduction and consolidation.

more frequently than the posterior tibial insertion.⁵ When an avulsed fragment is displaced, primary fixation is indicated in order to prevent anterior impact in extension, residual laxity and non-consolidation of fragments and preservation of the native ACL. Several surgical treatments have been proposed for these injuries, going from the conventional open procedure to inclusion of arthroscopic methods, which were first described by McLennan in Ochiai et al. in 1982,⁶ with a number of fixation methods: Kirschner wires, cannulated screws, sutures with steel or polyester wires, anchors and EndoButton®. While the results from primary fixation in skeletally immature patients are good, the treatments in adults present variable results, and some authors have reported high rates of incidence of postoperative complications.³

In 1970, Meyers and McKeever⁷ proposed a classification system for fractures of the anterior tibial spine in children, based on the degree of displacement of the fragment. The injuries were divided into three types, but no classification for avulsed fractures of the PCL was reported. Subsequently, this classification was modified by Zaricznyj,⁸ who added a further subtype. This classification system made it possible to define the best treatment in relation to each type of fracture: Type I – without displacement or with minimal displacement of the fragment; Type II – angular elevation of the anterior portion with full posterior hinging; Type III – complete displacement with or without rotation; Type IV – comminuted. Griffith et al.⁹ modified the classification of Meyers and

McKeever and expanded these concepts to avulsion fractures of the PCL.

There is still some controversy regarding the surgical indications for treating PCL injuries but, for avulsion fractures, surgical reinsertion of the fragment is the procedure indicated.⁹ Tibial avulsion fractures of the PCL are a small subgroup that differs from other injuries to this ligament in two ways: firstly, early diagnosis is generally possible using standard radiographs in which the bone fragment can be viewed; and secondly, there is no simplified standardized treatment protocol for posterior approaches to the knee.¹⁰

Several authors have emphasized that surgical reinsertion of the PCL fragment produces better results than conservative treatment. Surgery makes it possible to perform measures such as deepening of the site of tibial insertion of the PCL and rigid fixation of the bone fragment, which can be done using screws and washers or non-absorbable thread. These measures may assist in retensioning the ligament and, consequently, in improving the clinical evolution.⁹ Furthermore, the time that elapses between the injury and the surgical procedure is an important factor to be considered. Over the last few years, new options for fixation of bone fragments have been evaluated, along with new proposals for surgical approaches toward these injuries, such as controlling the reduction under arthroscopic viewing.

To treat ACL or PCL avulsions, it is recommended that fractures without displacement (Type I) should be treated conservatively; moderately displaced fractures (Type II) can be managed conservatively or surgically; and displaced fractures (Type III) and comminuted fractures (Type IV) are surgical indications.⁹ The type of surgical treatment depends on the size and degree of comminution of the avulsed fracture. Fixation of the avulsed tibial insertion of the PCL can be done by means of a conventional open route, or arthroscopically. The latter is less aggressive but it requires equipment and an experienced surgeon. Trickey described a surgical technique with a posterior access route in the knee, open reduction and fixation of the avulsed fragment. Burks and Schaffer¹ used a simplified access route for the posterior approach to the knee. Arthroscopic reduction and fixation are difficult and require a longer learning curve. Therefore, reduction and fixation can be achieved by means of a simplified open access route, particularly a posterior route, which can be used in any center. In 2011, Shelbourne et al.¹¹ reported in a review of the current literature that the commonest forms of treatment for this type of injury might equally be open or arthroscopic reduction, although controversy remained regarding which treatment method was best.¹¹ In 2012, Hapa et al.¹² conducted a biomechanical study on sheep and affirmed that fixation using EndoButton® for fractures of the tibial eminence produced initial fixation strength that was greater than with fixation using anchors or other types of suture. Recently, Gui et al.¹³ contraindicated arthroscopic fixation for avulsions of the PCL presenting large fragments with an effect going as far as the tibial plateau. In such situations, because of the difficulty in achieving the necessary elevation and exposure of the focus of the fracture, the best option is open fixation using screws.

For functional evaluation, Lysholm and Gillquist developed a scale of knee symptoms. The Lysholm scale includes

basic aspects of the Larson scale, but introduces the criterion of instability and correlates it with activity. This scale was subsequently modified by Tegner and Lysholm. These authors recognized the difficulty in having a score for ligament injuries and decided at that juncture to investigate clinical findings and evaluate symptoms and functions. This scale or questionnaire by Lysholm is composed on eight questions, with options for closed responses, in which the final result is expressed in nominal and ordinal form, such that “excellent” is 95–100 points, “good” is 84–94 points, “fair” is 65–83 points and “poor” is less than or equal to 64 points.¹⁴

The interest in presenting this case arises because this is a rare episode of simultaneous avulsion fractures of the cruciate ligaments at their tibial sites, for which no similar published papers are available in the literature. For this case, we chose to perform fixation of the two fractures as if they were separate injuries. Despite the gravity of the trauma and the surgical complexity, the patient evolved satisfactorily, both from the functional and from the mechanical point of view, using the Lysholm questionnaire and the usual maneuvers to verify ligament stability.

Conflicts of interest

The authors declare no conflicts of interest.

REFERENCES

- Burks RT, Schaffer JJ. A simplified approach to the tibial attachment of the posterior cruciate ligament. *Clin Orthop Relat Res.* 1990;254:216–9.
- Piedade SR, Mischon MM. Surgical treatment of avulsion fractures of the knee PCL tibial insertion: experience with 21 cases. *Acta Ortop Bras.* 2007;15(5):272–5.
- Montgomery KD, Cavanaugh J, Cohen S, Wickiewicz TL, Russell F, Warren RF, et al. Motion complications after arthroscopic repair of anterior cruciate ligament avulsion fractures in the adult. *Arthroscopy.* 2002;18(2):171–6.
- Toye LR, Cummings DP, Armendariz G. Adult tibial intercondylar eminence fracture: evaluation with MR imaging. *Skeletal Radiol.* 2002;31(1):46–8.
- Ponseller PD, Stanisti CL. Fraturas e luxações na região do joelho. In: Beaty J, Kasser J, editors. *Rockwood e Wilkins: fraturas em crianças.* 5a. ed. Manole: São Paulo; 2004. p. 1038–44.
- Ochiai S, Hagino T, Watanabe Y, Senga S, Haro H. One strategy for arthroscopic suture fixation of tibial intercondylar eminence fractures using the Meniscal Viper Repair System. *Sports Med Arthrosc Rehabil Ther Technol.* 2011;3(1):17.
- Meyers MH, McKeever FM. Fracture of the intercondylar eminence of the tibia. *J Bone Joint Surg Am.* 1970;52(8):1677–84.
- Zaricznyj B. Avulsion fracture of the tibial eminence: treatment by open reduction and pinning. *J Bone Joint Surg Am.* 1977;59(8):1111–4.
- Griffith JF, Antonio GE, Tong CWC, Ming CK. Cruciate ligament avulsion fractures. *Arthroscopy.* 2004;20(8):803–12.
- Dhillon MS, Singh HP, Nagi OP. Posterior cruciate ligament avulsion from the tibia: fixation by a posteromedial approach. *Acta Orthop Belg.* 2003;69(2):162–7.
- Shelbourne KD, Urch SE, Freeman H. Outcomes after arthroscopic excision of the bony prominence in the treatment of tibial spine avulsion fractures. *Arthroscopy.* 2011;27(6):784–9.
- Hapa O, Barber FA, Süner G, Özden R, Davul S, Bozdağ E, et al. Biomechanical comparison of tibial eminence fracture fixation with high-strength suture. EndoButton, and suture anchor. *Arthroscopy.* 2012;28(5):681–7.
- Gui J, Wang L, Jiang Y, Wang Q, Yu Z, Gu Q. Single-tunnel suture fixation of posterior cruciate ligament avulsion fracture. *Arthroscopy.* 2009;25(1):78–85.
- Peccin MS, Ciconelli R, Cohen M. Questionário específico para sintomas do joelho Lysholm Knee Scoring Scale: tradução e validação para a língua portuguesa. *Acta Ortop Bras.* 2006;14(5):268–72.