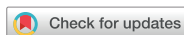

Original Article  
Internal Medicine



# Clinical assessment and grading of back pain in horses

Abubakar Musa Mayaki <sup>1,2</sup>, Intan Shameha Abdul Razak <sup>1,\*</sup>,  
Noraniza Mohd Adzahan <sup>3</sup>, Mazlina Mazlan <sup>4</sup>, Abdullah Rasedee <sup>5</sup>

<sup>1</sup>Department of Veterinary Preclinical Sciences, Faculty of Veterinary Medicine, Universiti Putra Malaysia, 43400 Serdang, Selangor, Malaysia

<sup>2</sup>Department of Veterinary Medicine, Faculty of Veterinary Medicine, Usmanu Danfodiyo University, P.M.B 2346, City Campus Complex, Sokoto, Nigeria

<sup>3</sup>Department of Farm and Exotic Animal Medicine and Surgery, Faculty of Veterinary Medicine, Universiti Putra Malaysia, 43400 Serdang, Selangor, Malaysia

<sup>4</sup>Department of Veterinary Pathology and Microbiology, Faculty of Veterinary Medicine, Universiti Putra Malaysia, 43400 Serdang, Selangor, Malaysia

<sup>5</sup>Department of Veterinary Laboratory Diagnosis, Faculty of Veterinary Medicine, Universiti Putra Malaysia, 43400 Serdang, Selangor, Malaysia

 OPEN ACCESS

Received: Mar 9, 2020

Revised: Aug 23, 2020

Accepted: Aug 27, 2020

\*Corresponding author:

Intan Shameha Abdul Razak


Department of Veterinary Preclinical Sciences,  
Faculty of Veterinary Medicine, Universiti Putra  
Malaysia, 43400 Serdang, Selangor, Malaysia.  
E-mail: intanshameha@upm.edu.my


© 2020 The Korean Society of Veterinary  
Science


This is an Open Access article distributed  
under the terms of the Creative Commons  
Attribution Non-Commercial License ([https://  
creativecommons.org/licenses/by-nc/4.0](https://creativecommons.org/licenses/by-nc/4.0))  
which permits unrestricted non-commercial  
use, distribution, and reproduction in any  
medium, provided the original work is properly  
cited.

ORCID iDs

Abubakar Musa Mayaki   
<https://orcid.org/0000-0001-9033-7149>

Intan Shameha Abdul Razak   
<https://orcid.org/0000-0001-6787-3621>

Noraniza Mohd Adzahan   
<https://orcid.org/0000-0002-8892-5037>

Mazlina Mazlan   
<https://orcid.org/0000-0001-5981-3522>

Abdullah Rasedee   
<https://orcid.org/0000-0001-6625-508X>

## ABSTRACT

**Background:** The clinical presentation of horses with back pain (BP) vary considerably with most horse's willingness to take part in athletic or riding purpose becoming impossible. However, there are some clinical features that are directly responsible for the loss or failure of performance.

**Objectives:** To investigate the clinical features of the thoracolumbar region associated with BP in horses and to use some of the clinical features to classify equine BP.

**Methods:** Twenty-four horses comprised of 14 with BP and 10 apparently healthy horses were assessed for clinical abnormality that best differentiate BP from normal horses. The horses were then graded (0–5) using the degree of pain response, muscular hypertonicity, thoracolumbar joint stiffness and overall physical dysfunction of the horse.

**Results:** The common clinical features that significantly differentiate horses with BP from non-BP were longissimus dorsi spasm at palpation (78.6%), paravertebral muscle stiffness (64.3%), resist lateral bending (64.3%), and poor hindlimb impulsion (85.7%). There were significantly ( $p < 0.05$ ) higher scores for pain response to palpation, muscular hypertonicity, thoracolumbar joint stiffness and physical dysfunction among horses with BP in relation to non-BP. A significant relationship exists between all the graded abnormalities. Based on the cumulative score, horses with BP were categorized into mild, mild-moderate, moderate and severe cases.

**Conclusions:** BP in horse can be differentiated by severity of pain response to back palpation, back muscle hypertonicity, thoracolumbar joint stiffness, physical dysfunctions and their cumulative grading score is useful in the assessment and categorization of BP in horses.

**Keywords:** Back pain; spinal abnormalities; clinical grading; horses

**Funding**

This study was supported by Fundamental Research Grant Scheme (FRGS/1/2017/SKK15/UPM/O2/2) from the Malaysian Ministry of Education.

**Conflict of Interest**

The authors declare no conflicts of interest.

**Author Contributions**

Conceptualization: Abdul Razak IS, Adzahan NM, Rasedee A; Data curation: Mayaki AM, Adzahan NM, Mazlan M; Formal analysis: Mayaki AM, Abdul Razak IS, Adzahan NM; Funding acquisition: Abdul Razak IS; Investigation: Mayaki AM; Writing - original draft: Mayaki AM, Abdul Razak IS, Rasedee A; Writing - review & editing: Mayaki AM, Abdul Razak IS, Adzahan NM, Mazlan M, Rasedee A.

**INTRODUCTION**

Back pain (BP) is a clinical condition that causes performance failure among athletic and riding horses [1]. BP in horses are of many aetiologies, although among the common causes are thoracolumbar musculoskeletal lesions, supraspinous desmitis, lameness, ill-fitting tack, and inadequate schooling [2-4]. Diagnosis of equine BP can be very challenging, because the condition is presented as a syndrome rather than with specific clinical signs. Thus, despite the availability of sophisticated clinical aids, definitive diagnosis of equine back injuries is most often made by eliminating other conditions.

Clinical manifestations in equine BP of primary and secondary causes may be similar. For example, lameness or neurological disorders involving the thoracolumbar and sacral region may be similarly presented with spinal muscular atrophy and abnormal gait [5-8]. Among methods of diagnosis of equine BP in the field is by visual inspection, palpation, and manipulation of thoracolumbar spine [9] and examination at exercise. Currently, there is no suitable grading system that can be conveniently used by practicing veterinarians to grade and quantify BP/disorders in horses. A validated and practical grading system would allow veterinarians to categorize back disorders for better therapeutic interventions, assessment, and monitoring of the conditions. In this study, we hypothesised that the influence of clinical and spinal abnormalities on the manifestations of equine BP vary with type and severity of abnormalities. Thus, the aim of the study was to develop a grading system for equine BP based on thoracolumbar spinal abnormalities and clinical features.

**MATERIALS AND METHODS****Animals**

Twenty-four patrolling or endurance horses from ambulatory cases of the University Veterinary Hospital, Universiti Putra Malaysia (UPM) were used in the study. The horses comprised of 14 with BP and 10 apparent healthy horses as normal. The ages, sex, and breeds were recorded. The study was with horse owner consents and approved by Institutional Animal Care and Use Committee, UPM (UPM/IACUC/AUP-R016/2018).

**Clinical examination**

Complete clinical examination was conducted on all the horses at rest to determine the general conformation of the thoracolumbar region, including epaxial and pelvic muscle development, symmetry, and spinal curvature. The thoracolumbar region was then palpated with firm but gentle digital pressure along the dorsal thoracolumbar midline. Avoidance reaction (i.e., sinking) to palpation was used as indicator of pain. Digital palpation was repeated to ensure consistency of clinical findings. Response to thoracolumbar flexibility was assessed by spinal manipulation: lateral bending and ventral and dorsal flexion. Conformational variations, response to palpation and spinal manipulation among the 2 groups were noted. The horses were trotted on a hard surface and in small circles to determine gait. Oral examination of the horses was performed to rule out influence of dental pain on gait.

**BP grading**

The assessment of the horses for BP grading was then performed by an independent equine veterinarian who was blinded of the clinical category of the horses. Spinal abnormalities were

**Table 1.** Grading of equine back pain based on the spinal structural and functional abnormalities

Parameter	Abnormality score (grade)					
	0 (absence)	1 (mild)	2 (mild-moderate)	3 (moderate)	4 (severe)	5 (incapacitated)
Pain response	No clinical evidence	Occasional, mild reaction to grooming or firm pressure only	Mild-moderate reaction to firm pressure	Moderate reaction with avoidance response to moderate pressure	Marked reaction with strong avoidance response to mild pressure	Marked generalized reaction
Muscle hypertonicity	No clinical evidence	Mild hypertonicity without fasciculations to firm pressure	Variable hypertonicity with pressure	Moderate unilateral or bilateral hypertonicity with fasciculations to moderate pressure	Marked hypertonicity with spontaneous fasciculations to pressure	Marked, generalized, and persistent muscle spasm
Lameness	No lameness observed	Inconsistent lameness at the trot that is difficult to discern under any circumstance	Lameness is difficult to observe at a walk or trot in a straight line, but consistently apparent under special circumstances	Consistent lameness at the trot and under all circumstances	Obvious lameness with marked asymmetry of gait at the trot without manipulation	Minimal or no weight bearing on the affected limb and reluctant to move
Thoracolumbar joint stiffness	No clinical evidence	Mild segmental stiffness	Stiffness from restricted muscle function	Moderate dorsoventral and unilateral bending	Marked reduced dorsoventral and bilateral bending	No flexibility
Physical dysfunction	Full functional activity	Able to walk and trot with mild restriction	Noticeable dysfunction during certain activities	Performs activities with much effort	Able to stand comfortably but resents activities	Unable to stand comfortably or perform at all levels

graded on a scale of 0 to 5 based on the developed guide: degree of pain response to back palpation, back muscle hypertonicity, thoracolumbar joint stiffness, and physical dysfunction (Table 1). Lameness was graded using the American Association of Equine Practitioners lameness grading scale [10]. The score for each horse was calculated and compared between categories of horses. Using the cumulative grading scores of pain response to palpation, muscle hypertonicity, thoracolumbar joint stiffness, and physical dysfunction, BP horses with cumulative score of 0 was classified as normal, mild (1–4), mild-moderate (5–8), moderate (9–12), marked (13–16), and incapacitated (17–20).

Total BP severity was calculated as follows:

$$\text{Total severity} = \text{Number of horses in each severity grade} \times \text{Grade of severity}$$

### Data analysis

The statistical analyses were conducted using GraphPad Prism version 8.0.2 (GraphPad Software, USA). Descriptive statistic was used to summarize the data and the scores for each abnormality expressed as mean ± standard deviation. The association between BP and clinical findings was determined using the Fisher's exact test. Differences between mean scores were analysed using the nonparametric Mann-Whitney *U* test. The relationship between spinal abnormalities in BP was determined using the Spearman's correlation. The *p* value < 0.05 was considered significant.

## RESULTS

### Breeds and frequency of BP

Among the horses 13/24 (54.2%) were geldings and 11/24 (45.8%) mares. The mean age of horses with BP was 14.9 ± 3.2 years while normal horses in the study was 12.3 ± 3.3 years old. Among horses with BP, the predominant breed was Warmblood (7/14, 50%) followed equally by thoroughbreds and Polo ponies (3/14, 21.4% each), and Criollo (1/14, 7.1%).

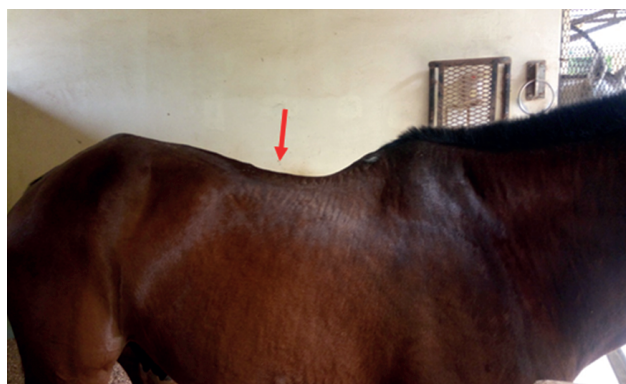
**Table 2.** Clinical features and signs in horses with BP

Clinical features/signs	Horse		p value
	BP (n = 14)	Non-BP (n = 10)	
Pain response to back digital pressure	14 (100.0)	0	< 0.000
Poor development of epaxial muscles	6 (42.9)	1 (10.0)	0.172
Moderate-to-good epaxial muscle development	8 (57.1)	9 (90.0)	0.172
Warm area at back region	4 (28.6)	0	0.114
Focalised back swelling	3 (21.4)	0	0.239
Paravertebral muscle stiffness	9 (64.3)	1 (10.0)	0.013
Longissimus dorsi muscle spasm at palpation	11 (78.6)	0	0.000
Resistance to lateral bending	9 (64.3)	0	0.000
Poor hindlimb impulsion	12 (85.7)	1 (10.0)	0.001
Forelimb lameness	1 (7.1)	0	> 0.999
Hindlimb lameness	3 (21.4)	1 (10.0)	0.615
Bad attitude/aggressive behaviour	2 (14.2)	1 (10.0)	> 0.999
Ill-fitted saddle mark	3 (21.4)	3 (30.0)	0.665

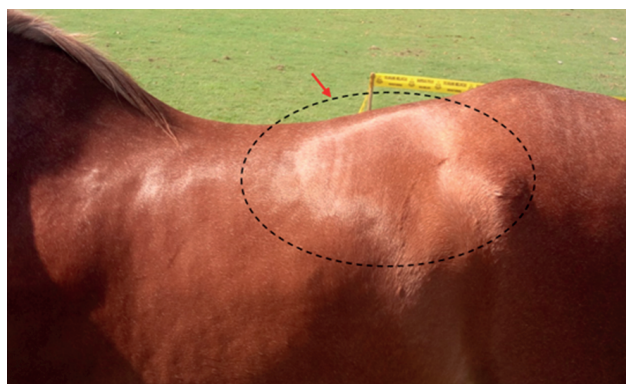
Values are presented as number (%).  
BP, back pain.

### Clinical observations

The clinical findings of horses with and without BP in the study are shown in **Table 2**. All horses with BP showed pain response to digital pressure on the back. Among other most common signs of BP were poor hindlimb impulsion, muscle spasm to palpation, resistance to lateral bending, and back muscle stiffness. Six horses with BP showed poor epaxial muscle development (**Fig. 1**). Other changes/abnormalities observed to be associated with BP the horses include mark of ill-fitted saddle (**Fig. 2**) and swelling on the back (**Fig. 3**).



**Fig. 1.** Poor development of paravertebral muscles in horse with back pain. Note the prominence at the summits of the thoracolumbar spinous processes (arrow).



**Fig. 2.** Mark of ill-fitted and narrow saddle on a horse with back pain.



Fig. 3. Focal swelling (red ring) in a horse with back pain.

### Physical and function abnormalities in grading horses with BP

The severity and frequency of spinal abnormalities in horses with BP are presented in **Table 3**. Horses with BP showed significantly ( $p < 0.05$ ) higher mean overall abnormality score than those of normal horses. All horse with BP showed significant pain response to palpation, muscular hypertonicity, thoracolumbar joint stiffness, and physical dysfunction in comparison with normal horses. Lameness was not a significant finding in horses with BP. However, there was a positive strong correlation between pain response to palpation and the muscular hypertonicity ( $r = 0.9027, p < 0.05$ ), thoracolumbar joint stiffness ( $r = 0.9098, p < 0.05$ ), lameness ( $r = 0.7763, p < 0.05$ ), and physical dysfunction ( $r = 0.9361, p < 0.05$ ) in horses with BP. In general, horses with BP in this study showed mild to moderate physical and function abnormalities. A few horses showed marked pain response to palpation. Based on the cumulative scores of abnormalities horses with BP were categorized into mild, mild-moderate, moderate and severe (**Table 4**).

**Table 3.** Number of horses and frequency of physical and function abnormalities in horses with BP

Abnormalities	BP grade						Overall mean severity	
	Horses with abnormality						Back pain (n = 14)	Normal (n = 10)
	0 (normal)	1 (mild)	2 (mild-moderate)	3 (moderate)	4 (marked)	5 (incapacitated)		
Pain response to palpation	0 (0)	4 (4)	4 (2)	15 (5)	12 (3)	0 (0)	2.50 ± 1.16*	0
Muscular hypertonicity	0 (0)	7 (7)	8 (4)	9 (3)	0 (0)	0 (0)	1.79 ± 0.81*	0.20 ± 0.42
Thoracolumbar joint stiffness	0 (1)	5 (5)	6 (3)	15 (5)	0 (0)	0 (0)	1.79 ± 1.05*	0
Lameness	0 (0)	0 (0)	4 (2)	6 (2)	0 (0)	0 (0)	0.71 ± 1.20	0.20 ± 0.63
Physical dysfunction	0 (4)	6 (6)	4 (2)	3 (1)	4 (1)	0 (0)	1.21 ± 1.19*	0.20 ± 0.42
	Total						8.00 ± 3.57	0.60 ± 1.27

Horses with abnormality are presented as total severity (number of horses). Total severity = Number of horses × BP grade. Overall mean severity are presented mean ± SD. Too few normal animals showed abnormality, thus, score breakdown is not included.

BP, back pain.

\*Means for horses with back pain significantly different from normal horses at  $p < 0.05$ .

**Table 4.** Category of back pain in horses based on cumulative score for abnormalities

Categories	No. (%)	Cumulative score (mean ± SD)
Mild	4 (28.57)	3.25 ± 0.96
Mild-moderate	6 (42.86)	6.83 ± 1.17
Moderate	3 (21.42)	11.33 ± 0.58
Severe	1 (7.14)	14.00 ± 0.00*

\*Value for one horse only.

## DISCUSSION

In horses with BP, assessment of abnormal conditions is only based on observations and clinical findings; thus, it is therefore imperative that clinical abnormalities are clearly identified for the practitioner to accurately assess the clinical conditions to ensure precise management and treatments. Digital palpation and back manipulation are commonly used to determine BP. Though this method is subjective, it is still the most commonly used method in clinical practice to determine BP in horses [9,11]. Other method, like pressure algometry, has also been used in the assessment of BP [12-14]. This method is more objective; however, there are confounding factors, such as individual differences in pain sensation and response that could compromise the accuracy and specificity of BP assessment using the method. Furthermore, pain perception can be influenced by time of day, rate and duration of machine pressure applied, and avoidance responses by the subjects from previous painful experiences [12,15,16]. In horses, the assessment of pain using pressure algometry is also dependent on the ability of the operator to recognize pain response.

In the current study, we classified the severity of BP in horse based on clinical abnormalities: response to palpation, muscular hypertonicity, thoracolumbar joint stiffness, lameness, and physical dysfunctions. Though, there is overlap in the clinical abnormalities observed in both horses with BP and those without BP, this is not surprising considering the that other ailments may show clinical signs similar to BP [17-19]. However, the clinical abnormalities fact observed in BP horses are often associated with thoracolumbar dysfunction. Furthermore, the percentage of occurrence of each clinical feature/abnormality was significantly higher in the horse with BP except for moderate-good epaxial muscle development. These clinical abnormalities include paravertebral muscle stiffness, longissimus dorsi spasm at palpation, poor epaxial muscle development, resistance to lateral bending, and poor hindlimb impulsion [9,11,20].

Using the palpation method, horses with BP showed various degrees of pain response from mild to marked, with mild-moderate response being the most frequent. The variation in pain response to palpation is presumably dependent on the severity of the back disorder. Predisposing factors to equine BP are mostly associated with horse activity, age, use, management, diseases, and disorders. The age and the long duration of physical activities over the active lifespan of the horse could result in degenerative changes of the skeletal structure leading to spinal injury-associated BP [21,22]. Present study showed otherwise with both BP horses and normal horses share similar age, sex, and breed. Therefore, these factors do not predispose horses to BP [1,23].

The movement and stability of the thoracolumbar spine involve spinal epaxial musculature, ligaments, and intervertebral joints [24]. Thus, the muscle hypertonicity and spasm associated BP in this study could be attributed to muscle fatigue, constant weight shifting because of pain and stress, and uncoordinated muscle contraction which may be due to high work demand. The BP horses showed variable muscle hypertonicity ranging from mild to moderate. Similarly, their pain responses to palpation were variable with a few showing marked responses. The reduced intervertebral joint motion and lateral bending is however considered a sequel to prolonged muscle spasm and stiffness of spinal musculature [25,26]. Although, poor musculature can also be due to disuse or neurogenic atrophy, however, the poor development of epaxial muscle observed in this study is a reflection of disuse atrophy of spinal musculature due to reduced muscle activity seen in thoracolumbar pain [23,27,28].

Furthermore, the abnormal gait or reduced hindlimb impulsion seen when the horse is ridden may not necessarily be due to lameness but could be because of weight shifting behaviour displayed by the horse to accommodate for the BP [17]. This is true for BP horses in this study as majority displayed reduced hindlimb impulsion. Nevertheless, forelimb or hindlimb lameness may occur concurrently with BP [29-31]. Since the head is in continuum with the axial skeleton, abnormal gait will affect head motion pattern leading to asymmetrical thoracolumbar kinematics. In such cases, thoracolumbar asymmetry can be corrected by alleviating lameness-induced BP, allowing for increased axial rotation and flexion-extension range of motion, and lateral bending of the spine [32]. Very few horses showed signs of lameness in this study, which led to the conclusion that lameness may not be a significant cause of equine BP.

Among causes of equine BP are conformational abnormalities and degree of back mobility [33]. Conformation abnormalities, for example in the thoracolumbar region, predispose the horse to weakness, soft tissue injury, leading to poor performance may not necessarily be associated with BP, if motion is not affected [34]. Incidentally, the horses in this study did not show any conformation abnormality.

Using the clinical abnormalities, it is possible to grade thoracolumbar pain based a scale of 1 to 5. Horses with BP had significantly higher scores than those without for all parameters except lameness. Horses with BP responded painfully to back palpation that ranged from mild to marked response. The variability in pain response is presumably dependent on the severity of the back disorder. Thoracolumbar joint stiffness and muscular hypertonicity, to a lesser extent, were also significant in horses with BP. Furthermore, there was a strong significant correlation between the degree of pain response, muscular hypertonicity, thoracolumbar joint stiffness, lameness, and physical dysfunction. According to this method of assessment, it is proposed that pain response, muscular hypertonicity, and thoracolumbar joint stiffness can reliably be used to grade the severity of equine BP.

In this study, based on BP-associated parameters, the horses showed different degrees of severity in abnormalities. The reason for the variation in abnormalities in equine BP may be associated with duration of the BP and individual horse tolerances. Some experienced athletic horses with BP may mask their pain by compensation and still perform adequately, while those sensitive to BP resist work [25,35]. It is important to note that because of differences in temperament, the relationship between clinical features or abnormalities and the true perceived pain behaviours may not be as straightforward in horses as in other animals and humans [36,37]. Even in normal horses, response to digital palpation or pressure along the back region can vary, since some horses, known as “cold-backs,” are very sensitive to touch and react abnormally.

Using the cumulative scores of abnormalities, this study showed that horses with BP could be classified according to severity. In order of frequency, the horses suffered from mild-moderate, mild, moderate, and severe BP (**Table 4**). Since muscular hypertonicity, thoracolumbar joint stiffness, physical dysfunction impact performance, the grading system could be used as a measure of response to treatment and recovery to full function.

In conclusion, the study shows that among clinical abnormalities, pain response to back palpation, back muscle hypertonicity, thoracolumbar joint stiffness, and physical dysfunctions are useful in determining BP in horses. Noticeably, BP in horse can be

differentiated by severity of presentation of these clinical abnormalities. Despite the small sample size of the horses in this study, the data showed that cumulative grading score of abnormalities is useful in the assessment and categorization of BP in horses.

## ACKNOWLEDGMENTS

We deeply acknowledge the resident veterinarian's at large animal clinics, University Veterinary Hospital-Universiti Putra Malaysia (UVH-UPM) for their assistant and horse owners for consent to use their horses.

## REFERENCES

1. Jeffcott LB. Disorders of the thoracolumbar spine of the horse--a survey of 443 cases. *Equine Vet J*. 1980;12(4):197-210.  
[PUBMED](#) | [CROSSREF](#)
2. Gillis C. Spinal ligament pathology. *Vet Clin North Am Equine Pract*. 1999;15(1):97-101.  
[PUBMED](#) | [CROSSREF](#)
3. Henson FM, Lamas L, Knezevic S, Jeffcott LB. Ultrasonographic evaluation of the supraspinous ligament in a series of ridden and unridden horses and horses with unrelated back pathology. *BMC Vet Res*. 2007;3:3.  
[PUBMED](#) | [CROSSREF](#)
4. Mayaki AM, Intan-Shameha AR, Noraniza MA, Mazlina M, Adamu L, Abdullah R. Clinical investigation of back disorders in horses: a retrospective study (2002-2017). *Vet World*. 2019;12(3):377-381.  
[PUBMED](#) | [CROSSREF](#)
5. Dyson S, Berger JM, Ellis AD, Mullard J. Behavioral observations and comparisons of nonlame horses and lame horses before and after resolution of lameness by diagnostic analgesia. *J Vet Behav*. 2018;26:64-70.  
[CROSSREF](#)
6. Landman MA, de Blaauw JA, van Weeren PR, Hofland LJ. Field study of the prevalence of lameness in horses with back problems. *Vet Rec*. 2004;155(6):165-168.  
[PUBMED](#) | [CROSSREF](#)
7. Mohammed HO, Divers TJ, Summers BA, de Lahunta A. Vitamin E deficiency and risk of equine motor neuron disease. *Acta Vet Scand*. 2007;49(1):17.  
[PUBMED](#) | [CROSSREF](#)
8. Weber Polack E, King JM, Cummings JF, de Lahunta A, Divers TJ, Mohammed HO. Quantitative assessment of motor neuron loss in equine motor neuron disease (EMND). *Equine Vet J*. 1998;30(3):256-259.  
[PUBMED](#) | [CROSSREF](#)
9. Riccio B, Frascchetto C, Villanueva J, Cantatore F, Bertuglia A. Two multicenter surveys on equine back-pain 10 years a part. *Front Vet Sci*. 2018;5:195.  
[PUBMED](#) | [CROSSREF](#)
10. American Association of Equine Practitioners (AAEP) Horse Show Committee. *Guide to Veterinary Services for Horses Shows*. 7th ed. Lexington: American Association of Equine Practitioners; 1999.
11. Cauin E. Assessment of back pain in horses. *In Pract*. 1997;19:522-533.  
[PUBMED](#) | [CROSSREF](#)
12. de Heus P, van Oossanen G, van Dierendonck MC, Back W. A pressure algometer is a useful tool to objectively monitor the effect of diagnostic palpation by a physiotherapist in Warmblood horses. *J Equine Vet Sci*. 2010;30(6):310-321.  
[CROSSREF](#)
13. Haussler KK, Erb HN. Pressure algometry for the detection of induced back pain in horses: a preliminary study. *Equine Vet J*. 2006;38(1):76-81.  
[PUBMED](#) | [CROSSREF](#)
14. Lane DM, Hill SA. Pressure algometry measurement of canine muscular pain near the thoracolumbar junction: evaluation of a modified technique. *Vet Anaesth Analg*. 2016;43(2):227-234.  
[PUBMED](#) | [CROSSREF](#)



15. Grint NJ, Beths T, Yvorchuk K, Taylor PM, Dixon M, Whay HR, et al. The influence of various confounding factors on mechanical nociceptive thresholds in the donkey. *Vet Anaesth Analg*. 2014;41(4):421-429.  
[PUBMED](#) | [CROSSREF](#)
16. Pongratz U, Licka T. Algometry to measure pain threshold in the horse's back - An *in vivo* and *in vitro* study. *BMC Vet Res*. 2017;13(1):80.  
[PUBMED](#) | [CROSSREF](#)
17. Dyson S, Murray R. Pain associated with the sacroiliac joint region: a clinical study of 74 horses. *Equine Vet J*. 2003;35(3):240-245.  
[PUBMED](#) | [CROSSREF](#)
18. Lesimple C, Fureix C, Biquand V, Hausberger M. Comparison of clinical examinations of back disorders and humans' evaluation of back pain in riding school horses. *BMC Vet Res*. 2013;9:209.  
[PUBMED](#) | [CROSSREF](#)
19. Martin BB Jr, Klide AM. Physical examination of horses with back pain. *Vet Clin North Am Equine Pract*. 1999;15(1):61-70.  
[PUBMED](#) | [CROSSREF](#)
20. Sardari K. Back pain: a significant cause of poor performance in show jumping horses (diagnostic challenge and treatment). *Iran J Vet Surg*. 2008;5(2):163-169.
21. Bergmann W, Bergknut N, Veraa S, Gröne A, Vernooij H, Wijnberg ID, et al. Intervertebral disc degeneration in Warmblood horses: morphology, grading, and distribution of lesions. *Vet Pathol*. 2018;55(3):442-452.  
[PUBMED](#) | [CROSSREF](#)
22. Veraa S, Bergmann W, Wijnberg ID, Back W, Vernooij H, Nielen M, et al. Equine cervical intervertebral disc degeneration is associated with location and MRI features. *Vet Radiol Ultrasound*. 2019;60(6):696-706.  
[PUBMED](#) | [CROSSREF](#)
23. Cousty M, Retureau C, Tricaud C, Geffroy O, Caure S. Location of radiological lesions of the thoracolumbar column in French trotters with and without signs of back pain. *Vet Rec*. 2010;166(2):41-45.  
[PUBMED](#) | [CROSSREF](#)
24. Hyytiäinen HK, Mykkänen AK, Hielm-Björkman AK, Stubbs NC, McGowan CM. Muscle fibre type distribution of the thoracolumbar and hindlimb regions of horses: relating fibre type and functional role. *Acta Vet Scand*. 2014;56(1):8.  
[PUBMED](#) | [CROSSREF](#)
25. Barstow A, Dyson S. Clinical features and diagnosis of sacroiliac joint region pain in 296 horses: 2004-2014. *Equine Vet Educ*. 2015;27(12):637-647.  
[CROSSREF](#)
26. Knutson GA, Owens EF. Active and passive characteristics of muscle tone and their relationship to models of subluxation/joint dysfunction: Part I. *J Can Chiropr Assoc*. 2003;47(3):168-179.
27. Licka T, Frey A, Peham C. Electromyographic activity of the longissimus dorsi muscles in horses when walking on a treadmill. *Vet J*. 2009;180(1):71-76.  
[PUBMED](#) | [CROSSREF](#)
28. Stubbs NC, Riggs CM, Hodges PW, Jeffcott LB, Hodgson DR, Clayton HM, et al. Osseous spinal pathology and epaxial muscle ultrasonography in Thoroughbred racehorses. *Equine Vet J Suppl*. 2010;(38):654-661.  
[PUBMED](#) | [CROSSREF](#)
29. Girodroux M, Dyson S, Murray R. Osteoarthritis of the thoracolumbar synovial intervertebral articulations: clinical and radiographic features in 77 horses with poor performance and back pain. *Equine Vet J*. 2009;41(2):130-138.  
[PUBMED](#) | [CROSSREF](#)
30. Meehan L, Dyson S, Murray R. Radiographic and scintigraphic evaluation of spondylosis in the equine thoracolumbar spine: a retrospective study. *Equine Vet J*. 2009;41(8):800-807.  
[PUBMED](#) | [CROSSREF](#)
31. Zimmerman M, Dyson S, Murray R. Comparison of radiographic and scintigraphic findings of the spinous processes in the equine thoracolumbar region. *Vet Radiol Ultrasound*. 2011;52(6):661-671.  
[PUBMED](#) | [CROSSREF](#)
32. Greve L, Dyson S, Pfau T. Alterations in thoracolumbosacral movement when pain causing lameness has been improved by diagnostic analgesia. *Vet J*. 2017;224:55-63.  
[PUBMED](#) | [CROSSREF](#)
33. Johnston C, Holmt K, Faber M, Erichsen C, Eksell P, Drevemo S. Effect of conformational aspects on the movement of the equine back. *Equine Vet J Suppl*. 2002;(34):314-318.  
[PUBMED](#) | [CROSSREF](#)

34. Kleinstück F, Dvorak J, Mannion AF. Are “structural abnormalities” on magnetic resonance imaging a contraindication to the successful conservative treatment of chronic nonspecific low back pain? *Spine*. 2006;31(19):2250-2257.  
[PUBMED](#) | [CROSSREF](#)
35. Lesimple C, Fureix C, De Margerie E, Sénèque E, Menguy H, Hausberger M. Towards a postural indicator of back pain in horses (*Equus caballus*). *PLoS One*. 2012;7(9):e44604.  
[PUBMED](#) | [CROSSREF](#)
36. Ellis AD, Stephenson M, Preece M, Harris P. A novel approach to systematically compare behavioural patterns between and within groups of horses. *Appl Anim Behav Sci*. 2014;161:60-74.  
[CROSSREF](#)
37. Hall C, Heleski C. The role of the ethogram in equitation science. *Appl Anim Behav Sci*. 2017;190:102-110.  
[CROSSREF](#)