

Argon Plasma Coagulation for Extraction of an Impacted Trapezoid Basket in the Pancreatic Duct

Treta Purohit, MBBS, MPH¹, Mrinal Garg, MD², Abhijit Kulkarni, MD, FASGE², and Shyam Thakkar, MD²

¹Division of Gastroenterology, Beaumont Health System and Oakland University School of Medicine, Royal Oak, MI

²Division of Gastroenterology, Allegheny Health Network, Pittsburgh, PA

Abstract

We performed endoscopic retrograde cholangiopancreatography (ERCP) with sphincterotomy for pancreatic stent placement on a 55-year-old woman with a dilated pancreatic duct, pancreatic duct stone, and chronic pancreatitis. During follow-up ERCP, the lithotripter traction wire fractured during electrohydraulic lithotripsy and mechanical lithotripsy. Multiple attempts using standard techniques to clear the lithotripter and stone failed. Argon plasma coagulation (APC) was used to ablate 2 of the lithotripter wires, and the lithotripter was disengaged from the stone and removed.

Introduction

Fracture of traction wires during endoscopic treatment of stones is a known but rare complication of mechanical lithotripsy.¹ There are no reported cases describing successful endoscopic retrieval of lithotripter baskets from fractured traction wires using argon plasma coagulation (APC). APC involves non-contact electrocoagulation where an electric current is applied to tissue using ionized argon gas.² The plasma beam follows the path of least resistance and helps treat regions that are difficult to access to allow tissue necrosis with minimal risk of perforation.³

Case Report

A 55-year-old African American woman presented with chronic epigastric and right upper quadrant abdominal pain. The pain was sharp, radiated to her back, associated with nausea, and aggravated with intake of fatty foods. Her history was significant for alcohol abuse that had ceased 2 years prior to presentation. Imaging studies showed a dilated pancreatic duct (PD) with a 10-mm stone and changes suggestive of chronic pancreatitis (Figure 1). Endoscopic ultrasound revealed no underlying mass lesion. Abdominal pain was successfully treated initially with endoscopic retrograde cholangiopancreatography (ERCP), biliary and pancreatic duct sphincterotomy, and placement of a pancreatic stent (Cook Medical, Bloomington, IN). At follow-up ERCP, direct visualization pancreatoscopy was performed using a 10 French x 250 cm cholangioscope (Boston Scientific, Marlborough, MA). After electrohydraulic lithotripsy, multiple stone fragments were extracted with balloon and trapezoid baskets (Boston Scientific, Marlborough, MA; Figure 2), but an 8-mm stone fragment remained. A mechanical lithotripter was inserted to remove the stone fragment; however, the complex could not be extracted and the lithotripter basket wires could not be disengaged from the stone. During attempts at removal, the lithotripter traction wire fractured and the stone–lithotripter complex remained impacted (Figure 3).

Multiple techniques were used in an attempt to clear the lithotripter and stone from the pancreatic duct, including the use of an out-of-the-scope (OOS) lithotripter (Olympus, Center Valley, PA). This was unsuccessful, as the traction wire fractured a second time. Further techniques—including dilation of the ampullary orifice, extension of

ACG Case Rep J 2015;2(3):139-141. doi:10.14309/crj.2015.34. Published online: April 10, 2015.

Correspondence: Shyam Thakkar, 1307 Federal Street, Ste 301, Pittsburgh, PA 15212 (sthakkar@wpahs.org).



Copyright: © 2015 Purohit et al. This work is licensed under a Creative Commons Attribution-NonCommercial-NoDerivatives 4.0 International License. To view a copy of this license, visit <http://creativecommons.org/licenses/by-nc-nd/4.0>.

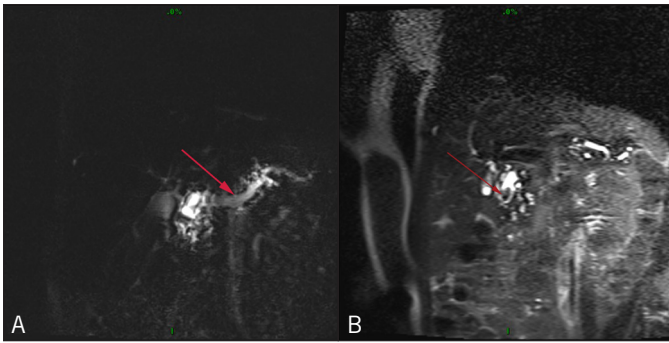


Figure 1. Abdominal MRI showing (A) dilated pancreatic duct downstream from pancreatic stone, and (B) a stone in the pancreatic duct.

pancreatic sphincterotomy, and repeated attempts at balloon extraction of the stone and basket—were unsuccessful due to changes secondary to chronic pancreatitis. Using rat tooth forceps (Olympus, Center Valley, PA), a portion of the basket was successfully everted in the duodenal lumen; however, the basket remained engaged within the duct with the stone.

APC (ERBE USA, Maritta, GA) at 60 watts and 2 L/min was used to successfully ablate 2 of the lithotripter wires, and the lithotripter was successfully disengaged from the stone and removed (Figure 4). No basket wires or basket fragments remained (Figure 5). The large stone fragment remained. An attempt was made to place a pancreatic duct stent prior to completion of the exam for post-ERCP pancreatitis prophylaxis; however, due to the severity of swelling, pancreas duct stent placement could not be achieved. Her post-procedure stay was complicated by mild acute pancreatitis that was managed conservatively. ERCP 3 weeks later showed the larger stone fragment was no longer present, consistent with spontaneous passage between exams. Small residual 2–3-mm stone fragments were extracted with a 9–12 mm balloon.

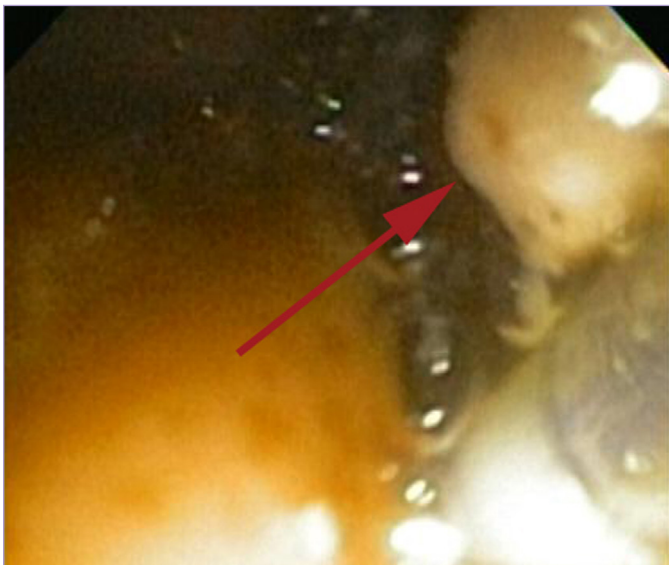

Figure 2. Endoscopic removal of pancreatic stone fragments.

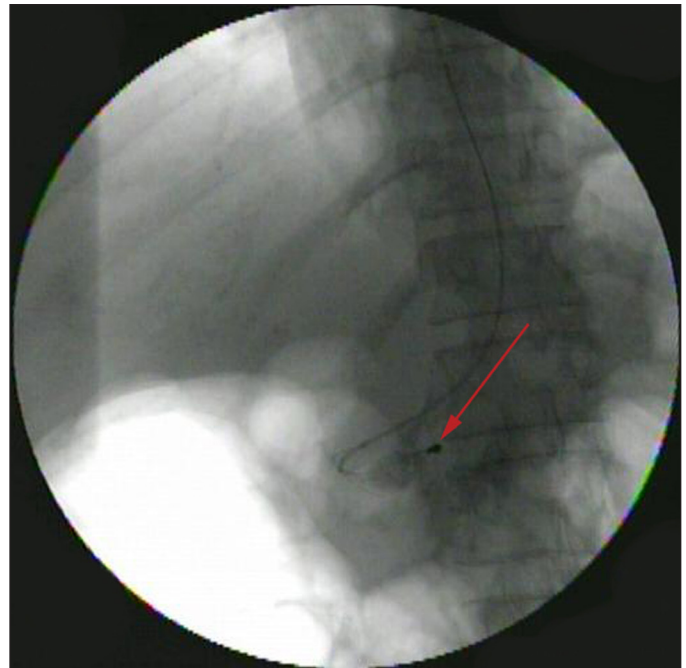


Figure 3. Fluoroscopic image of the retained lithotripsy basket impaction.

At 6-month follow-up, the patient remained free of symptoms.

Discussion

The various methods available for treatment of resistant pancreatic duct stones include endoscopic treatment with a combination of 1 or more of the following techniques: sphincterotomy, sphincteroplasty, stone extraction, extracorporeal shock-wave lithotripsy,^{4,5} laser lithotripsy,⁶ mechanical lithotripsy,^{1,7} electrohydraulic lithotripsy,⁸ and placement of pancreatic duct stents.⁹ Our patient’s treatment was staged with interval pancreatic stenting in combination with sphinc-




Figure 4. Close view of lithotripsy basket following argon plasma coagulation showing failed deployment of the safety cap.

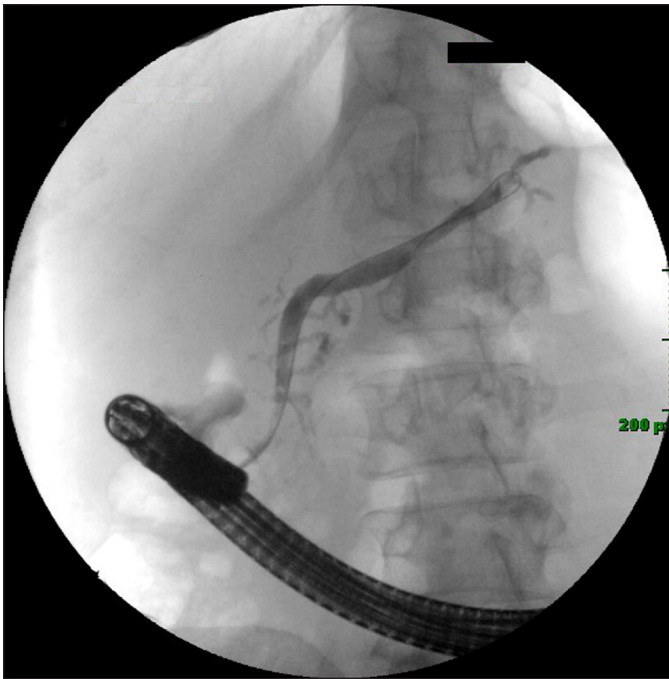

Figure 5. Cleared pancreatic duct after stone and lithotripter removal.

terotomy, electrohydraulic lithotripsy, mechanical lithotripsy, and stone extraction.

Equipment malfunction, safety, and breaking point strengths of the mechanical lithotripters should be considered. In our case, we used a lithotripter with a designed failure point at its tip to prevent entrapment onto the stone. Despite its design, the traction wire fractured, and the safety mechanism did not deploy (Figure 4). Laser lithotripsy for impacted baskets has been described in the literature; however, it has limited availability in most centers.¹⁰ The rationale for APC in this setting was based on reported use of APC for trimming uncovered metallic stents.¹¹⁻¹³ Based on these studies in which APC settings ranged from 60 to 85 watts and from 0.8 to 1.8 L/min flow, the generator was set at the lowest wattage and flow was titrated to successful ablation. Most of these stents are made of an alloy of titanium and nickel known as nitinol, with melting points between 1200°C and 1300°C, which are temperatures that can be generated by the argon beam. Most trapezoid baskets are also made of nitinol or stainless steel,¹⁴ so we attempted ablation of the lithotripter wires with APC after other maneuvers failed. The successful management establishes a unique use of APC in endoscopy.

Disclosures

Author contributions: All authors contributed equally to the creation of the manuscript. S. Thakkar is the article guarantor.

Financial disclosure: None to report.

Informed consent was obtained for this case report.

Received: November 13, 2014; Accepted: February 10, 2015

References

1. Thomas M, Howell DA, Carr-Locke D, et al. Mechanical lithotripsy of pancreatic and biliary stones: Complications and available treatment options collected from expert centers. *Am J Gastroenterol.* 2007;102(9):1896-1902.
2. Grund KE, Storek D, Farin G. Endoscopic argon plasma coagulation (APC): First clinical experiences in flexible endoscopy. *Endosc Surg Allied Technol.* 1994;2(1):42-46.
3. Johanns W, Jakobeit C, Luis W, Greiner L. Non-contact argon gas coagulation in flexible endoscopy of the gastrointestinal tract: In vitro studies and initial clinical experiences [Article in German]. *Z Gastroenterol.* 1995;33(12):694-700.
4. Delhaye M, Vandermeeren A, Baize M, Cremer M. Extracorporeal shock-wave lithotripsy of pancreatic calculi. *Gastroenterology.* 1992;102(2):610-620.
5. Costamagna G, Gabbriellini A, Mutignani M, et al. Extracorporeal shock wave lithotripsy of pancreatic stones in chronic pancreatitis: Immediate and medium-term results. *Gastrointest Endosc.* 1997;46(3):231-236.
6. Neuhaus H, Hoffmann W, Classen M. Laser lithotripsy of pancreatic and biliary stones via 3.4 mm and 3.7 mm miniscopes: First clinical results. *Endoscopy.* 1992;24(3):208-214.
7. Freeman ML. Mechanical lithotripsy of pancreatic duct stones. *Gastrointest Endosc.* 1996;44(3):333-336.
8. Howell DA, Dy RM, Hanson BL, et al. Endoscopic treatment of pancreatic duct stones using a 10F pancreatoscope and electrohydraulic lithotripsy. *Gastrointest Endosc.* 1999;50(6):829-833.
9. Sasahira N, Tada M, Isayama H, et al. Outcomes after clearance of pancreatic stones with or without pancreatic stenting. *J Gastroenterol.* 2007;42(1):63-69.
10. Neuhaus H, Hoffmann W, Classen M. Endoscopic laser lithotripsy with an automatic stone recognition system for basket impaction in the common bile duct. *Endoscopy.* 1992;24(6):596-599.
11. Demarquay R, Dumas R, Peten EP, Rampal P. Argon plasma endoscopic section of biliary metallic prostheses. *Endoscopy.* 2001;33(3):289-290.
12. Vanbiervliet G, Piche T, Caroli-Bosc FX, et al. Endoscopic argon plasma trimming of biliary and gastrointestinal metallic stents. *Endoscopy.* 2005;37(5):434-438.
13. Christiaens P, Decock S, Buchel O, et al. Endoscopic trimming of metallic stents with the use of argon plasma. *Gastrointest Endosc.* 2008;67(2):369-371.
14. Adler DG, Conway JD, Farraye FA, et al; ASGE Technology Committee. Biliary and pancreatic stone extraction devices. *Gastrointest Endosc.* 2009;70(4):603-609.

Publish your work in ACG Case Reports Journal

ACG Case Reports Journal is a peer-reviewed, open-access publication that provides GI fellows, private practice clinicians, and other members of the health care team an opportunity to share interesting case reports with their peers and with leaders in the field. Visit <http://acgcasereports.gi.org> for submission guidelines. Submit your manuscript online at <http://mc.manuscriptcentral.com/acgcr>.