



CASE REPORT

Endovascular treatment of chronic mesenteric ischemia in an adolescent male: case report [v1; ref status: indexed, <http://f1000r.es/2gm>]

Sadiq Muhammed Al-Hammash, Abd El-Salam Dawood Al-Ethawi, Kasim Abbas Ismail

Ibn Al-Bittar Center for Cardiac Surgery, College of Medicine, Al-Mustansiriyah University, Baghdad, Iraq

v1 First published: 17 Dec 2013, 2:277 (doi: [10.12688/f1000research.2-277.v1](https://doi.org/10.12688/f1000research.2-277.v1))
Latest published: 17 Dec 2013, 2:277 (doi: [10.12688/f1000research.2-277.v1](https://doi.org/10.12688/f1000research.2-277.v1))

Abstract

Chronic mesenteric ischemia (CMI) is a condition characterized by inadequate blood flow to the bowel resulting from stenosis of one or more of the three mesenteric arteries. Fibromuscular dysplasia is the most common cause in children and young adults; whereas atherosclerosis is the most common cause in the elderly. Treatment is mandatory in symptomatic patients, because it may lead to malnutrition, bowel infarction or even death. Herein, we present the case of a 14-year old male, diagnosed with CMI who underwent percutaneous balloon angioplasty (PTA) followed by stent placement with immediate positive results.

Article Status Summary

Referee Responses

Referees	1	2
v1 published 17 Dec 2013	 report 1	 report

- Madathipat Unnikrishnan**, Sree Chitra Thirunal Institute of Medical Sciences and Technology India
- Lefeng Qu**, Shanghai Hospital, Second Military Medical University China

Latest Comments

No Comments Yet

Corresponding author: Abd El-Salam Dawood Al-Ethawi (dr.ethawi@gmail.com)

How to cite this article: Al-Hammash SM, Al-Ethawi AESD and Ismail KA (2013) **Endovascular treatment of chronic mesenteric ischemia in an adolescent male: case report [v1; ref status: indexed, <http://f1000r.es/2gm>]** *F1000Research* 2013, 2:277 (doi: [10.12688/f1000research.2-277.v1](https://doi.org/10.12688/f1000research.2-277.v1))

Copyright: © 2013 Al-Hammash SM *et al.* This is an open access article distributed under the terms of the [Creative Commons Attribution Licence](#), which permits unrestricted use, distribution, and reproduction in any medium, provided the original work is properly cited. Data associated with the article are available under the terms of the [Creative Commons Zero "No rights reserved" data waiver](#) (CC0 1.0 Public domain dedication).

Grant information: The author(s) declared that no grants were involved in supporting this work.

Competing interests: No competing interests were disclosed.

First published: 17 Dec 2013, 2:277 (doi: [10.12688/f1000research.2-277.v1](https://doi.org/10.12688/f1000research.2-277.v1))

First indexed: 13 May 2014, 2:277 (doi: [10.12688/f1000research.2-277.v1](https://doi.org/10.12688/f1000research.2-277.v1))

Introduction

Chronic mesenteric ischemia (CMI) is a condition characterized by inadequate blood flow to the bowel resulting from stenosis of one or more of the three mesenteric arteries: the celiac artery (CA), the superior mesenteric artery (SMA), and the inferior mesenteric artery (IMA). Many case-series include patients with ischemic bowel due to stenosis of a single artery¹⁻³.

Fibromuscular dysplasia (FMD) is a rare disorder of medium-sized arteries with no signs of inflammation or atherosclerosis⁴. It is the most common cause of stenosis in children and young adults. The reported worldwide incidence is around 1%⁵.

Renal arteries (60–75%) and cerebral arteries (25–30%) are the most commonly involved vasculatures; followed by the mesenteric, iliac, and subclavian arteries⁵.

In those older than 60 years atherosclerotic plaques are the most common cause of stenosis of the mesenteric arteries, with females affected three times more often than males⁶.

Symptomatic untreated bowel ischemia may cause malnutrition or acute bowel ischemia with infarction –a complication that is associated with a bad prognosis⁶. A fatal outcome has been reported in some cases⁷. Therefore, treatment is mandatory in symptomatic cases.

The gold standard therapeutic option is surgical (either a bypass or endarterectomy) with a combined morbidity of 15–47% and a mortality of 0–17%⁸⁻¹². Stenoses of the mesenteric vessels are focal, and found at the ostium or proximal part of the artery – two features that make them accessible to transluminal therapy. Endovascular treatment of bowel ischemia was first described in 1980¹³ and subsequently good results were found in two small studies^{14,15}. Encouraged by these results, several centers, including ours, started using transluminal angioplastic techniques as the first line therapy for mesenteric ischemia.

Herein, we present the case of a 14-year old Arabic Muslim male from the center of Iraq who was diagnosed with chronic mesenteric ischemia and who underwent a percutaneous balloon angioplasty (PTA) followed by stent placement with immediate positive results.

Case report

The condition started in infancy when the child had recurrent attacks of respiratory tract infections and exhibited a failure to thrive. He was diagnosed at that time as a case of moderate-sized patent ductus arteriosus (PDA) and small restrictive perimembranous ventricular septal defect (VSD). The patient had been prescribed anti-heart failure medications (in the form of digoxin oral drops (10 mcg/kg/day in two divided doses, furosemide 1 mg/kg bid by mouth (PO), and captopril 0.5 mg/kg by mouth per day (QD PO)) and the patient had frequent follow-up visits. His PDA had been closed via a transcatheter approach using an Amplatzer® ductal occluder device at the age of 8 months and the VSD closed spontaneously as suggested by clinical follow-up exams and confirmed by echocardiography. The child's medication was stopped at the age of 2 years and he was thriving well.

One year ago (at the age of 13), the patient started to develop postprandial nausea and abdominal pain necessitating a complete work-up including investigations to exclude peptic ulcer disease (PUD) as a cause of these symptoms.

The patient was referred back to our center by his pediatrician to exclude any complicating event associated with his ex-PDA and VSD. An initial clinical examination was unremarkable. A screening echocardiography was performed that showed turbulence in the abdominal aorta near the origin of the celiac artery (CA), which raised the possibility of chronic mesenteric ischemia as the cause of his symptoms.

Catheterization was done and a 6 F short sheath inserted in the right femoral artery. A non-selective abdominal aortography followed by selective angiography using a 6 F Judkins Right® (JR) catheter confirmed the presence of a narrowing at the ostial and proximal segments of the celiac artery. The length of the narrowed segment, the diameter of the stenosed segment and the nearby normal segment were measured, expert consultation was done, and the patient was scheduled for subsequent therapeutic catheterization including percutaneous balloon angioplasty (PTA) with or without stent placement (Figure 1A).

Six weeks later (after being prepared with aspirin 100 mg QD PO for seven days and clopidogrel 75 mg QD PO for three days, a 6 F short sheath introducer was inserted in the right femoral artery and another 6 F hydrophilic short sheath introducer was inserted in the right radial artery after confirming palmar arch patency using modified Allen's test¹⁶ and skin infiltration with 1.5 ml lidocaine as a local anaesthetic. Heparin 5000 IU was given intravenously immediately after inserting the radial sheath and 200 mcg nitroglycerine was administered via the sheath. The femoral sheath was used for monitoring, and non-selective angiography (for proper localization of the balloon), while the radial sheath was used to deliver the balloon (with or without the stent) into the celiac artery. A 6 French guiding catheter was passed over a 0.030" exchange guide wire (GW) reaching up to the ostium of the CA from the radial artery. It was then replaced with a 0.014" soft-tipped GW, which was passed a few centimeters within the CA. A 4 mm diameter percutaneous coronary angioplasty (PTCA) balloon was passed over the 0.014' GW and dilatation of the ostial and proximal segment of the CA was done (reaching nominal pressure and kept inflated for 30 seconds) (Figure 1B and C). A residual stenosis of about 40% was noticed after the balloon angioplasty, necessitating the use of a Promus® drug-eluting stent (PROMUS Element™ Plus; Everolimus-Eluting Platinum Chromium Coronary Stent System), premounted on a balloon, measuring 4 mm in diameter and 12 mm in length. The balloon was inflated just-below burst pressure and kept inflated for 30 seconds. An angiography conducted after this procedure, showed a diameter equal to the nearby normal segment (Figure 1D).

The radial artery sheath was removed immediately after completing the procedure and hemostasis was secured using a TR band® (compression strap) and a femoral artery sheath, removed after 60 minutes.

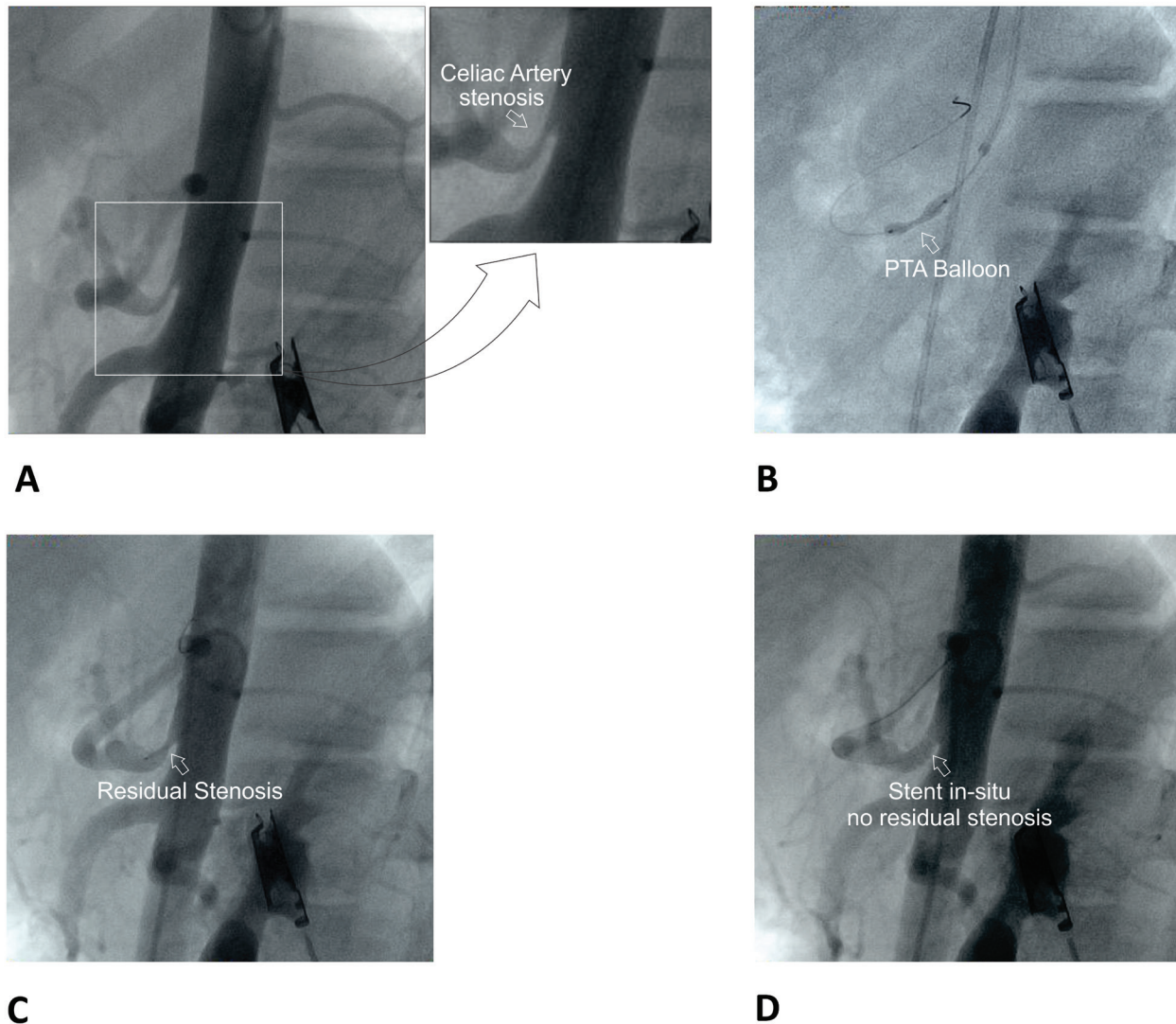


Figure 1. Percutaneous balloon angioplasty with stent placement for celiac artery stenosis. **A.** Non-selective angiography (lateral view) showing ostial and proximal segment stenosis of the celiac artery. (The inset shows a close-up view of the stenosis; arrow). **B.** PTA balloon inflated showing "waist" formation (arrow). **C.** Residual stenosis (arrow) after initial PTA. **D.** Stent *in-situ* with no residual stenosis (arrow).

There were no immediate post-operative complications. The patient was discharged on the second day after the operation and was instructed to take both aspirin 100 mg/day QD PO and clopidogrel 75 mg/day QD PO for the following six months followed by use of aspirin alone for life. In the subsequent follow-up visits conducted one- and six-months after the procedure, there was neither post-prandial abdominal pain, nor nausea and the patient gained 7 kilograms weight over 6 months.

Discussion

Untreated chronic mesenteric ischemia (CMI) can lead to symptoms of post-prandial abdominal pain, malnutrition, or even death. Therefore, a symptomatic patient needs treatment. The conventional treatment is surgical via a bypass surgery with or without endarterectomy⁶. Transluminal endovascular intervention, first described

in 1980¹³ and the good results obtained by two small studies encouraged many centers- including ours- to adopt the endovascular treatment as the first line therapy.

The aims of therapy are to: 1) achieve symptomatic resolution, 2) prevent bowel infarction and resultant morbidity and mortality and 3) prevent and treat malnutrition. Some groups also recommend prophylactic revascularization even in asymptomatic patients who are due for an operation in the aorta (e.g. aneurysm, coarctation, etc.) or before being scheduled for major abdominal surgery that might jeopardize the collateral circulation⁶.

The patient had a moderate-sized PDA and small restrictive VSD diagnosed in infancy. The former was closed by a transcatheter approach and the latter closed spontaneously. Up to the time of

writing this article, the authors were unable to find a study showing an association between these two defects and mesenteric ischemia due to celiac artery stenosis. As such these findings appear coincidental.

Two catheterization sessions were needed in our patient because expert consultation and support was needed. However, if the patient is well-prepared in terms of antiplatelet medications (seven days of aspirin and three days of clopidogrel in our center); equipment and expert consultation is available, one catheterization session might suffice for confirming the diagnosis, planning, measuring and proceeding with angioplasty with or without stent placement.

Since the initial PTA result was unsatisfactory with 40% residual stenosis, a drug-eluting covered stent (PROMUS Element™ Plus; Everolimus-Eluting Platinum Chromium Coronary Stent System) with a length ensuring 1 mm protrusion in the aortic lumen and 1–2 mm coverage of the nearby normal-width segment was inserted. The diameter chosen depends on the diameter of the nearby normal segment (we added 1 mm to the diameter of the normal segment).

Some centers also recommend using stents in the following situations: 1) lesions located at the ostium or eccentric lesions, 2) History of dissection after a previous angioplasty and 3) Chronic stenosis¹⁷.

Since the take-off of the celiac artery has an acute angle to the aortic wall, the superior approach (i.e. radial) provides a smoother curve and easier access of this artery. For that reason we chose the right radial artery after using a modified Allen test¹⁶ to confirm patency of the palmar arch.

The use of vasodilators (nitroglycerine) given in the sheath is necessary to prevent radial artery vasospasm.

Conclusion

Symptomatic CIM can be found in the pediatric age group. We contribute this case report to the growing body of information regarding the role and effectiveness of endovascular treatment of this condition. Further research is needed to elucidate the “long-term” efficacy and safety of this therapeutic option.

Consent

Written informed consent for publication of clinical details was obtained from the patient’s parents.

Author contributions

Sadiq, Abd El-Salam, and Kasim conceived the study. Sadiq prepared the patient for the procedure in addition to Kamal and Amer. Sadiq and Abd El-Salam conducted the procedure and Kasim monitored its technical aspects. Abd El-Salam wrote the first draft of the manuscript. All authors had been involved in revising the manuscript and agreed to its final contents.

Competing interests

No competing interests were disclosed.

Grant information

The author(s) declared that no grants were involved in supporting this work.

Acknowledgements

The authors acknowledge Dr. Kamal Ali and Dr. Amer Na’aes for their medical care for the patient pre- and postoperatively and for technical support in preparing the images displayed in this article.

References

- Sharafuddin MJ, Olson CH, Sun S, *et al.*: **Endovascular treatment of celiac and mesenteric arteries stenoses: application and results.** *J Vasc Surg.* 2003; **38**(4): 692–8.
[PubMed Abstract](#) | [Publisher Full Text](#)
- Maspeles F, Mazzetti di Pietralata G, Gandini R, *et al.*: **Percutaneous transluminal angioplasty in the treatment of chronic mesenteric ischemia: results and 3 years of follow-up in 23 patients.** *Abdom Imaging* 1998; **23**(4): 358–63.
[PubMed Abstract](#) | [Publisher Full Text](#)
- Steinmetz E, Tatou E, Favier-Blavoux C, *et al.*: **Endovascular treatment as first choice in chronic intestinal ischemia.** *Ann Vasc Surg.* 2002; **16**(6): 693–9.
[PubMed Abstract](#) | [Publisher Full Text](#)
- Harrison EG Jr, McCormack LJ: **Pathologic classification of renal arterial disease in renovascular hypertension.** *Mayo Clin Proc.* 1971; **46**(3): 161–7.
[PubMed Abstract](#)
- Slovut DP, Olin JW: **Fibromuscular dysplasia.** *N Engl J Med.* 2004; **350**(18): 1862–71.
[PubMed Abstract](#) | [Publisher Full Text](#)
- Loffroy R, Steinmetz E, Guiu B, *et al.*: **Role of endovascular therapy in chronic mesenteric ischemia.** *Can J Gastroenterol.* 2009; **23**(5): 365–73.
[PubMed Abstract](#) | [Free Full Text](#)
- Guill CK, Benavides DC, Rees C, *et al.*: **Fatal mesenteric fibromuscular dysplasia: a case report and review of literature.** *Arch Intern Med.* 2004; **164**(10): 1148–53.
[PubMed Abstract](#) | [Publisher Full Text](#)
- AbuRahma AF, Stone PA, Bates MC, *et al.*: **Angioplasty/stenting of the superior mesenteric artery and celiac trunk: early and late outcomes.** *J Endovasc Ther.* 2003; **10**(6): 1046–53.
[PubMed Abstract](#) | [Publisher Full Text](#)
- Kasirajan K, O'Hara PJ, Gray BH, *et al.*: **Chronic mesenteric ischemia: open surgery versus percutaneous angioplasty and stenting.** *J Vasc Surg.* 2001; **33**(1): 63–71.
[PubMed Abstract](#) | [Publisher Full Text](#)
- Rose SC, Quigley TM, Raker EJ: **Revascularisation for chronic mesenteric ischemia: comparison of operative arterial bypass grafting and percutaneous transluminal angioplasty.** *J Vasc Interv Radiol.* 1995; **6**(3): 339–49.
[PubMed Abstract](#) | [Publisher Full Text](#)
- Cunningham CG, Reilly LM, Rapp JH, *et al.*: **Chronic visceral ischemia: Three decades of progress.** *Ann Surg.* 1991; **214**(3): 276–88.
[PubMed Abstract](#) | [Free Full Text](#)
- Mateo RB, O'Hara PJ, Hertzner NR, *et al.*: **Elective surgical treatment of symptomatic chronic mesenteric occlusive disease: early results and late outcomes.** *J Vasc Surg.* 1999; **29**(5): 821–31.
[PubMed Abstract](#) | [Publisher Full Text](#)
- Furrer J, Grüntzig A, Kugelmeier J, *et al.*: **Treatment of abdominal angina with percutaneous dilatation of an arteria mesenterica superior stenosis. Preliminary communication.** *Cardiovasc Intervent Radiol.* 1980; **3**(1): 43–4.
[PubMed Abstract](#) | [Publisher Full Text](#)
- Matsumoto AH, Tegtmeier CJ, Fitzcharles EK, *et al.*: **Percutaneous transluminal angioplasty of visceral arterial stenoses: results and long-term clinical follow-up.** *J Vasc Interv Radiol.* 1995; **6**(2): 165–74.
[PubMed Abstract](#) | [Publisher Full Text](#)
- Allen RC, Martin GH, Rees CR, *et al.*: **Mesenteric angioplasty in the treatment of chronic intestinal ischemia.** *J Vasc Surg.* 1996; **24**(3): 415–21.
[PubMed Abstract](#) | [Publisher Full Text](#)
- Barone JE, Madlinger RV: **Should an Allen test be performed before radial artery cannulation?** *J Trauma.* 2006; **61**(2): 468–70.
[PubMed Abstract](#) | [Publisher Full Text](#)
- Kougias P, El Sayed HF, Zhou W, *et al.*: **Management of chronic mesenteric ischemia: The role of endovascular therapy.** *J Endovasc Ther.* 2007; **14**(3): 395–405.
[PubMed Abstract](#) | [Publisher Full Text](#)

Current Referee Status:

Referee Responses for Version 1



Lefeng Qu

Department of Vascular Surgery, Shanghai Hospital, Second Military Medical University, Shanghai, China

Approved: 13 May 2014

Referee Report: 13 May 2014

doi: [10.5256/f1000research.3190.r4650](https://doi.org/10.5256/f1000research.3190.r4650)

This article reported a case of a 14-year old male, diagnosed with CMI who underwent PTA followed by stent placement with immediate positive results.

The history was reported clearly, and the procedure was described in detail.

The authors also pointed out their experiences concerning the tips of the procedure, such as choosing the right radial artery as the approach to overcome the acute angle of the celiac artery, and the use of nitroglycerine to prevent radial artery vasospasm.

Generally, this is an interesting article, and has certain merits for indexing.

I have read this submission. I believe that I have an appropriate level of expertise to confirm that it is of an acceptable scientific standard.

Competing Interests: No competing interests were disclosed.



Madathipat Unnikrishnan

Department of Cardiovascular and Thoracic Surgery, Sree Chitra Thirunal Institute of Medical Sciences and Technology, Trivandrum, India

Approved: 25 April 2014

Referee Report: 25 April 2014

doi: [10.5256/f1000research.3190.r4553](https://doi.org/10.5256/f1000research.3190.r4553)

The authors present an excellent and well-written case of a 14 year old boy who reported with features of mesenteric angina due to ostioproximal stenosis of the coeliac trunk managed by percutaneous angioplasty combined with stenting. Technical success was followed by clinical relief of symptoms along with considerable weight gain for the boy as expected.

However, I wish to place a few of my thoughts and suggestions regarding this case scenario:

- The last line of the introduction (just prior to Case report) is redundant.
- Isolated coeliac artery stenosis is rarely the cause for mesenteric angina in the presence of a full calibre superior mesenteric artery. Also ostioproximal lesion is not typical of FMD which usually

involves the body of an artery (Renal /internal carotid).

- In this 14 year old boy, having had congenital cardiac (VSD and PDA) lesions, rarely found coeliac artery syndrome might have been the cause that had given rise to the symptoms described.

I congratulate the authors and suggest they also discuss the possibility or otherwise of coeliac artery syndrome in discussion which would make this a tidy and valuable contribution.

I have read this submission. I believe that I have an appropriate level of expertise to confirm that it is of an acceptable scientific standard.

Competing Interests: No competing interests were disclosed.

1 Comment

Referee Response

Madathipat Unnikrishnan, Sree Chitra Thirunal Institute of Medical Sciences and Technology,
India

Posted: 28 Apr 2014

In continuation to my referee report, in the Conclusion the authors should change 'CIM' to 'CMI'

Competing Interests: No competing interests were disclosed.