

Case Report


Dural metastasis from prostate carcinoma mimicking tuberculum sellae meningioma: A case report

Masaaki Kobayashi¹, Yasuo Sasagawa¹, Satoko Nakada², Yukihiro Kohda³, Mitsutoshi Nakada⁴

¹Department of Neurosurgery, Graduate School of Medical Science, Kanazawa University; ²Department of Pathology, Kanazawa University Hospital;

³Department of Neurosurgery, Asanogawa General Hospital, ⁴Department of Neurosurgery, Kanazawa University, Kanazawa, Japan.

E-mail: *Masaaki Kobayashi - m.koba84@med.kanazawa-u.ac.jp; Yasuo Sasagawa - y-sasa@med.kanazawa-u.ac.jp; Satoko Nakada - snakada@staff.kanazawa-u.ac.jp; Yukihiro Kohda - ykohda409@gmail.com; Mitsutoshi Nakada - mnakada@med.kanazawa-u.ac.jp



*Corresponding author:

Masaaki Kobayashi,
Department of Neurosurgery,
Graduate School of Medical
Science, Kanazawa University,
Kanazawa, Japan.

m.koba84@med.kanazawa-u.
ac.jp

Received : 16 March 2022

Accepted : 04 August 2022

Published : 09 September 2022

DOI

10.25259/SNI_257_2022

Quick Response Code:



ABSTRACT

Background: Prostate carcinoma rarely metastasizes to the central nervous system. However, when it does, a dural lesion is a common and possible misdiagnosis of meningioma. Here, we describe a case of a 77-year-old man with dural metastasis from prostate carcinoma of the tuberculum sellae.

Case Description: The patient was diagnosed with prostate carcinoma 7 years previously and was well-controlled by hormone therapy. He was incidentally found to have a suprasellar tumor and underwent endoscopic endonasal transsphenoidal surgery because of rapid tumor growth and worsening visual impairment. Since his serum prostate-specific antigen (PSA) level was within the normal range, malignant meningioma was suspected based on the magnetic resonance imaging (MRI) and the course. However, the pathological findings revealed dural metastasis from prostate carcinoma. He received radiation therapy, and the tumor disappeared on MRI. His visual impairment improved without recurrence. This case report highlights that dural metastasis of the tuberculum sellae arose despite the patient's PSA level being within the normal range, and a single metastasis to the dura was found.

Conclusion: In patients with a history of prostate carcinoma or older men, careful follow-up considering the possibility of metastasis is required when a dural lesion is found.

Keywords: Batson's venous plexus, Dural metastasis, Prostate carcinoma, Surgical resection, Tuberculum sellae meningioma

INTRODUCTION

Prostate carcinoma usually metastasizes to the pelvic lymph nodes and bones and its rarely to the central nervous system (CNS). CNS metastasis from metastatic prostate carcinoma was noted in 131 of 6282 (2.1%) patients with prostate carcinoma.^[8] However, when prostate carcinoma metastasizes to the CNS, it is characterized by a high proportion of dural metastases and is the most common primary tumor of dural metastasis in men.^[3,6] Dural metastasis from prostate carcinoma can look like meningioma on imaging, and there have been several reports of dural metastasis from prostate carcinoma that was difficult to differentiate preoperatively from meningioma.^[1,4] Here, we have reported a case of dural metastasis from prostate carcinoma that mimicked tuberculum sellae meningioma.

This is an open-access article distributed under the terms of the Creative Commons Attribution-Non Commercial-Share Alike 4.0 License, which allows others to remix, transform, and build upon the work non-commercially, as long as the author is credited and the new creations are licensed under the identical terms.

©2022 Published by Scientific Scholar on behalf of Surgical Neurology International

CASE REPORT

A 77-year-old man diagnosed with prostate carcinoma 7 years ago received hormone therapy (gonadotropin-releasing hormone agonist) and was well-controlled. A tumor of the tuberculom sellae was observed on whole-body computed tomography in 2017 [CT; Figure 1a], but it was not recognized. In April 2019, he developed hyperproteinemia and anemia and was diagnosed with plasmacytoma. 18F-fluorodeoxyglucose positron emission tomography showed a suprasellar lesion with low uptake (maximum standardized uptake value, 4.2). Magnetic resonance imaging (MRI) revealed a tumor (25 × 18 × 19 mm) in the tuberculom sellae [Figure 1b]. Ophthalmologic examination revealed that his left eye was affected by fundus hemorrhage caused by hyperviscosity syndrome associated with plasmacytoma. In his right eye, Humphrey perimetry revealed upper temporal quadrantanopsia [Figure 1c], but his visual acuity was intact (20/20). His serum prostate-specific antigen (PSA) was within the normal range at 3.900 ng/mL and his pituitary hormone level was also normal. We diagnosed the tumor as a meningioma in the tuberculom sellae. Treatment for plasmacytoma was prioritized and chemotherapy was initiated. Two months later, he complained of blurred vision and his visual acuity in the right eye had decreased (10/20). Humphrey perimetry revealed progressive visual field disturbance [Figure 2a]. MRI showed tumor growth (27 × 24 × 25 mm) with homogeneous and dural enhancement

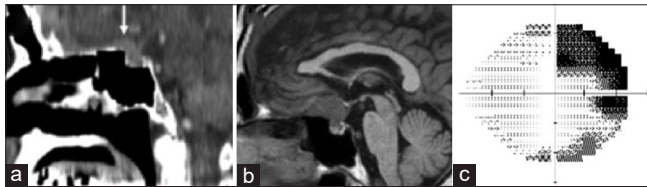


Figure 1: (a) A high-density mass was seen on sagittal computed tomography in 2017 (white arrow). (b) T1-weighted sagittal image with iso-intensity showing the tumor located at the tuberculom sellae. (c) When the suprasellar tumor was initially found, the patient's visual field test on the right eye showed upper temporal quadrantanopsia.

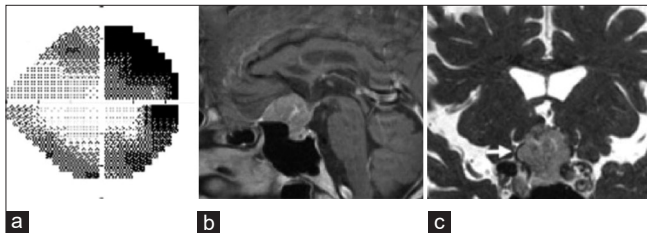


Figure 2: (a) Two months later, his visual acuity and field were aggravated. (b) Gadolinium T1-weighted image showing tumor growth with homogeneous enhancement two months later. Dural enhancement can also be seen. (c) Fast imaging with steady-state acquisition revealed that the right optic nerve (white arrow) was compressed by the tumor.

[Figure 2b]. Fast imaging with steady-state acquisition revealed that the right optic nerve was compressed by the tumor [Figure 2c] and malignant meningioma was suspected. He underwent endoscopic endonasal transsphenoidal surgery. The tumor was strongly attached to the dura. Surgery was completed with partial resection because the tumor adhered to the optic nerve/chiasm and was difficult to detach. The dura and bone defects were reconstructed using an overlay technique to prevent cerebrospinal fluid leakage. Pathological examination revealed atypical epithelioid cells with vacuoles. The gland-like formation was immunopositive for PSA and androgen receptor [Figures 3a-c]. The patient was diagnosed with dural metastasis from prostate carcinoma and received radiation therapy at a dose of 45 Gy (3 Gy × 15). The tumor disappeared on MRI [Figure 4a] and his visual impairment improved [Figure 4b]. Two years after irradiation, the patient did not experience any recurrence.

DISCUSSION

CNS metastasis from prostate carcinoma is rare. However, prostate carcinoma is the most common cause of dural metastases. Laigle-Donadey *et al.* reported in a review of 198 cases of dural metastases in which the major primary tumors were in the prostate (19.5%), breasts (16.5%), and lungs (11%).^[3] In another study conducted on 122 patients with dural metastases, 34%, 17%, and 13% of the patients had breast, prostate, and lung cancer, respectively.^[6] Dural metastasis may arise from direct extension from skull metastasis or by hematogenous spread. Direct extension from skull metastasis is the most common, which explains the high association with prostate and breast cancer, which usually metastasizes to the

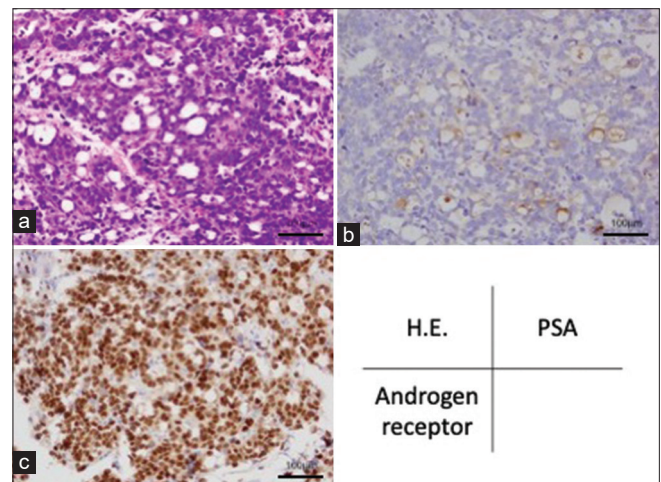


Figure 3: (a) Atypical epithelioid cells with vacuole proliferated in a sheeting pattern and focal gland-like formation can be seen (hematoxylin-eosin stain). (b and c) Immunohistochemically, the gland-like region was positive for prostate-specific antigen, and the nuclei of the tumor cells were diffusely positive for androgen receptor.

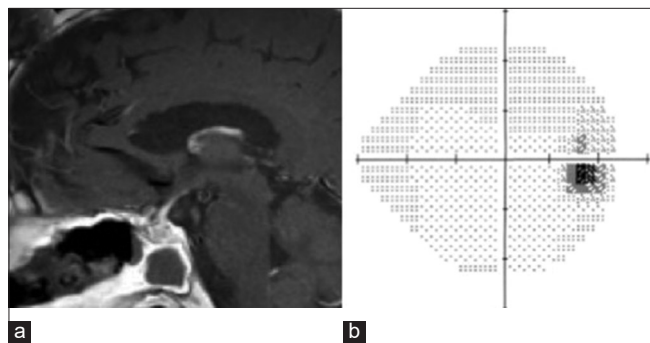


Figure 4: (a) The tumor disappeared after radiation therapy following transsphenoidal surgery. (b) The visual field disorder improved with the disappearance of the tumor.

bone.^[3,6] The tendency of prostate carcinoma to metastasize to the dura has been attributed to venous dissemination through Batson's venous plexus.^[5] Direct hematogenous spread is most likely when only dural metastases are observed. In the previous reports, most patients had high PSA levels and systemic diseases, such as bone or lymph node metastasis when dural metastasis from prostate carcinoma was diagnosed.^[2] In our case, the PSA level was controlled, and there were no metastases other than the dura at the time of diagnosis. We concluded that the dural metastasis had developed through the Batson's venous plexus. We assumed that the PSA level was within the normal range because the metastasis was localized to the dura. Dural metastases can look meningioma-like on imaging; therefore, a pathological diagnosis is important.^[4,7] Dural metastases from prostate carcinoma are rare; however, the possibility of prostate metastases should be considered when a dural tumor is detected, especially in patients with a history of prostate carcinoma or older men.^[4] There is no standard treatment for the management of dural metastasis. However, surgery and radiation therapy are effective in managing dural metastasis.^[2] Surgical resection is the most efficacious, particularly when the lesion is resectable and systemic disease is controlled.^[3,6] Following surgery and radiation therapy, our patient did not experience any recurrence for 2 years.

CONCLUSION

Although rare, dural metastasis should be considered a differential diagnosis in patients with prostate cancer. Careful

follow-up considering the possibility of metastasis is required when a dural lesion is found in patients with a history of prostate carcinoma or older men.

Declaration of patient consent

The authors certify that they have obtained all appropriate patient consent.

Financial support and sponsorship

Nil.

Conflicts of interest

There are no conflicts of interest.

REFERENCES

1. Chen TY, Lee HJ, Wu TC, Tsui YK, Wu TC. Intracranial dural metastatic prostate cancer can mimic meningioma: A report of two cases. *Clin Imaging* 2011;35:391-4.
2. Ganau M, Gallinaro P, Cebula H, Scibilia A, Todeschi J, Gubian A, *et al.* Intracranial metastases from prostate carcinoma: Classification, management, and prognostication. *World Neurosurg* 2020;134:e559-65.
3. Laigle-Donadey F, Taillibert S, Mokhtari K, Hildebrand J, Delattre JY. Dural metastases. *J Neurooncol* 2005;75:57-61.
4. Lath CO, Khanna PC, Gadewar S, Patkar DP. Intracranial metastasis from prostatic adenocarcinoma simulating a meningioma. *Australas Radiol* 2005;49:497-500.
5. Mitchell RA, Dimou J, Tsui A, Kavar B. Metastatic prostate adenocarcinoma invading an atypical meningioma. *J Clin Neurosci* 2011;18:1723-5.
6. Nayak L, Abrey LE, Iwamoto FM. Intracranial dural metastases. *Cancer* 2009;115:1947-53.
7. Tagle P, Villanueva P, Torrealba G, Huete I. Intracranial metastasis or meningioma? An uncommon clinical diagnostic dilemma. *Surg Neurol* 2002;58:241-5.
8. Tremont-Lukats IW, Bobustuc G, Lagos GK, Lolas K, Kyritsis AP, Puduvalli VK. Brain metastasis from prostate carcinoma: The M. D. Anderson cancer center experience. *Cancer* 2003;98:363-8.

How to cite this article: Kobayashi M, Sasagawa Y, Nakada S, Kohda Y, Nakada M. Dural metastasis from prostate carcinoma mimicking tuberculum sellae meningioma: A case report. *Surg Neurol Int* 2022;13:407.