



Endoscopic Orientation of Juxta-pituitary Carotid in Transsphenoidal Approaches: Critical Considerations for Clinical Applications

Mostafa Ismail¹  Mohab Darwish² Abd El Rahman El Tahan³ Islam R. Herzallah⁴

¹ Department of Otorhinolaryngology, Minia University Hospital, Minia University, Minia, Egypt

² Department of Neurosurgery, Minia University Hospital, Minia University, Minia, Egypt

³ Department of Otorhinolaryngology, Aswan University Hospital, Aswan University, Aswan, Egypt

⁴ Department of Otorhinolaryngology–Head & Neck Surgery, Faculty of Medicine, Zagazig University, Zagazig, Egypt

Address for correspondence Mostafa Ismail, MD, Department of Otorhinolaryngology, Minia University Hospital, Kornish El Nile St., El Minia – Minya, Egypt (e-mail: mostafaismail3730@yahoo.com).

Int Arch Otorhinolaryngol 2023;27(3):e455–e460.

Abstract

Introduction In sphenoid sinuses with ill-defined carotid bony landmarks, accidental injury of the internal carotid artery (ICA) remains one of the most challenging complications, which is particularly reported in the endoscopic endonasal transsphenoidal approaches (EETAs).

Objectives To describe an anatomical model for the endoscopic orientation of the juxta-pituitary segment of the ICA in relation to the lateral opticocarotid recess (OCR) as a nearby bony landmark.

Methods Dissection was performed progressively, simulating the EETA, in twenty fresh adult cadavers. After reducing the posterior and lateral walls of the sphenoid sinuses, various measurements were taken from both lateral OCRs to “contact points” on the juxta-pituitary segment of the ICA and lateral margins of the pituitary gland.

Results The current results have enabled us to divide the region between the lateral OCRs into 3 compartments: 2 lateral parasellar compartments contain juxta-pituitary segments of the ICA with a mean width of 8 mm and a narrow range from 7 mm to 10 mm; and a central intercarotid sellar compartment represents the safe region for bone drilling, showing widely variable widths ranging from 9 mm to 20 mm. In all specimens, the variation in the width of the intercarotid compartment correlated with the distance between both lateral OCRs.

Conclusion The present study improves surgeon awareness of the variations in the course of the ICA through the EETA along sphenoid sinuses with ill-defined bony landmarks. An appreciation of the measurements taken in the present study can help in operative training, and can also provide a base for future studies to confirm ICA courses associated with a higher risk of injury.

Keywords

- ▶ cadaveric study
- ▶ internal carotid artery
- ▶ lateral opticocarotid recess
- ▶ pituitary gland
- ▶ transsphenoidal approach

received

April 15, 2020

accepted after revision

April 17, 2022

DOI <https://doi.org/>

10.1055/s-0042-1749391.

ISSN 1809-9777.

© 2023. Fundação Otorrinolaringologia. All rights reserved.

This is an open access article published by Thieme under the terms of the Creative Commons Attribution-NonDerivative-NonCommercial-License, permitting copying and reproduction so long as the original work is given appropriate credit. Contents may not be used for commercial purposes, or adapted, remixed, transformed or built upon. (<https://creativecommons.org/licenses/by-nc-nd/4.0/>)

Thieme Revinter Publicações Ltda., Rua do Matoso 170, Rio de Janeiro, RJ, CEP 20270-135, Brazil

Introduction

For more than three decades, the transsphenoidal midline route has been the standard approach for the excision of most intrasellar tumors.¹⁻⁴ The complex anatomy of the sphenoid sinus and its critical neurovascular relationships have always rendered the endoscopic transsphenoidal surgery a relative surgical challenge, particularly in sphenoid sinuses with ill-defined bony landmarks and narrow inter-carotid distances.

Vascular complications represent a serious challenge in the performance of endoscopic transsphenoidal approaches, and they still occur despite the continuous evolution in intraoperative image guidance.⁵ The risk of vascular complications has been associated, in most cases, with the surgeon's experience, intraoperative visualization, history of previous surgery, and presence of anatomical variations.⁶ These complications can be avoided, but it is of great importance to anticipate such problems and to make every effort to prevent them.

In transsphenoidal approaches, understanding the course of the internal carotid artery (ICA) in the sellar and parasellar regions is crucial to guarantee efficiency and safety, so that bone drilling is safe and avoids vascular injury. From a transnasal endoscopic perspective, the cavernous and paraclinoid segments of the ICA consistently form two bends which may bring the artery in contact with the pituitary gland. This often represents the key region for most endoscopic exposures.⁷ The lateral opticocarotid recess (OCR) is a constant and easily predictable anatomical landmark even in the presellar pneumatized sphenoid sinuses; thus, it can be helpful to efficiently guide the surgeon to the parasellar ICA and medial margin of the cavernous sinus.⁸

We present the results of a cadaveric study to describe an anatomical model for the endoscopic orientation of the juxta-pituitary segment of the ICA using the lateral OCR as a reliable landmark to predict the critical points of carotid contact with the lateral margins of the pituitary gland regardless of the degree of pneumatization of the sphenoid sinus.

Materials and Methods

The endoscopic anatomy of the sphenoid sinus and central skull base was studied in the Morgue Specialization Department. For more realistic measurements, twenty fresh adult cadavers with no former preservation or vascular injections were dissected using a stepwise endoscopic endonasal transsphenoidal approach (EETA). Consent for postmortem dissection was provided by the donors and the Medical Council.

Dissections were performed with regular instruments for sinus and skull base surgery under visualization with an 18-cm long, 4-mm in diameter, 0° rigid endoscope used for standard endoscopic sinus surgery. The images were displayed on a flat screen by connecting a video camera to the endoscope in all dissections. All measurements were taken on a millimetric scale.

Total sphenoidotomy was performed after endonasal identification of the natural ostium of the sphenoid sinus. Once inside the sphenoid sinus, the important bony landmarks were identified. The sellar floor was identified in the midline with the tuberculum sellae and sphenoidal planum above, and the sphenoid rostrum and clival recess below. Laterally, the lower (paraclival) and upper (paraclinoid) carotid prominences, as well as the optic prominences, were identified with the lateral OCR in between. The type of sphenoid sinus pneumatization was determined by considering all previous landmarks together.

The bony walls of sphenoid sinuses were reduced starting with the sellar floor, which was entered using a sharp dissector, and widened with a 2-mm angled Kerrison rongeur to expose the sellar dura covering the pituitary gland. Bone removal was extended laterally, on both sides, to expose the cavernous and paraclinoid segments of the ICA, which delineate the medial parasellar region. Both lateral OCRs were left intact during dissection to be used as landmarks for our measurements, but not the medial OCRs, which were only pneumatized in 50% of cases. The variation in distance between both lateral OCRs was recorded.

In the current study, we followed a slightly-modified seven-segment classification system of the ICA by DePowell et al.⁷ was followed. To describe the part of the ICA that may be in contact with the pituitary gland, we chose the term *juxta-pituitary* carotid. This segment comprises the intracavernous part of the paraclival segment, the parasellar segment, and the paraclinoid segment of the ICA. The term *juxta-pituitary carotid* helps avoid the ongoing discussion on whether the paraclinoid segment of the ICA is located intra- or extracavernously.

In all specimens, we relied on the lateral OCRs to define two reference points on each side; the upper one was located at the center of the lateral OCR, and the lower one was located at the same vertical plane, but below the upper point, at the level of the lower border of the pituitary gland. From the previously-recorded reference points, the distance between the upper reference point and the most medial margin of the paraclinoid segment of ICA was recorded first on both sides. Subsequently, the distance between the lower reference point and the most convex margin of the posterior bend of the ICA was recorded on both sides (→ Fig. 1A,B).

All measurements were taken on a millimetric scale using a malleable surgical ruler, before peeling the dura of the sellar and parasellar regions, to maintain as much as possible the measurements on living conditions, since removal of the dura covering the pituitary gland and cavernous carotids may disturb the original anatomical position of these structures.

Results

Endoscopic dissection was performed to gain direct access to the sphenoid sinus. During endoscopic dissection, a wider surgical access to the central skull base had to be created for exposure and manipulation of different structures in this region.

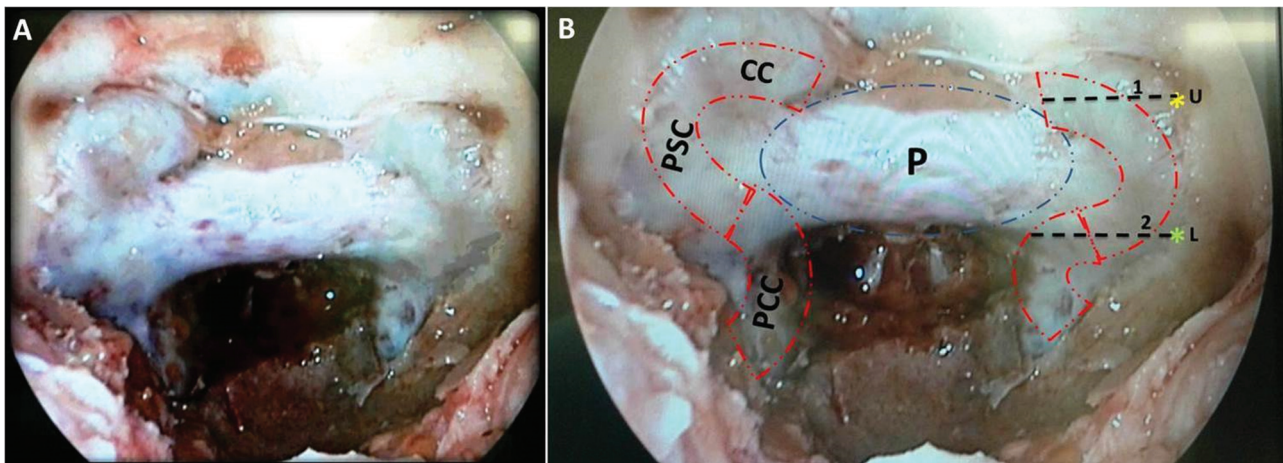


Fig. 1 (A,B) Skeletonized sphenoid sinus showing the relationship of the juxta-pituitary ICA with the lateral OCR and pituitary gland; line 1: distance between the upper reference point and the most medial margin of the paraclinoid segment; line 2: distance between the lower reference point and the most convex margin of the posterior bend of the ICA. Abbreviations: CC, paracaloid carotid; L, lower reference point; P, pituitary gland; PCC, paraclival carotid; PSC, parasellar carotid; U, upper reference point.

The types of sphenoid sinus pneumatization were grouped according to their characteristics into sellar, presellar, and conchal, according to the classification by Hamberger et al.⁹ In the present series, sellar pneumatization was the most common type (13 specimens; 65%). The presellar type was found in 6 specimens (30%), and the conchal type was only found in 1 (5%) specimen.

Sellar bulge and clival indentation in the midline, as well as carotid and optic prominences with both lateral OCRs in the lateral wall, were found to be well defined in the cases of sellar pneumatization. Regarding presellar pneumatization, all the intrasphenoidal bony landmarks were ill defined; the carotid and optic prominences were inappreciable, while the lateral OCRs were distinguishable. This means that the lateral OCRs were present and pneumatized in all specimens; however, they were well defined in 13 specimens and ill-defined in 6; the sellar and presellar sphenoid sinuses

respectively. Most intersphenoid septations (14 specimens; 67%) had paramedian orientation (right: 4 specimens; left: 10 specimens), while the other 6 specimens (33%) had midline orientation. Identification of the lateral OCRs was not affected by the configuration of the intersphenoid septations, as the posterior end of all paramedian septations was attached to the optic prominence, and the lateral OCRs were oriented laterally to the septation. These findings endorsed our choice to rely on the lateral OCRs as a landmark to take vascular measurements.

A wide variation in the distance between both lateral OCRs was found among the specimens, ranging between 23 mm to 34 mm, and with a mean distance of 26.5 mm. This was correlated with the variation in the intercarotid distance at the level of the paraclinoid segments (–Fig. 2A,B). The mean vertical distance between the upper and lower reference points was of 8 mm (range: 6–10 mm); this was comparable

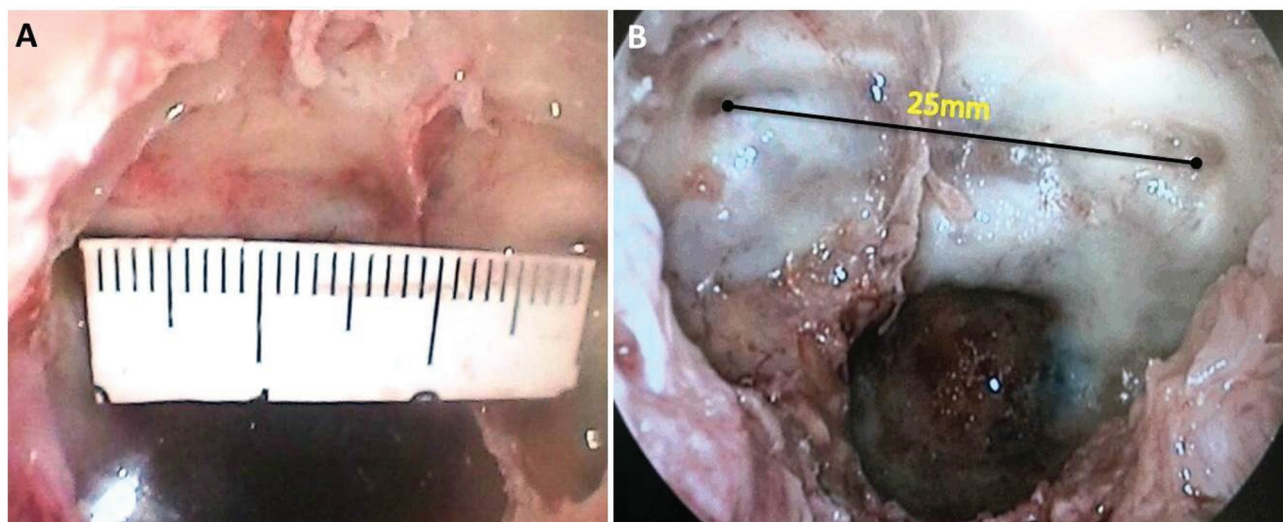


Fig. 2 Endoscopic view of sphenoid sinuses showing the recorded variation in the distance between both lateral OCRs; (A) 30 mm; (B) 25 mm.

with the variation in the height of the pituitary gland. The commonest anatomical variations identified regarding the juxta-pituitary ICA were those in the angle between the paraclival and parasellar segments. The angle was acute in 37% of the specimens in which the artery always in contact with the pituitary gland, while it was obtuse in 63% of the specimens in which the artery was 1 mm to 3 mm away from the pituitary gland.

From the upper reference point, the mean distance to the most medial margin of the paraclinoid segment was of 8 mm, ranging from 7 mm to 10 mm on both sides. Likewise, the mean distance from the most convex margin of the posterior bend to the lower reference point was of 8 mm, ranging from 7 mm to 9 mm on both sides (►Table 1). The carotid contact points herein presented were used to divide the region between both lateral OCRs into three compartments: two lateral (parasellar) and one central (sellar) (►Fig. 3A,B). Both lateral parasellar compartments had a mean width of 8 mm, with a narrow range from 7 mm to 10 mm, while the central intercarotid sellar compartment showed widely variable widths ranging from 9 mm to 20 mm, with a mean distance of 11.3 ± 2.9 mm.

Discussion

Despite the progress in EETA training and the widespread availability of teaching courses, neurovascular complications

continue to occur.^{10,11} In 2016, a systematic review¹² showed that the most commonly injured ICA segment was the cavernous, followed by the ophthalmic. The sphenoid sinus is extremely variable in size and degree of pneumatization, so the intrasphenoidal bony landmarks may be prominent, inappreciable, or absent.¹ These variations may negatively influence the accuracy of bone removal and, accordingly, the safety of surgery, even when using surgical navigation. Consequently, the aim of the present anatomical study was not to suggest a new description of the endoscopic anatomy of the ICA, which has already been well described; rather, we attempted to establish an anatomical model for the endoscopic orientation of the juxta-pituitary segment of the ICA in sphenoid sinuses with inappreciable bony landmarks and short intercarotid distances.

Most of previous cadaveric studies¹³⁻¹⁸ discussed the relationship between both ICAs with each other and with the pituitary gland rather than doing that in relation to a bony landmark. Based on the findings herein presented, the lateral OCR appears to be the ideal bony landmark, in the lateral wall of the sphenoid sinus, to take vascular measurements. Three reasons reinforced this conclusion: 1) the lateral OCR is the sole constant and distinguishable intrasphenoidal bony landmark,⁸ even in presellar pneumatized sphenoid sinuses; 2) carotid protuberances are variable and sometimes devoid of a bony layer,¹⁶ which renders them unreliable during bone removal; 3) according to our results, the variation in the

Table 1 Measurements taken after skeletonization of the bony walls of the sphenoid sinuses

Cadaver No.	A (26.57 ± 3.3 mm)	B (8.26 ± 1.1 mm)	C (8 ± 0.82 mm)	D (8.05 ± 0.98 mm)	E (7.78 ± 0.85 mm)	F (7.89 ± 0.79 mm)
1	26 mm	8 mm	8 mm	10 mm	7 mm	7 mm
2	23 mm	9 mm	7 mm	7 mm	8 mm	9 mm
3	25 mm	9 mm	7 mm	8 mm	9 mm	7 mm
4	30 mm	9 mm	10 mm	7 mm	9 mm	8 mm
5	23 mm	8 mm	8 mm	8 mm	8 mm	9 mm
6	24 mm	8 mm	7 mm	7 mm	7 mm	8 mm
7	28 mm	10 mm	7 mm	7 mm	7 mm	7 mm
8	28 mm	8 mm	8 mm	8 mm	9 mm	7 mm
9	25 mm	8 mm	8 mm	10 mm	7 mm	7 mm
10	30 mm	8 mm	8 mm	7 mm	9 mm	8 mm
11	32 mm	9 mm	8 mm	9 mm	7 mm	8 mm
12	23 mm	6 mm	9 mm	9 mm	7 mm	9 mm
13	25 mm	8 mm	8 mm	8 mm	8 mm	7 mm
14	23 mm	10 mm	8 mm	8.5 mm	9 mm	8 mm
15	26 mm	8 mm	8 mm	8 mm	8 mm	9 mm
16	25 mm	6 mm	9 mm	9 mm	8 mm	7 mm
17	25 mm	7 mm	7 mm	7 mm	7 mm	8 mm
18	34 mm	9 mm	9 mm	8 mm	7 mm	7 mm
19	30 mm	8 mm	8.5 mm	7.5 mm	7 mm	9 mm

Notes: A, distance between both lateral opticocarotid recesses; B, distance between the upper and lower reference points; C, distance between the upper reference point and the medial margin of the paraclinoid segment (right); D, distance between the upper reference point and the medial margin of the paraclinoid segment (left); E, distance between the lower reference point and the most convex margin of the posterior bend (right); F, distance between the lower reference point and the most convex margin of posterior bend (left).

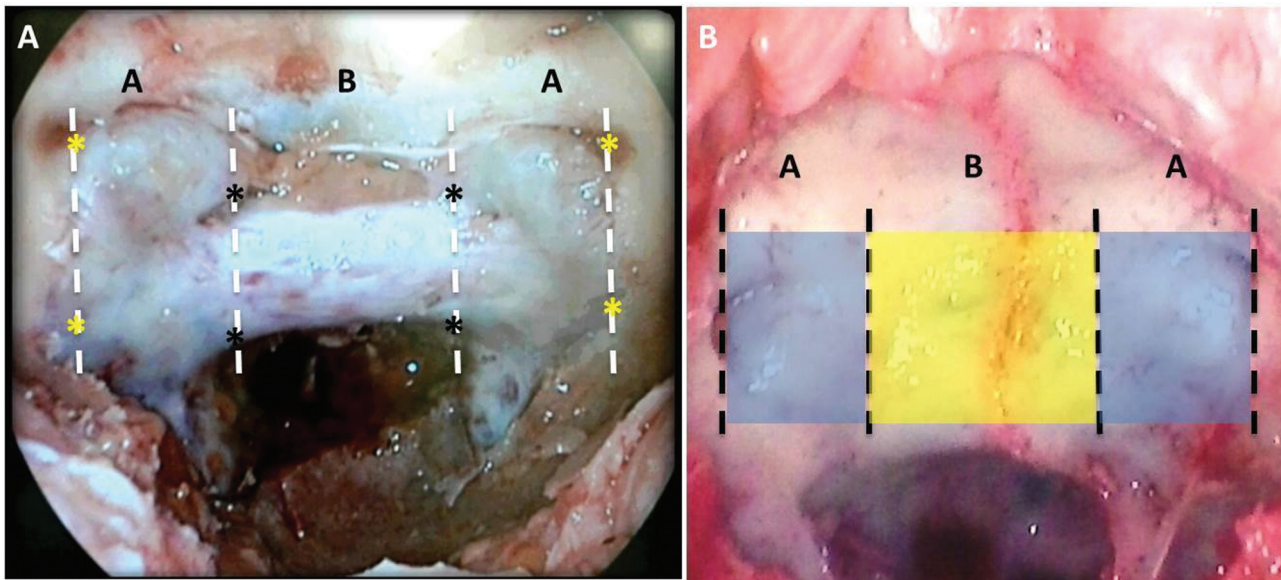


Fig. 3 Endoscopic view of the sphenoid sinus before and after skeletonization, showing the four defined contact points (black*) of both juxta-pituitary carotids with the lateral margins of the pituitary gland, and the upper and lower reference points (yellow*) on both sides. The area between both lateral OCRs is divided into 3 compartments, 2 lateral parasellar (A), with a mean width of 8 mm, and 1 central sellar (B), with a width ranging 9 mm to 20 mm.

distance between both lateral OCRs correlates with the variation in the intercarotid distance, particularly at the level of the paraclinoid segment of the ICA.

Based on the measurements performed in the current study, the region between the lateral OCRs can be divided into three compartments. The lateral parasellar compartment, on each side, contains the juxta-pituitary segment of the ICA, which comprises the intracavernous part of the paraclival segment, the parasellar segment, and the paraclinoid segment. This compartment is bound by two vertical lines: one transects the center of the lateral OCR that delineates the lateral limit of the juxta-pituitary segment of ICA, not the lateral margin of

the parasellar compartment, and the other is located at a mean distance of 8 mm (up to 10 mm) medial to the first line and delineates the carotid contact with the pituitary gland. The central intercarotid sellar compartment, which represents the safe area between both juxta-pituitary carotids, showed variable widths ranging between 9 mm to 20 mm. Thus, the variable distance between both lateral OCRs can be efficiently used to determine the width of the intercarotid area. On the other hand, the distance between the lateral OCR and the contact point of the juxta-pituitary carotid maintained a narrow range regardless of the variations in intercarotid distance (► Fig. 4A,B).

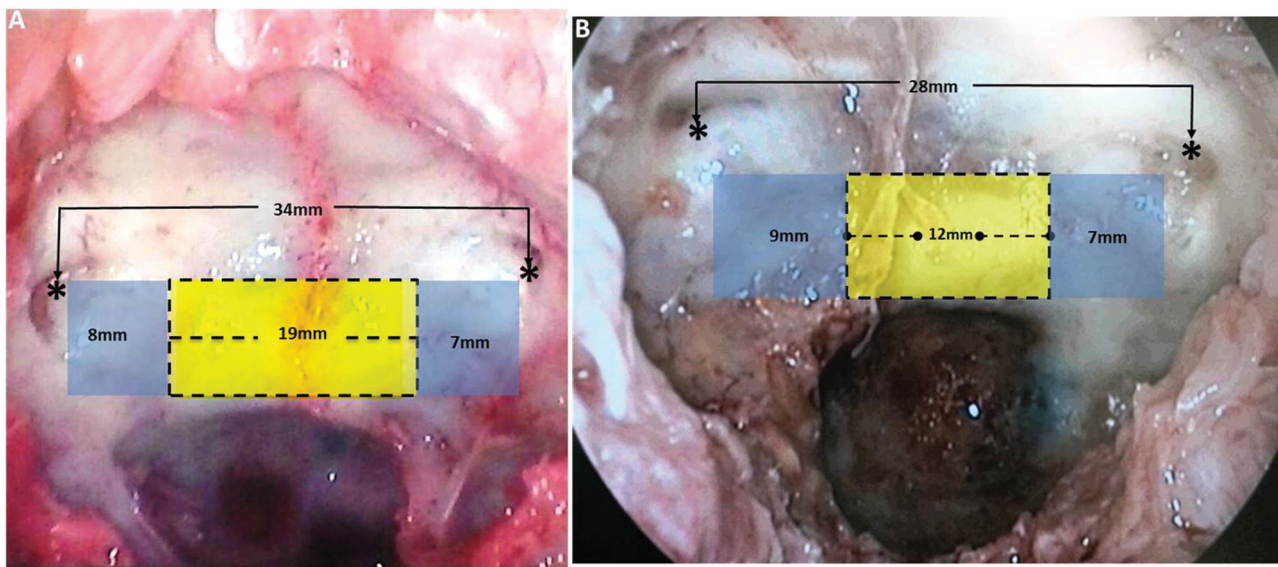


Fig. 4 (A,B) Endoscopic view of sphenoid sinuses, in two different specimens, showing the width variation of the central intercarotid sellar compartment in relation to the distance variation between both lateral OCRs as well as a maintained narrow range of widths for the lateral parasellar compartments.*

One of the most challenging steps in all transsellar approaches is the accurate determination of the intercarotid area that is deemed safe to work if a short intercarotid distance has been proved preoperatively through magnetic resonance imaging (MRI). Most surgeons expose the sella and then look for the medial margin of the cavernous sinus through the intraoperative use of the navigation system and/or intranasal Doppler. The introduction of computer-assisted surgery has definitely helped address the expected location and course of the ICA during EETA;⁵ this should not, however, impede our anatomical knowledge and deviate our attention to different variations, particularly since the navigation systems are not universally available and, in many centers, are not currently part of the set up for routine pituitary cases; moreover, it has reported variable registration errors.¹⁹ The anatomical model described in the present study is not meant to make the surgeon take measurements intraoperatively, but instead to provide an estimate of where to expect the pituitary-carotid contact points in the surgical field and how much they varies. In other words, this anatomical model roughly tells the surgeon where to begin and to end bone removal during EETA; the surgeon must start at the sellar midline and finish at the pituitary-carotid contact points established intraoperatively in relation to the lateral OCR as a bony landmark. This has been clearly shown in two examples in the present study (►Fig. 4A,B), as the width of the central safe area for bone removal was always determined by recording the distance between both lateral OCRs, which was also used to delineate the pituitary-carotid contact points on both sides, aiming at performing endoscopic endonasal skull base surgery more safely and effectively.

Conclusion

The EETA enables an expanded access to all regions of the central skull base. Great reason and care must be applied when operating in this particular region due to the possible variations in the intrasphenoidal bony landmarks. Since the key for safe surgery in this area is related to adequate manipulation of the ICA, the current work updates our knowledge about the location of the juxta-pituitary carotid from an endoscopic perspective. The variations herein described aim at improving surgeon awareness of carotid location in the EETA. This information can help surgeons in training and can also provide a base for future studies to confirm ICA courses associated with higher risk of injury.

Funding

The authors declare that they have no funding resources regarding the performance of the present study.

Conflict of Interests

The authors have no conflict of interests to declare.

References

- 1 Cavallo LM, Messina A, Cappabianca P, et al. Endoscopic endonasal surgery of the midline skull base: anatomical study and clinical considerations. *Neurosurg Focus* 2005;19(01):E2
- 2 Cappabianca P, de Divitiis E. Endoscopic endonasal transsphenoidal surgery Management of Pituitary Tumors. Springer; 2003: 161–171
- 3 Liu JK, Das K, Weiss MH, Laws ER Jr, Couldwell WT. The history and evolution of transsphenoidal surgery. *J Neurosurg* 2001;95(06): 1083–1096
- 4 McDonald T, Laws E Jr. Historical aspects of the management of pituitary disorders with emphasis on transsphenoidal surgery. *The Management of Pituitary Adenomas and Related Lesions with Emphasis on Transsphenoidal Microsurgery*. New York: Appleton-Century-Crofts; 1982:1–13
- 5 Gardner PA, Tormenti MJ, Pant H, Fernandez-Miranda JC, Snyderman CH, Horowitz MB. Carotid artery injury during endoscopic endonasal skull base surgery: incidence and outcomes. *Neurosurgery* 2013;73(02, Suppl Operative) ons261–ons269, discussion ons269–ons270
- 6 Laws ER Jr. Vascular complications of transsphenoidal surgery. *Pituitary* 1999;2(02):163–170
- 7 DePowell JJ, Froelich SC, Zimmer LA, et al. Segments of the internal carotid artery during endoscopic transnasal and open cranial approaches: can a uniform nomenclature apply to both? *World Neurosurg* 2014;82(06, Suppl)S66–S71
- 8 Labib MA, Prevedello DM, Carrau R, et al. A road map to the internal carotid artery in expanded endoscopic endonasal approaches to the ventral cranial base. *Neurosurgery* 2014;10 (Suppl 3):448–471, discussion 471
- 9 Hamberger CA, Hammer G, Marcusson G. Experiences in trans-antrosphenoidal hypophysectomy. *Trans Pac Coast Otoophthalmol Soc Annu Meet* 1961;42:273–286
- 10 Kassam AB, Prevedello DM, Carrau RL, et al. Endoscopic endonasal skull base surgery: analysis of complications in the authors' initial 800 patients. *J Neurosurg* 2011;114(06):1544–1568
- 11 Solares CA, Ong YK, Carrau RL, et al. Prevention and management of vascular injuries in endoscopic surgery of the sinonasal tract and skull base. *Otolaryngol Clin North Am* 2010;43(04):817–825
- 12 Chin OY, Ghosh R, Fang CH, Baredes S, Liu JK, Eloy JA. Internal carotid artery injury in endoscopic endonasal surgery: A systematic review. *Laryngoscope* 2016;126(03):582–590
- 13 Unlu A, Meco C, Ugur HC, Comert A, Ozdemir M, Elhan A. Endoscopic anatomy of sphenoid sinus for pituitary surgery. *Clin Anat* 2008;21(07):627–632
- 14 Renn WH, Rhoton AL Jr. Microsurgical anatomy of the sellar region. *J Neurosurg* 1975;43(03):288–298
- 15 Abuzayed B, Tanriöver N, Ozlen F, et al. Endoscopic endonasal transsphenoidal approach to the sellar region: results of endoscopic dissection on 30 cadavers. *Turk Neurosurg* 2009;19(03):237–244
- 16 Isolan GR, de Aguiar PHP, Laws ER, Strapasson ACP, Piltcher O. The implications of microsurgical anatomy for surgical approaches to the sellar region. *Pituitary* 2009;12(04):360–367
- 17 Cebula H, Kurbanov A, Zimmer LA, et al. Endoscopic, endonasal variability in the anatomy of the internal carotid artery. *World Neurosurg* 2014;82(06):e759–e764
- 18 Yilmazlar S, Kocaeli H, Eyigor O, Hakyemez B, Korfali E. Clinical importance of the basal cavernous sinuses and cavernous carotid arteries relative to the pituitary gland and macroadenomas: quantitative analysis of the complete anatomy. *Surg Neurol* 2008;70(02):165–174, discussion 174–175
- 19 Citardi MJ, Batra PS. Intraoperative surgical navigation for endoscopic sinus surgery: rationale and indications. *Curr Opin Otolaryngol Head Neck Surg* 2007;15(01):23–27